Mimics of HPV-independent vulvar intraepithelial neoplasia in vulvar biopsies

Stephanie L. Skala, MD

Assistant Professor of Pathology, University of Michigan

USCAP
UNITED STATES AND CANADIAN ACADEMY OF PATHOLOGY
Creating a Better Pathologist

Important Information Regarding CME

The **CME/evaluation** process will only be available on the USCAP website until **September 30, 2023**.

No claims can be processed after that date!

After **September 30, 2023** you will NOT be able to obtain any CME credits for attending this meeting.

Disclosure of Relevant Financial Relationships

No relevant financial relationships

Objectives

- List the common histologic features of differentiated vulvar intraepithelial neoplasia (dVIN) / HPV-independent (HPVi) VIN with p53 abnormality.
- Describe the features of HPVi VIN lacking abnormal p53 staining.
- Explain the rationale for universal ordering of p16 and p53 immunostains on suspected VIN specimens.
- Identify key entities in the differential diagnosis of HPVi VIN.

WHO (5th ed): Vulvar intraepithelial neoplasia, HPV-independent

- "Non-invasive precursor of HPVi squamous cell carcinoma, characterized by atypia of the basal and parabasal keratinocytes in an otherwise well-differentiated epithelium"
  - Acceptable terminology: differentiated VIN
  - Subtypes: differentiated exophytic vulvar intraepithelial lesion (DEVIL), vulvar acanthosis with altered differentiation (VAAD)
  - Frequent abnormal p53 staining, but *TP53*wt HPVi intraepithelial lesions may harbor somatic mutations in *PIK3CA*, *NOTCH1*, or *HRAS*
  - Essential: atypia of the basal layer
- Thick keratinized plaques or erosive erythematous macules or plaques

HPV-independent (HPVi) vulvar intraepithelial neoplasia (VIN)

- Many pathologists advocate for distinguishing between *TP53* mutant (differentiated vulvar intraepithelial neoplasia [dVIN]) and *TP53* wild-type lesions
- *TP53* wild-type acanthotic vulvar lesions
  - Vulvar aberrant maturation (VAM)*
  - HPVi, p53-wild-type verruciform acanthotic VIN (HPVi(p53wt) vaVIN)*
    - Includes lesions previously classified as:
      - Differentiated exophytic vulvar intraepithelial lesion (DEVIL)
      - Vulvar acanthosis with altered differentiation (VAAD)
      - Verruciform lichen simplex chronicus (vLSC)
      - Vulvar aberrant maturation (VAM)

Gray Area: HPVi(p53wt) Acanthosis

- Disclaimer: Nomenclature and classification of acanthotic lesions with features more concerning than LS but lacking the atypia of dVIN is controversial

- Where do we draw the line between reactive/inflammatory and neoplastic?

- ISSVD DPDC argues that these are *lesions* rather than *neoplasia* and may represent response to inflammation or neoplastic transition
  - “VAM” allows flexibility for individualized management based on assessment of neoplastic vs surgical risks
  - Since some regress, excision or intensified medical management may be reasonable
  - Close follow-up
- ISSVD DPDC advocates for removing VAAD and DEVIL and separating these from dVIN, but suggests delaying changes to terminology until these lesions are better understood

Differentiated Vulvar Intraepithelial Neoplasia

- Arises in a background of lichen sclerosus or lichen simplex chronicus
- Diagnosis can be challenging; criteria are somewhat subjective
  - Abnormal maturation/keratinization
  - Acanthosis
  - Elongated and/or anastomosing rete ridges
  - Prominent intercellular bridges
  - Parakeratosis
  - Subtle atypia in basal layer
- Aberrant staining for p53*
  - (1) Basal overexpression
  - (2) Parabasal/diffuse overexpression
  - (3) Absent/null expression
  - (4) Cytoplasmic expression
- HPV ISH negative; p16 not block positive

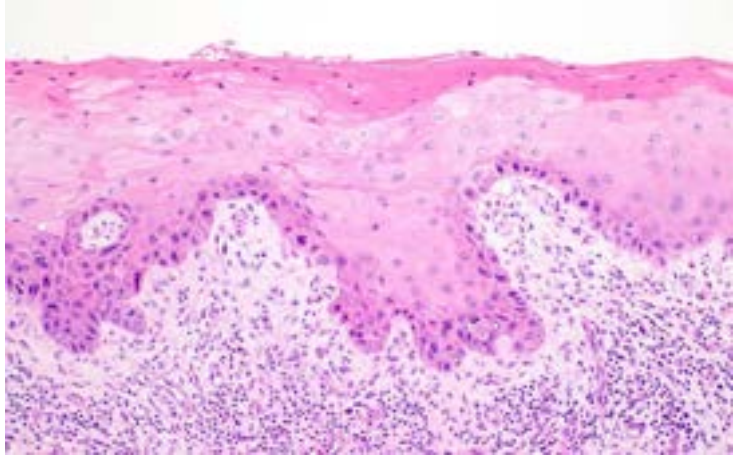

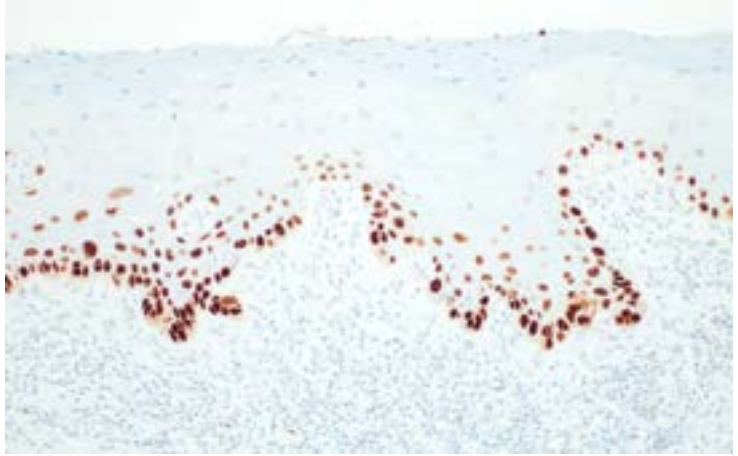

Abnormal Maturation/Keratinization

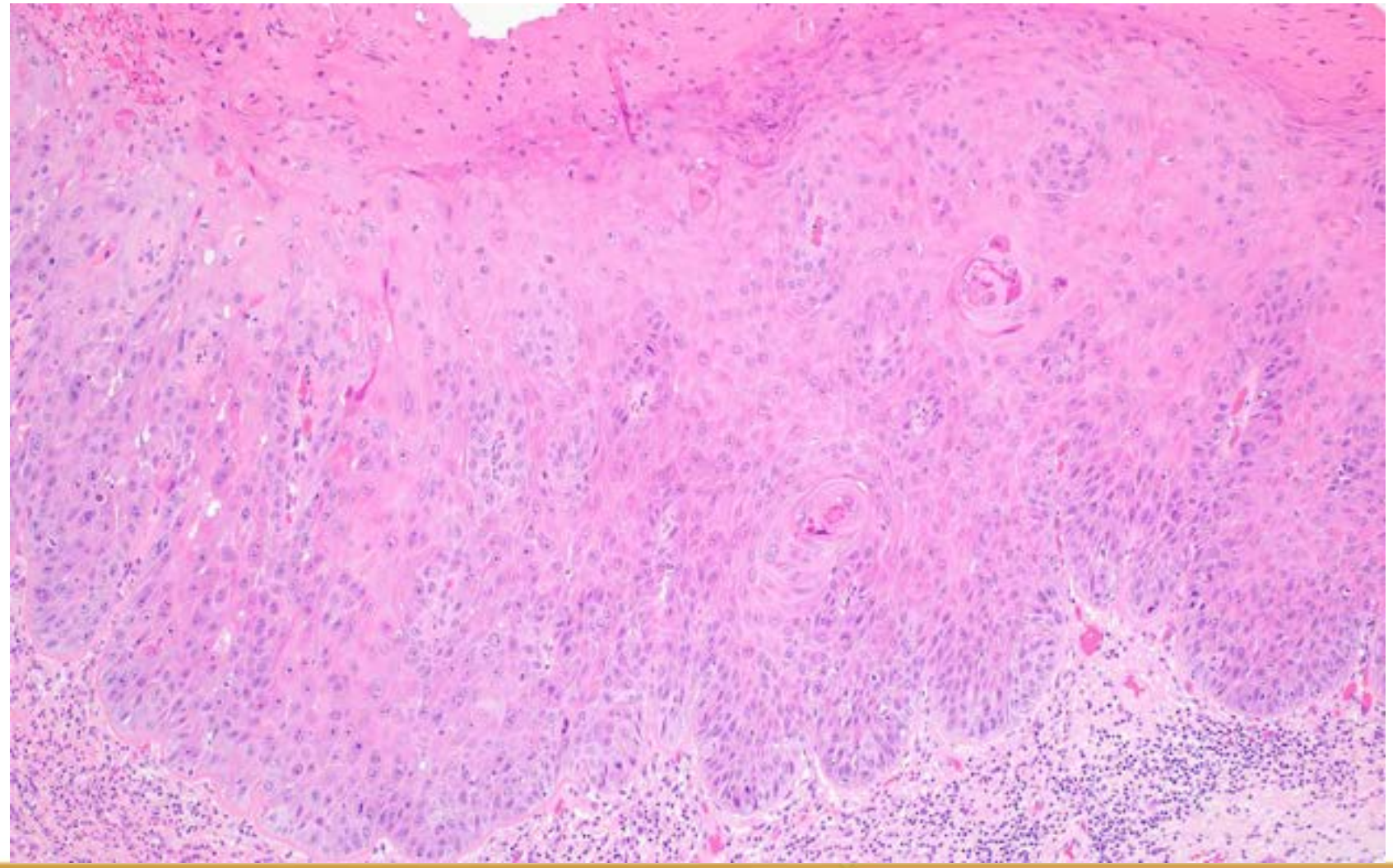

Basal Atypia (May Be Subtle)

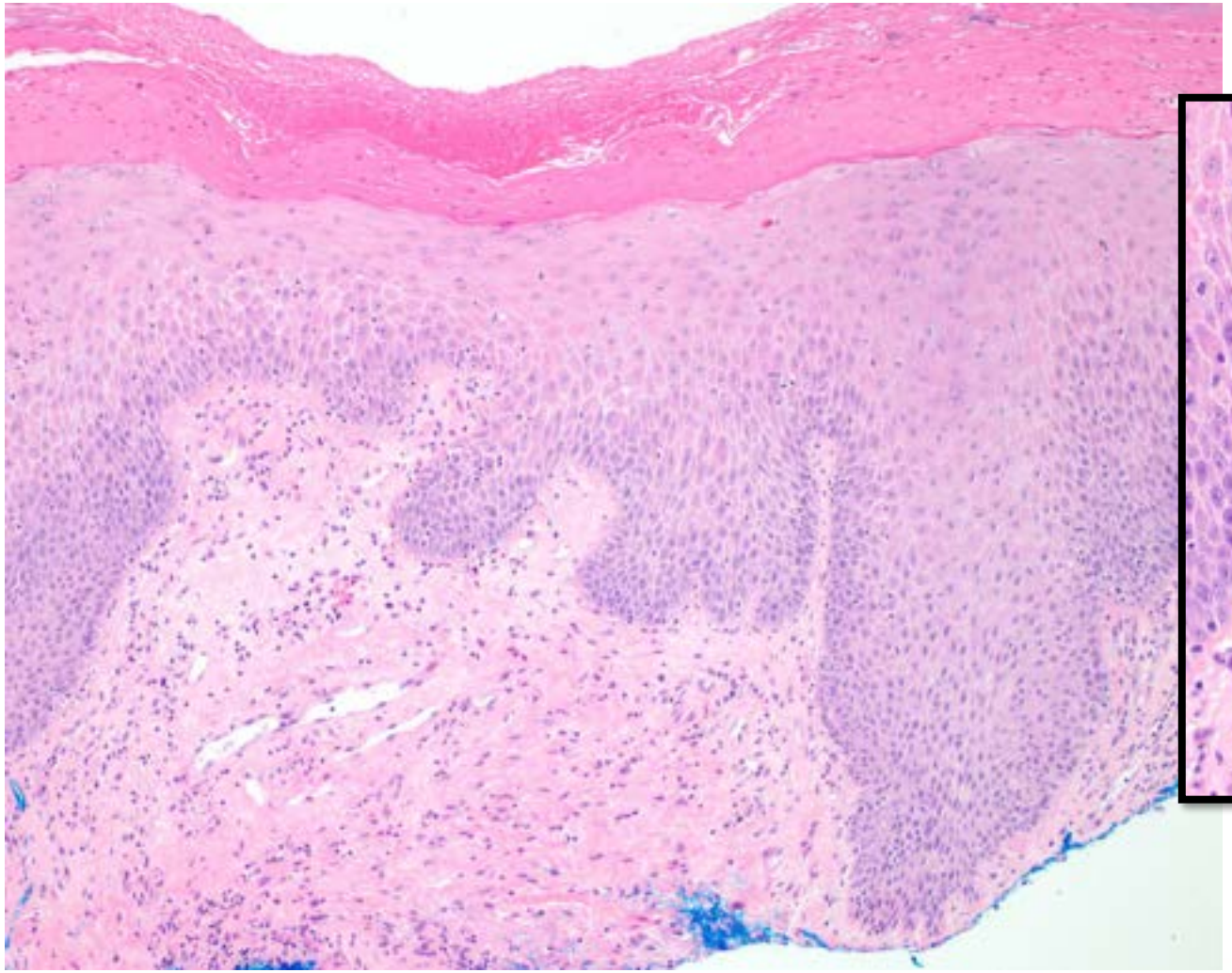

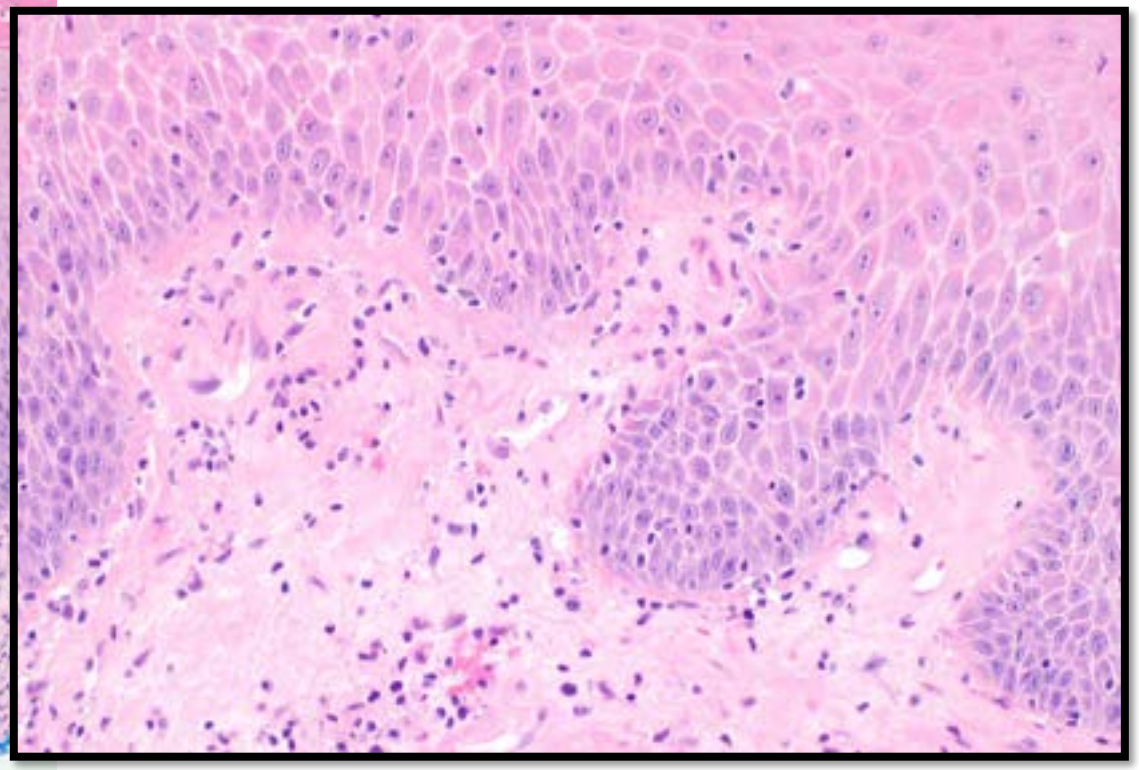

Basal Atypia

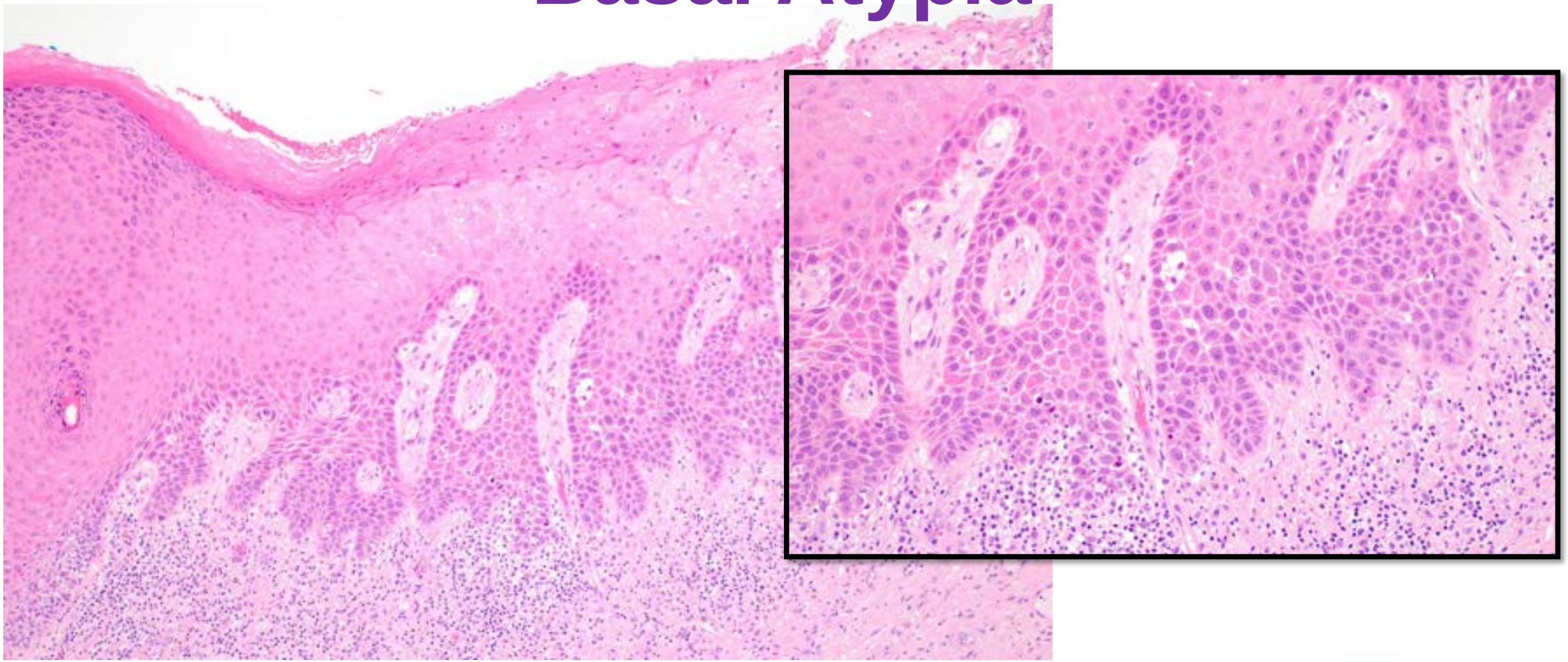

Elongated and Anastomosing Rete

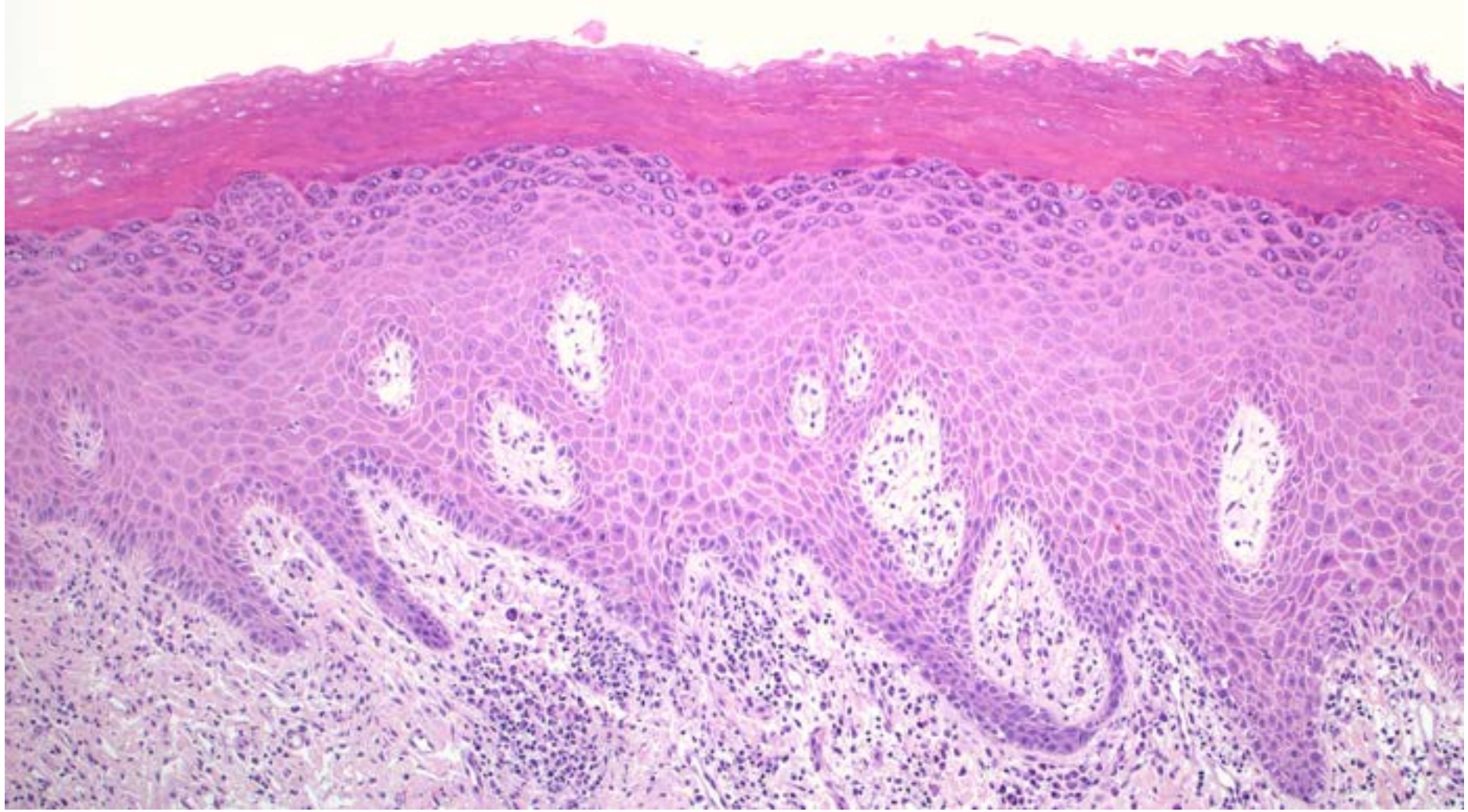

Elongated Rete Ridges

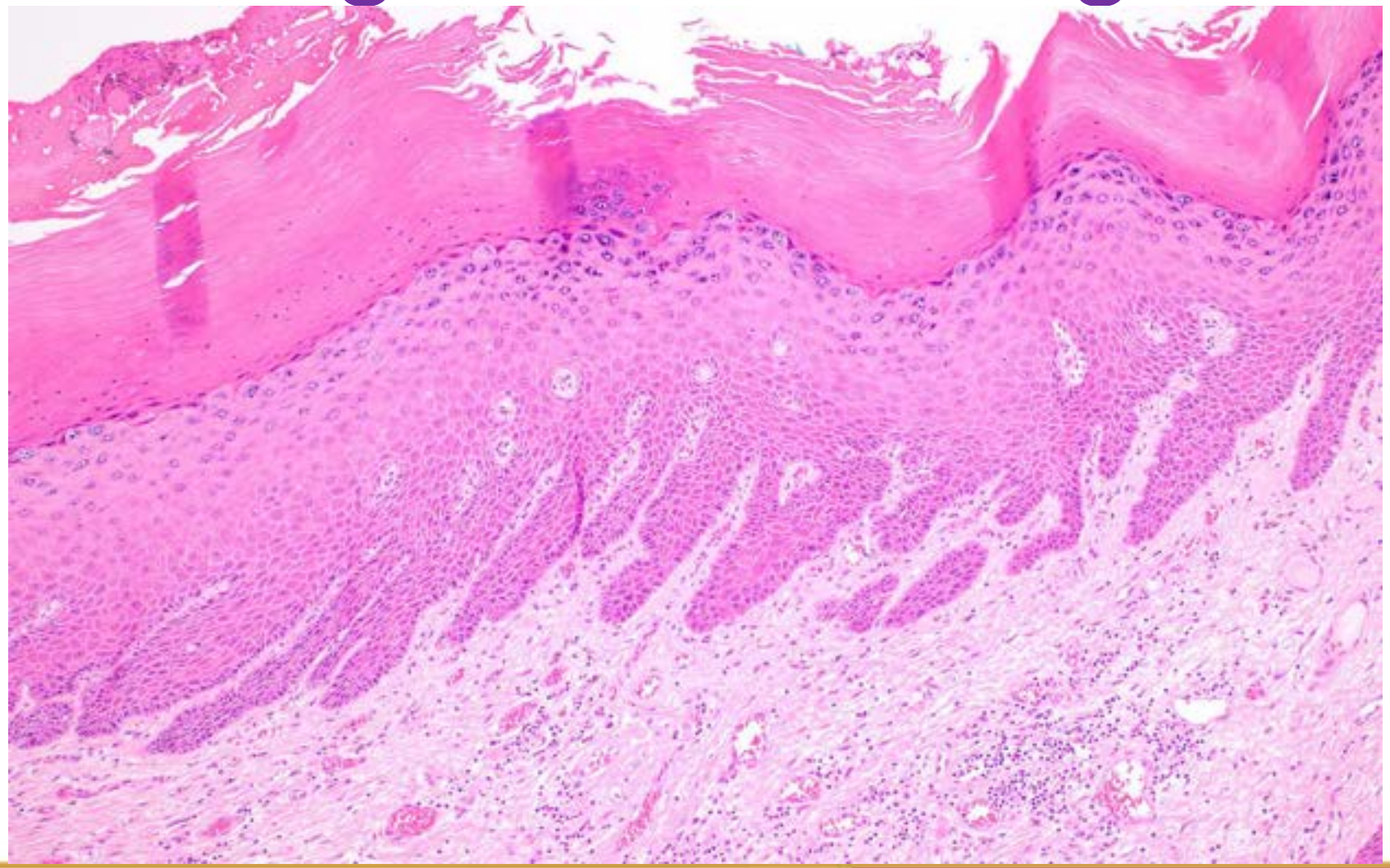

p53 Immunohistochemistry

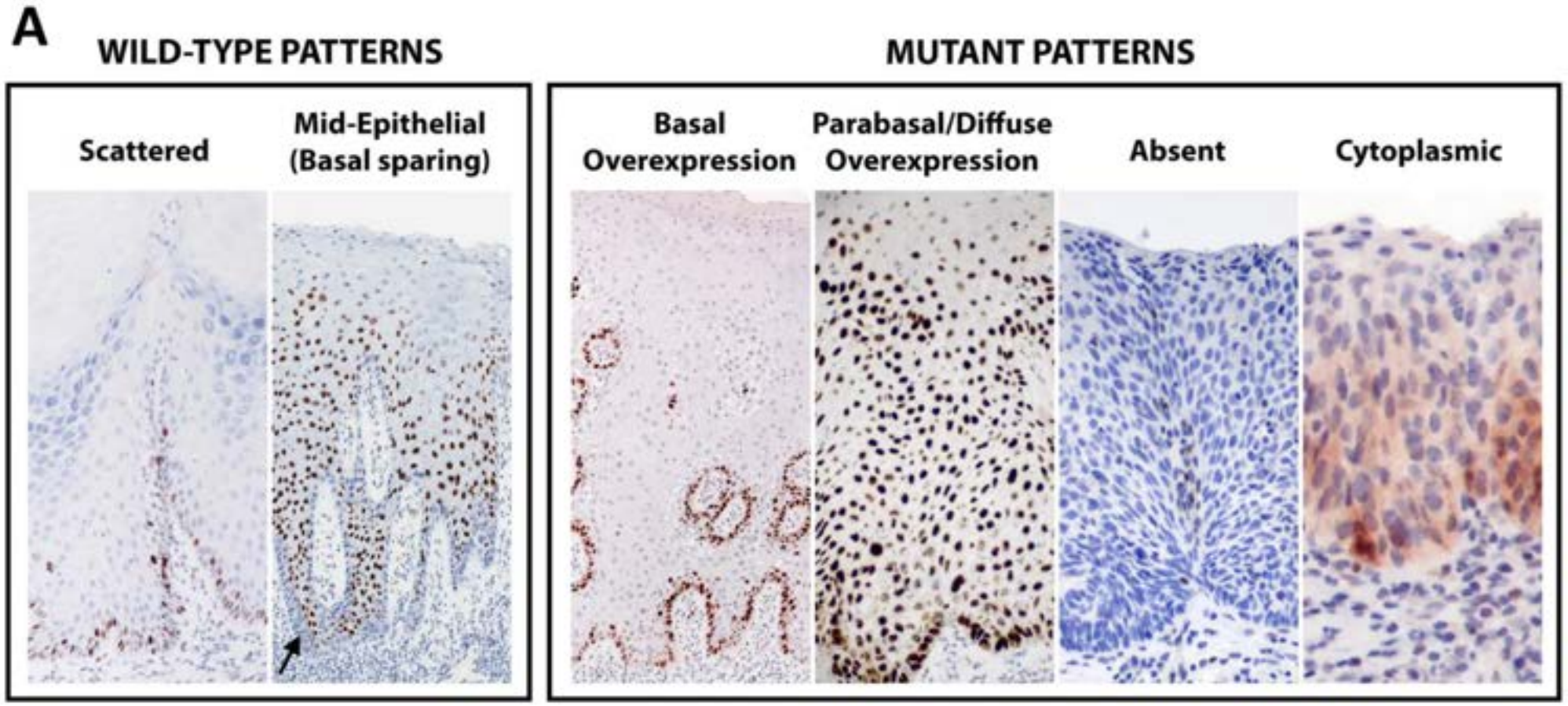

Tessier-Cloutier B, et al. *Mod Pathol* 2020;33(8):1595-1605.

HPVi(p53wt) vaVIN / VAM

- May show background of lichen sclerosus or lichen simplex chronicus
- Presentation as a clinically discrete lesion in a patient ≥60 yo should raise concern
- Consider excision with negative margins vs close surveillance with follow-up biopsies

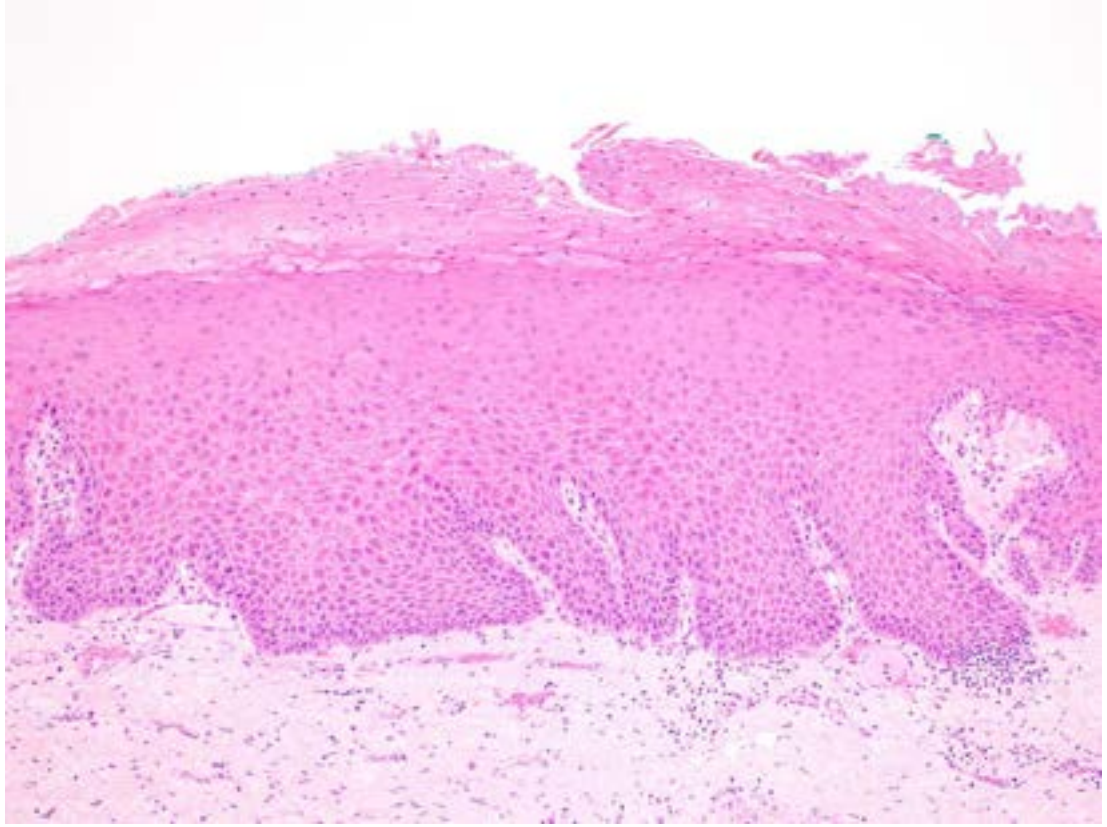

HPVi(p53wt) vaVIN / VAM

- Verruciform and/or acanthotic architecture
- Absent to mild basal/parabasal atypia
- Absence of p53 abnormality
- DEVIL
  - Acanthotic/verruciform architecture
  - Abnormal keratinocyte differentiation
- VAAD
  - Epithelial pallor or eosinophilic change
  - Hypogranulosis
  - Parakeratotic hyperkeratosis
- vLSC
  - Hypergranulosis
  - Thick hyperkeratosis
  - Absence of eosinophilic change or pallor

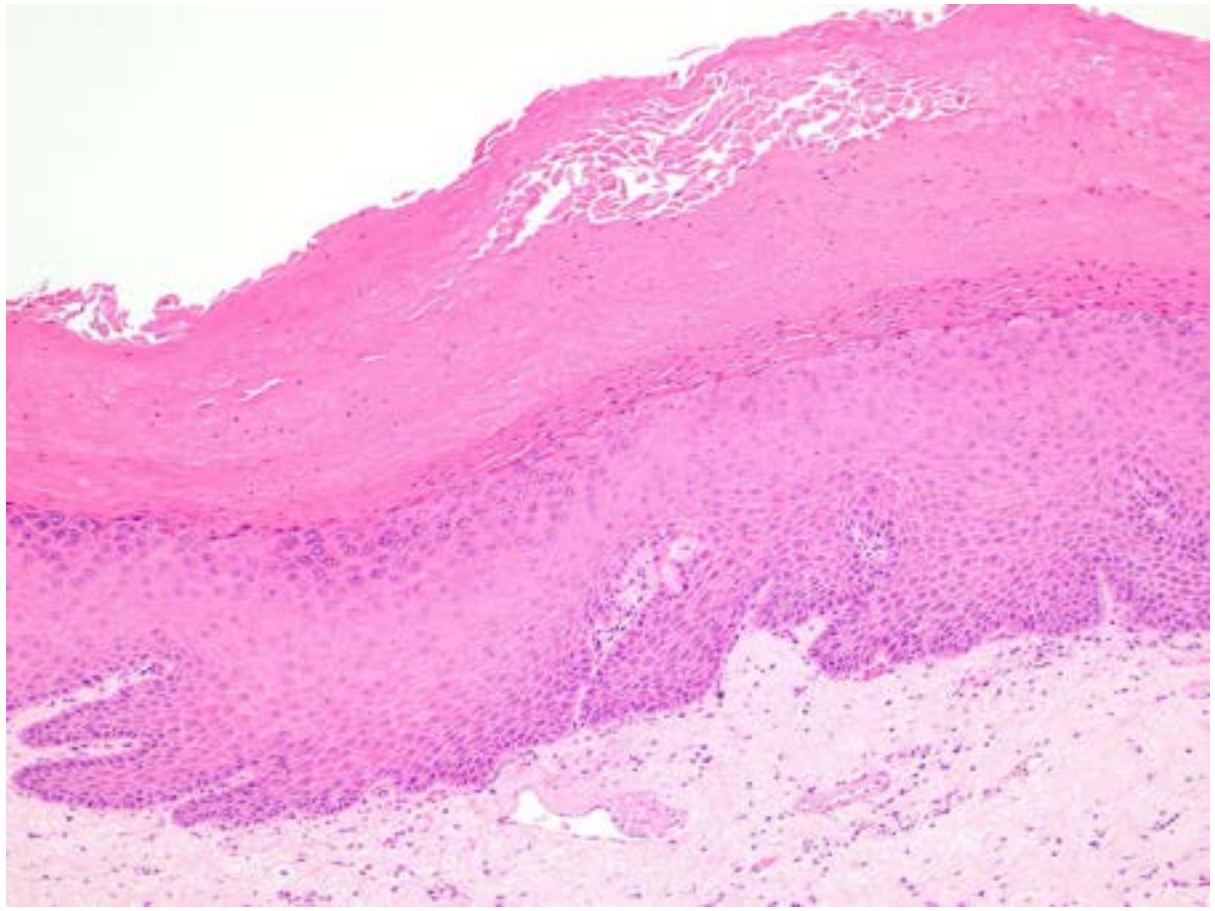

CASE 1a

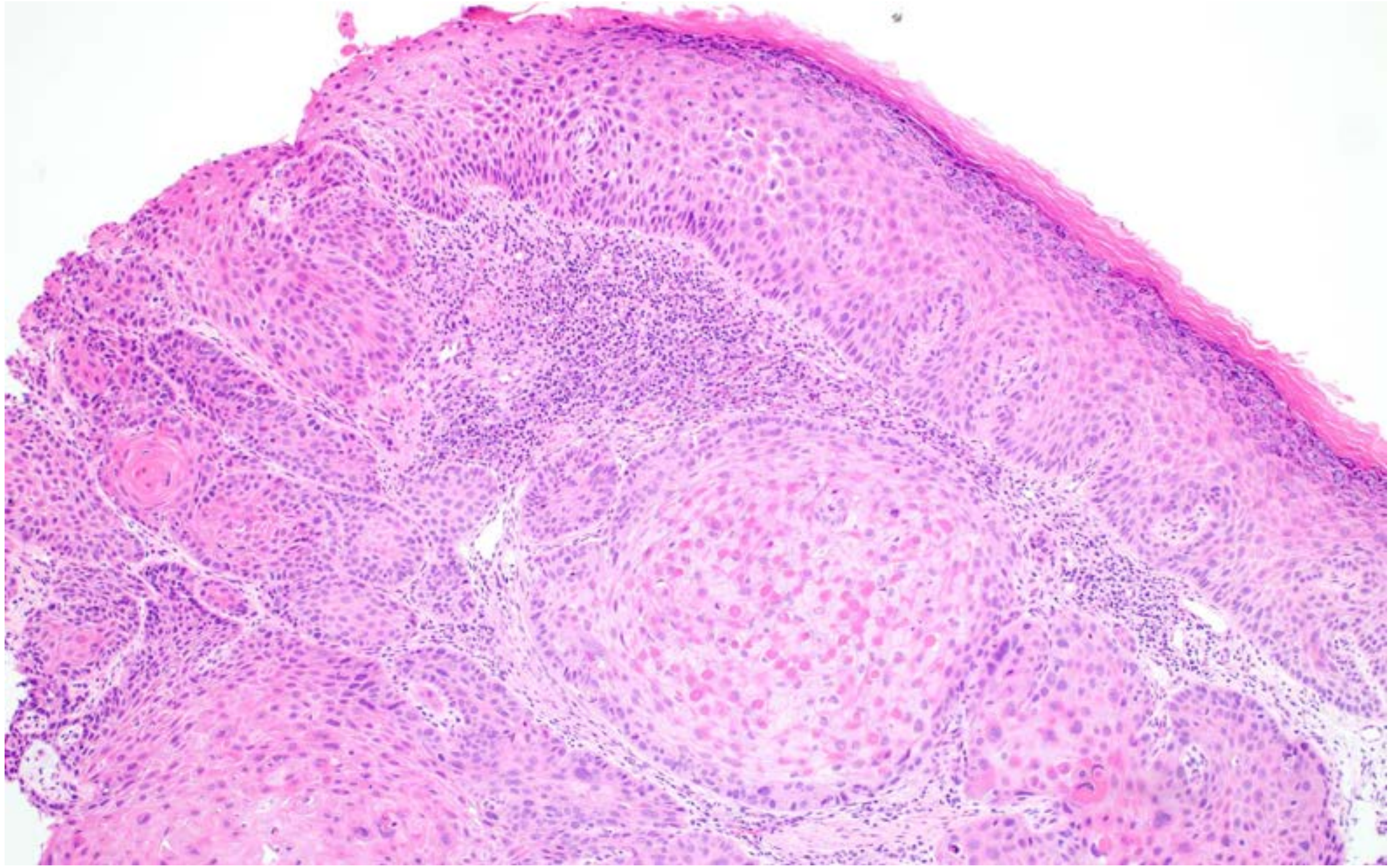

p53

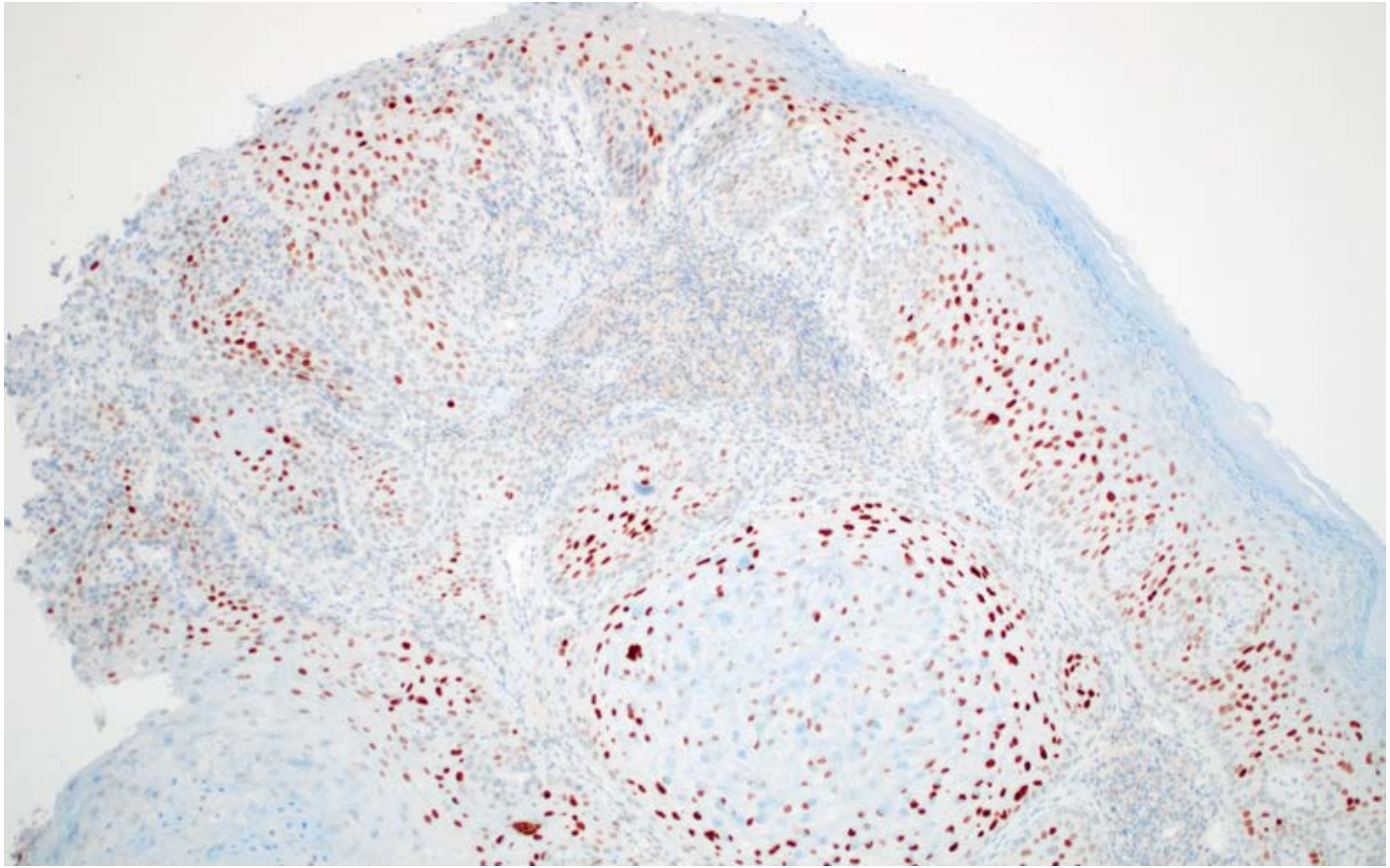

p16

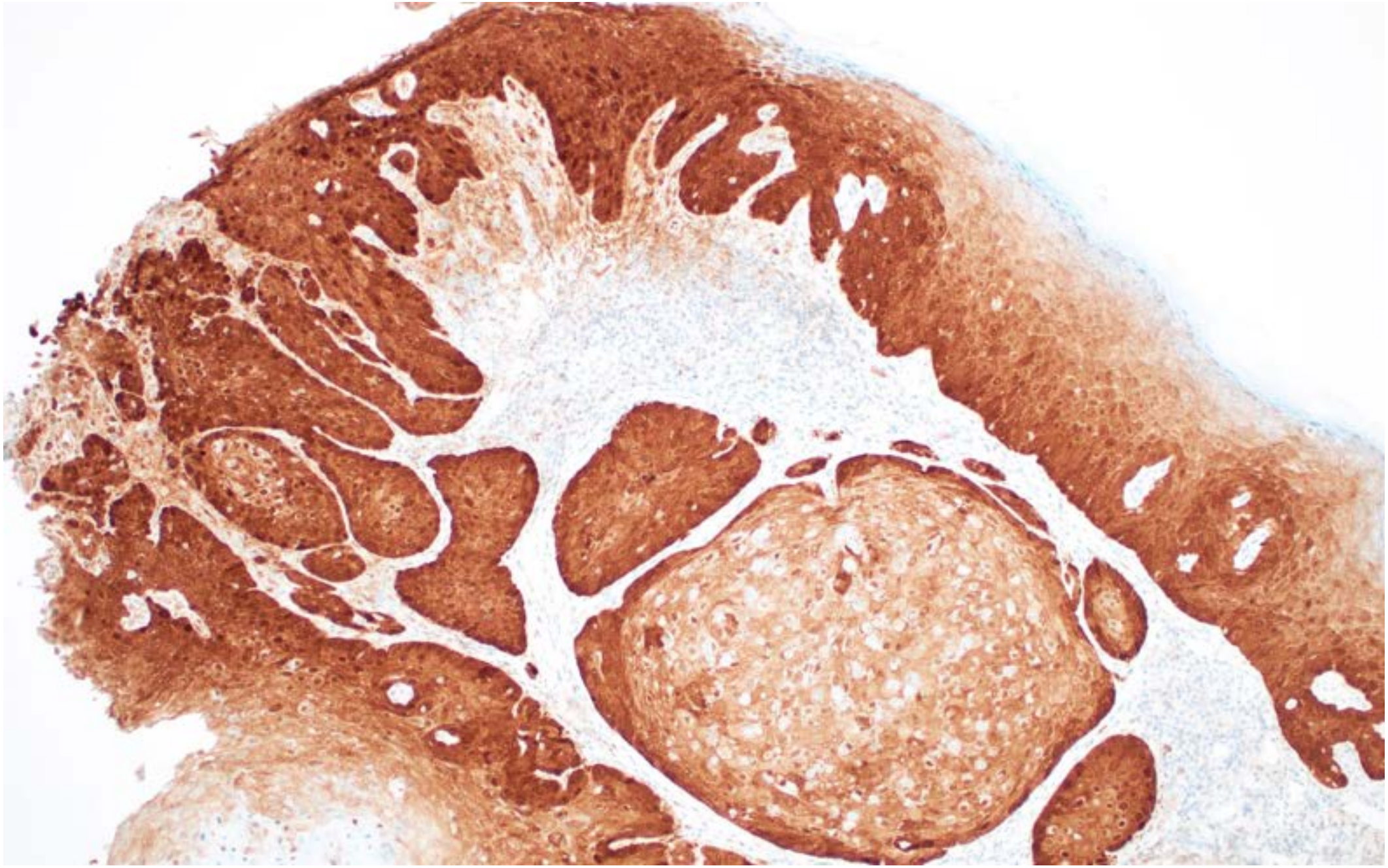

hrHPV ISH

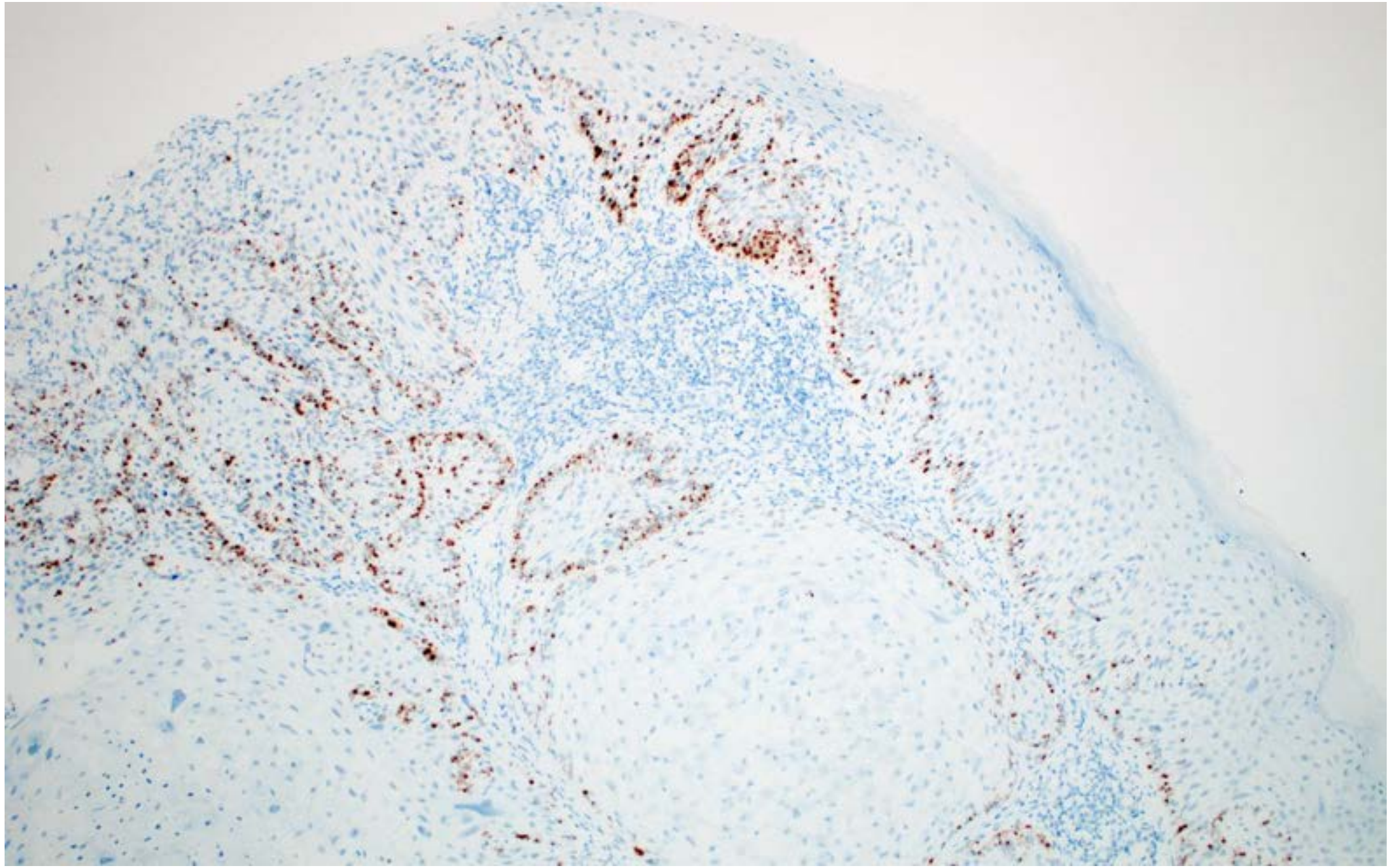

CASE 1b

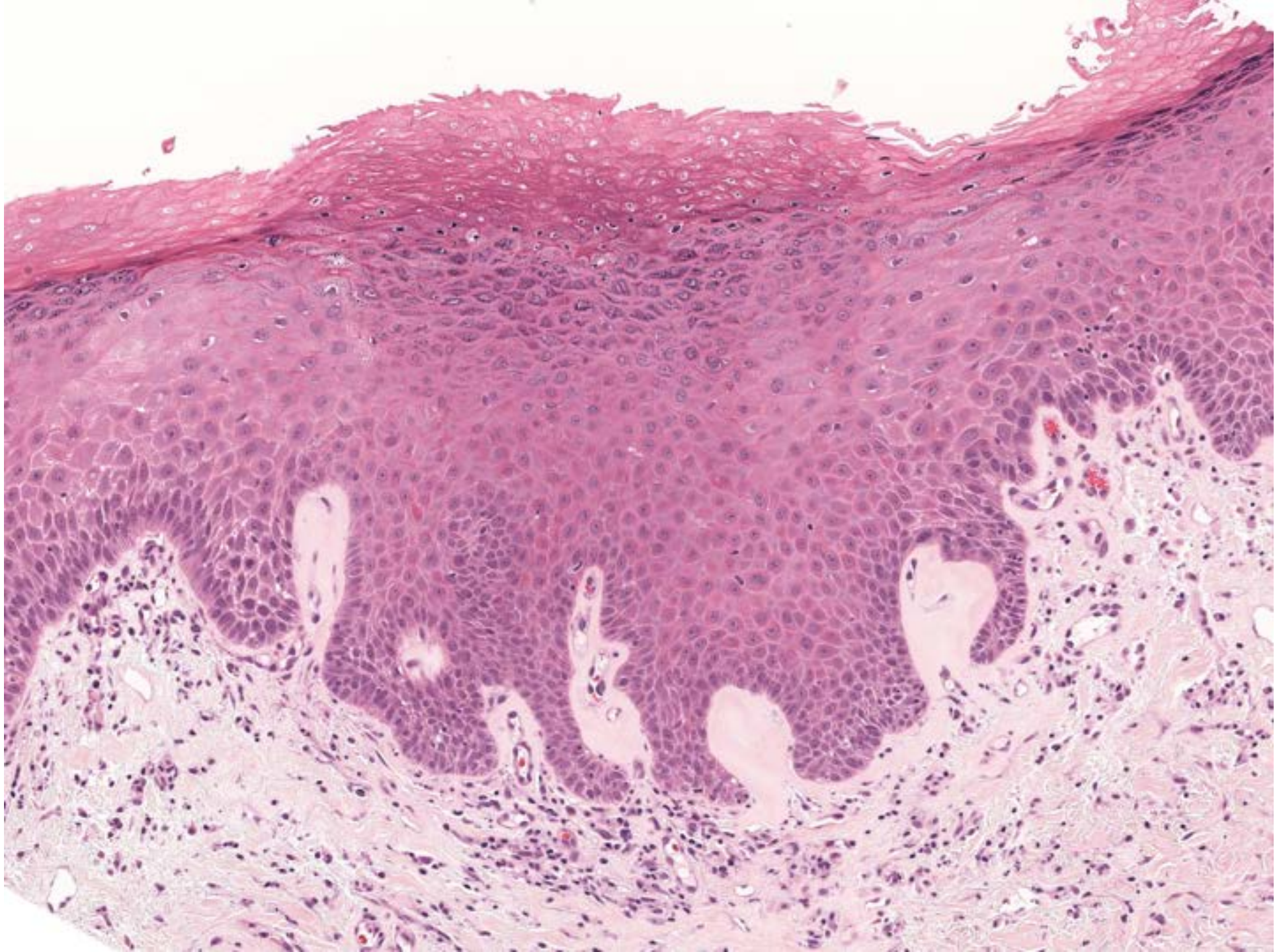

p53

p16

hrHPV ISH

HSIL with Morphologic Features Mimicking dVIN

- Features similar to dVIN with some exceptions*:
  - May be full thickness cytologic atypia
  - Cytologic atypia may be more severe than expected for dVIN
- Block positive p16 (sometimes limited to base), mid-epithelial p53 staining sparing base, HPV ISH often limited to base
- Areas with more conventional HSIL morphology may be seen nearby
- Lichen sclerosus may also be seen nearby
- Average age seems to be ~60s

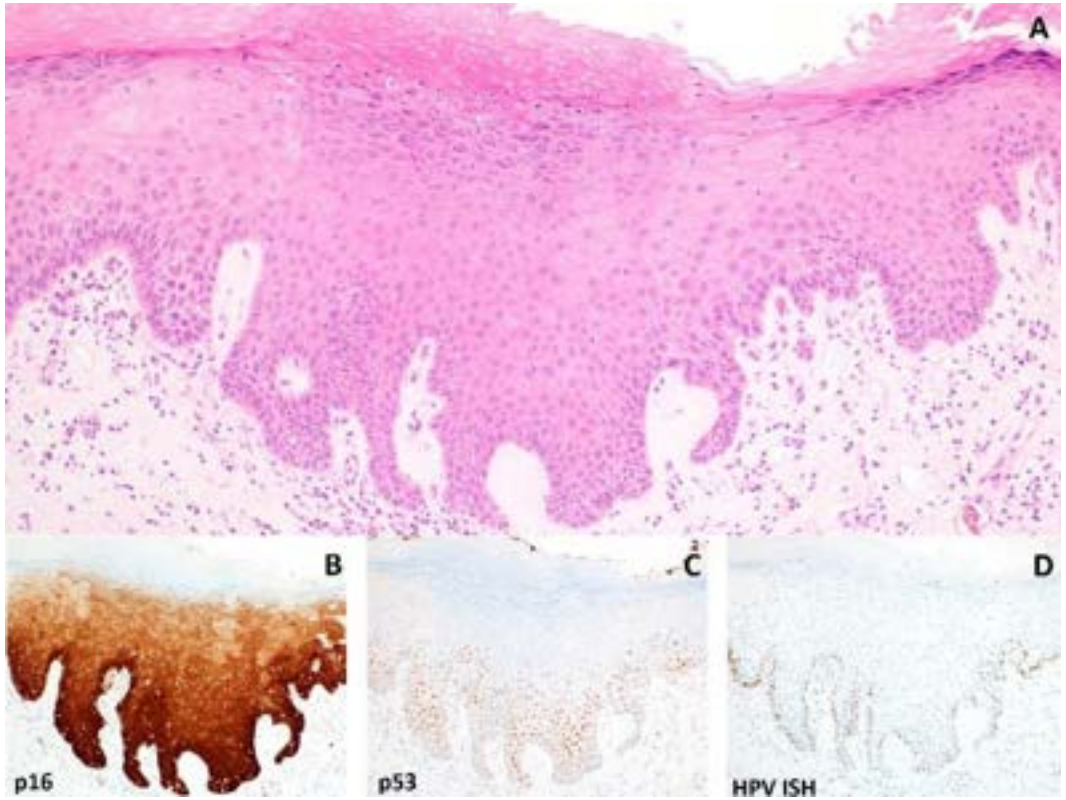

Griesinger L, et al. *Int J Gynecol Pathol* 2021;40(3):205-213.

ISSVD Recommendations for dVIN

- Aim for universal clinical photography of suspected dVIN and VAM
- Obtain biopsies from morphologically distinct areas, as dVIN and VAM may be multifocal and have a different appearance at each site
- Document presence of LS and/or LP and previous diagnoses of HSIL, VAM, dVIN, or SCC on pathology request forms
- Pathologists may need to solicit additional information from clinicians if clinical notes are insufficient as to history and examination findings
- Universal p16 and p53 in cases of suspected squamous neoplasia are advisable because dVIN and HSIL cannot be reliably distinguished by routine microscopy
    - If this is not possible, p16 and p53 are essential in:
        - Biopsies obtained from treatment-resistant lesions within LS
        - Suspected dVIN and VAM
        - Presumed HSIL in women older than 45 years, with comorbid LS/LP, or nonresponse to LASER or imiquimod
- Indicate type of dVIN and presence of LS/LP in pathology reports
- Communication between clinician and pathologist or expert multidisciplinary review is recommended before embarking on cytotoxic, ablative, or extirpative procedures

J Low Genit Tract Dis. 2021; 25(1): 57–70.

CASE 2a

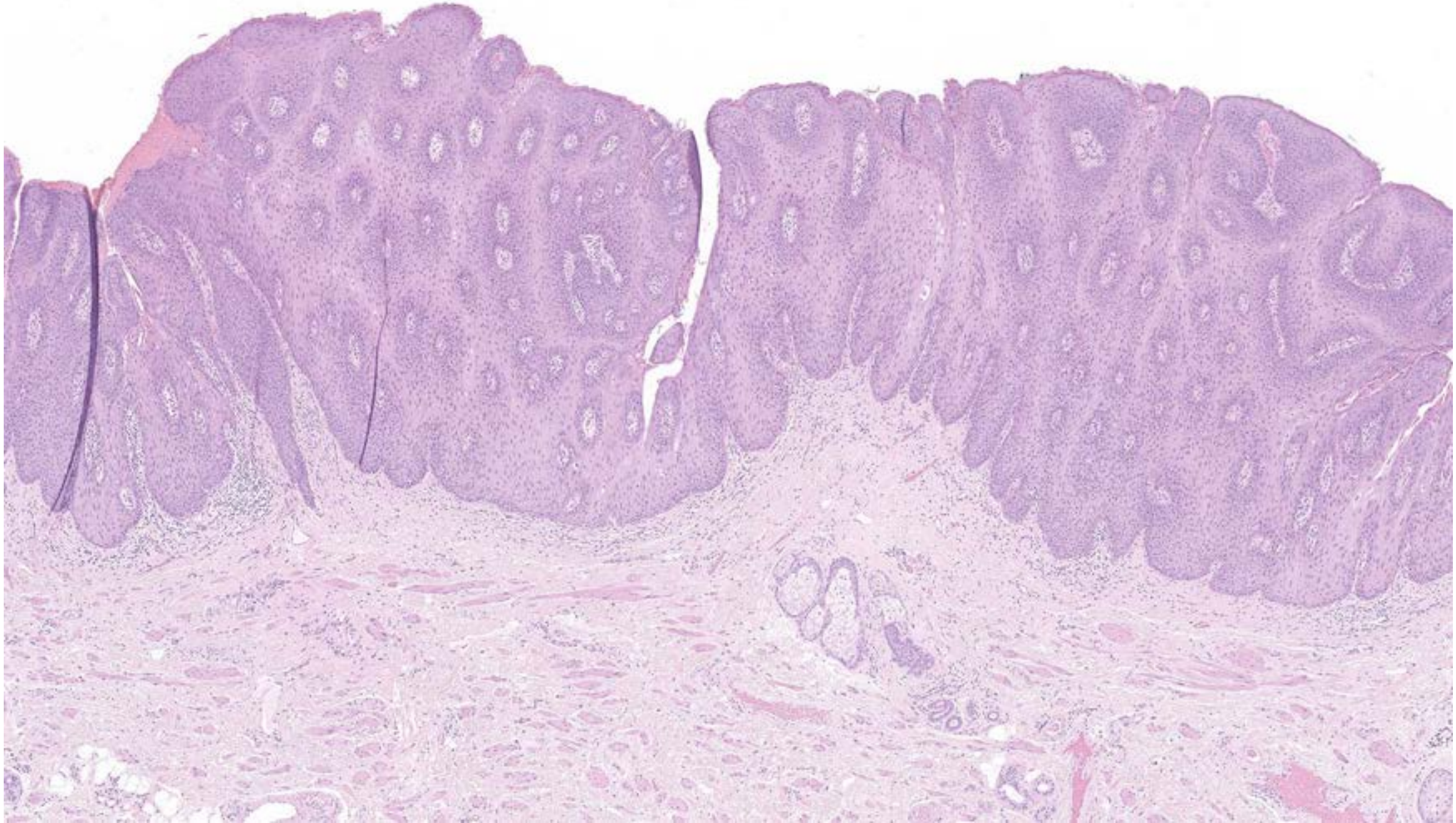

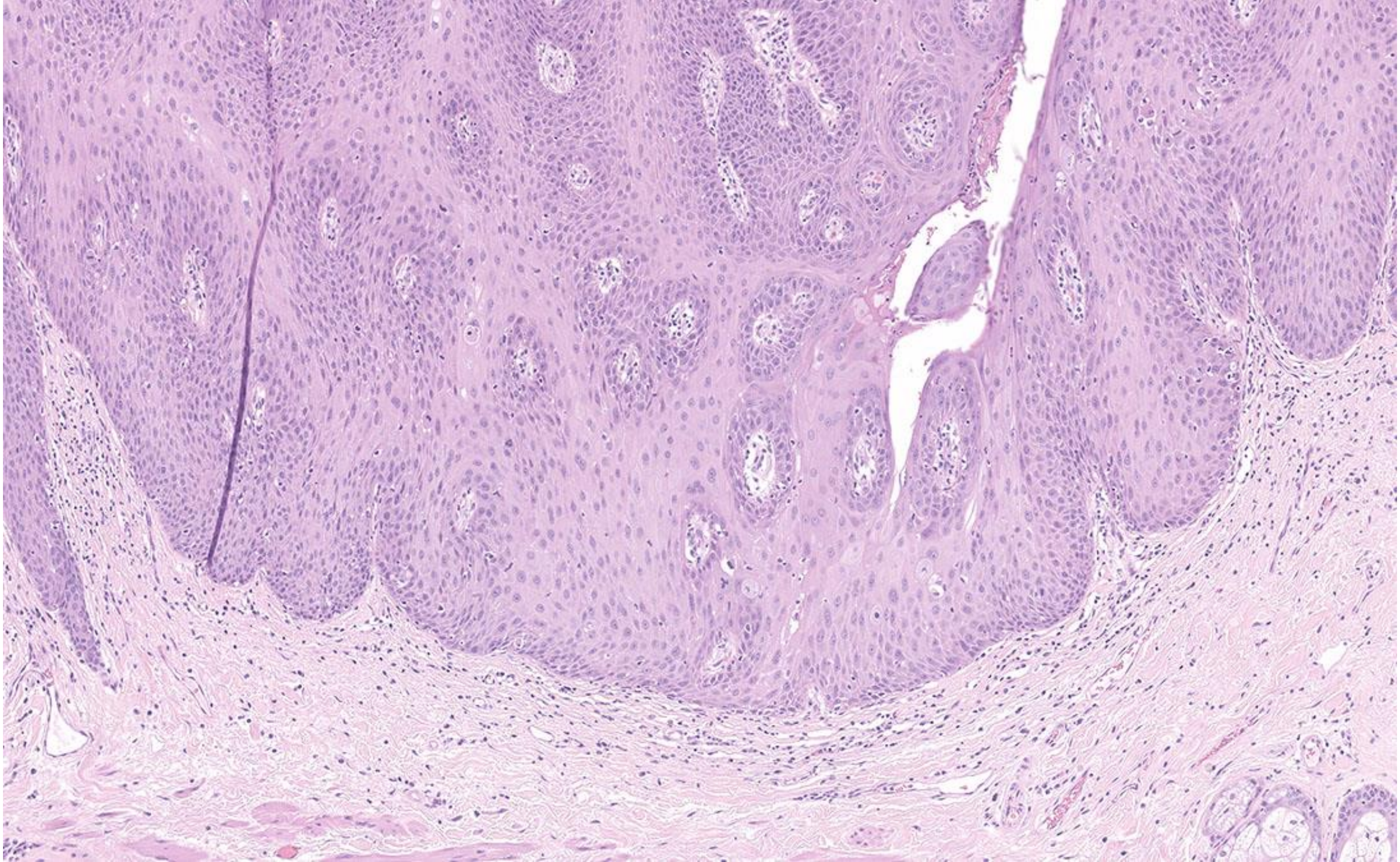

p53/CK17

lrHPV ISH

lrHPV ISH



CASE 2b

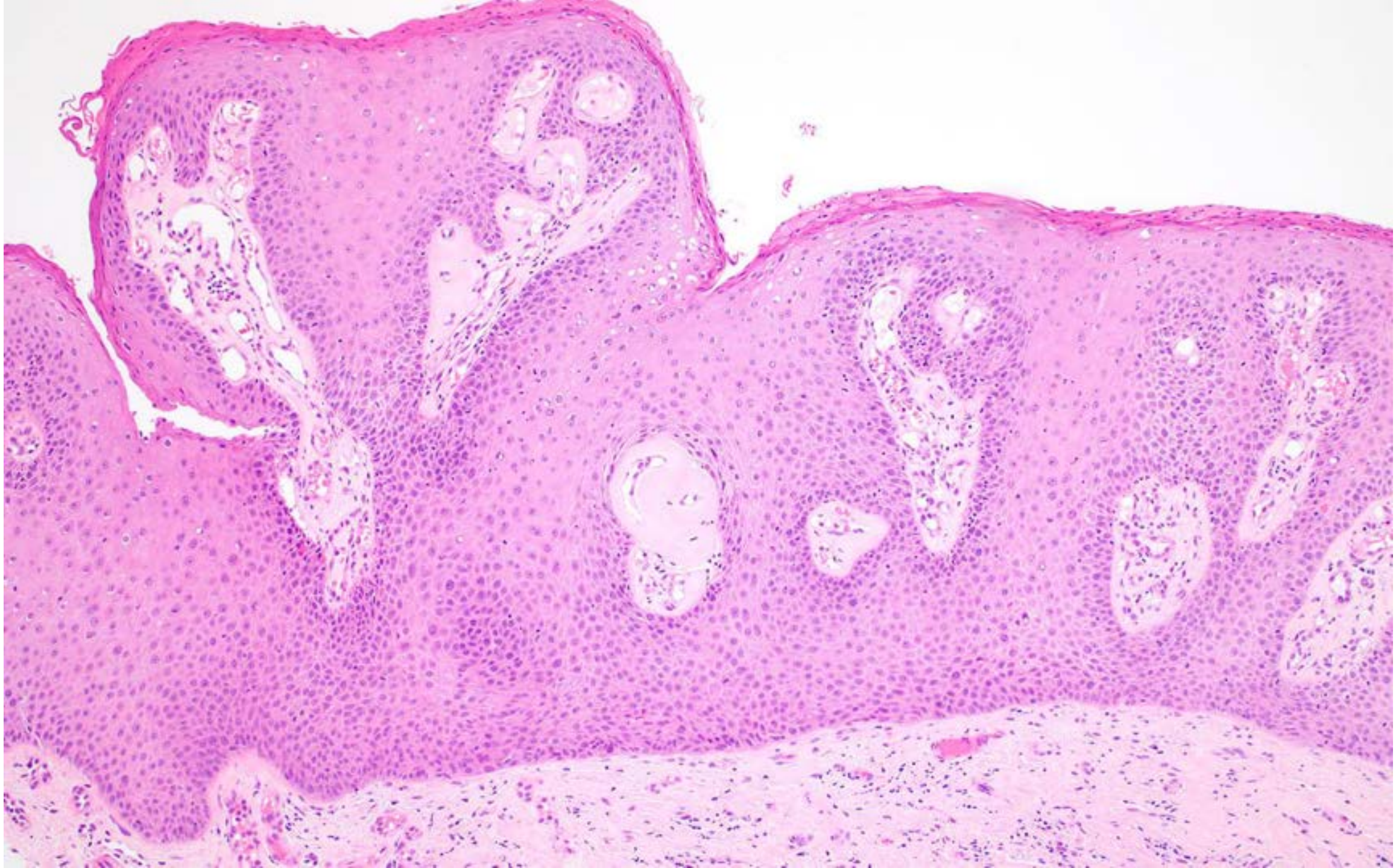

p16

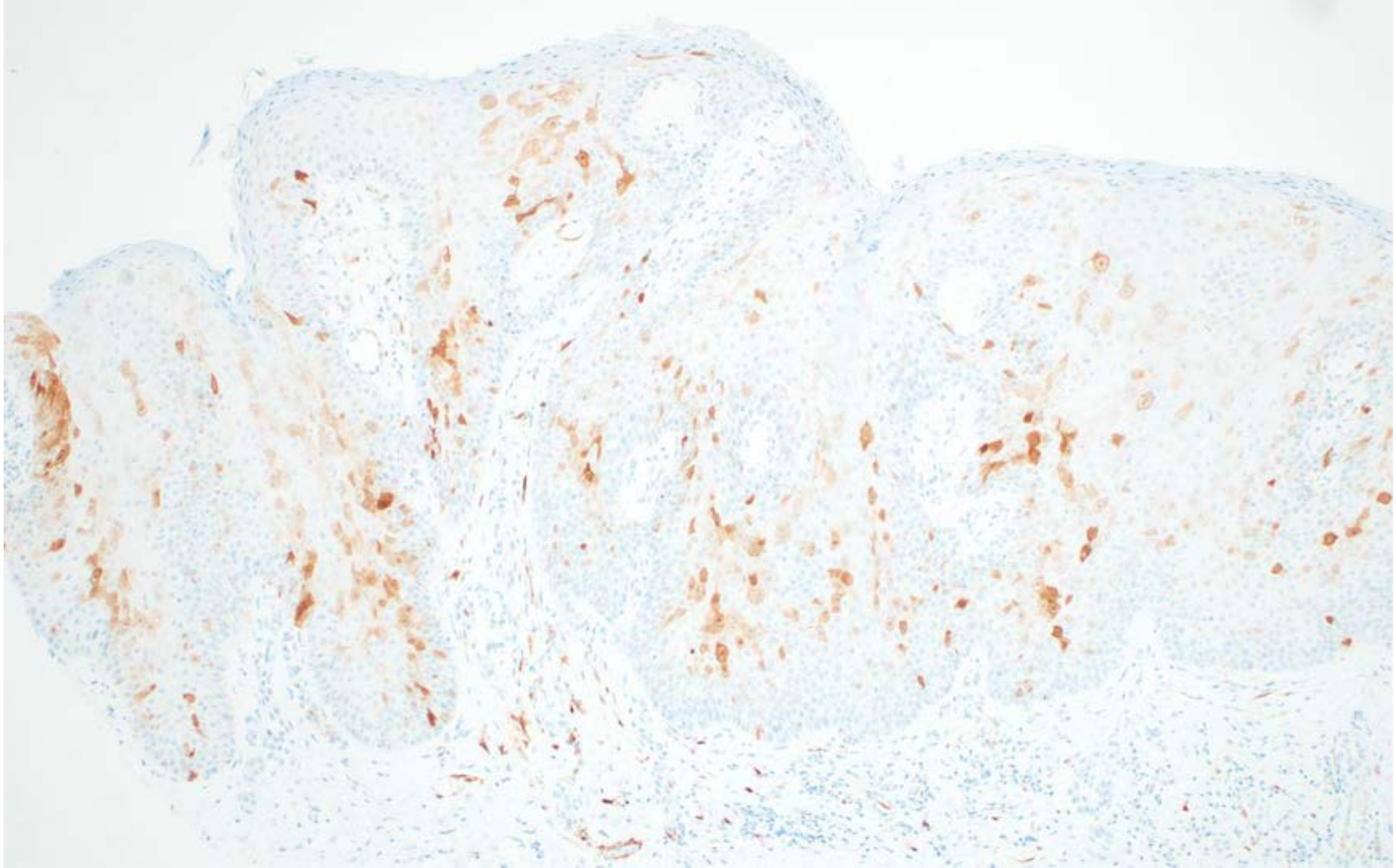

lrHPV ISH

Condyloma

- Morphology overlaps with HPVi(p53wt) vaVIN/VAM
  - Verruciform architecture
  - Acanthosis
  - +/- parakeratosis
  - Variable granular layer

- Key differences from HPVi(p53wt) vaVIN/VAM
  - Caused by low-risk HPV (usually type 6 or 11)
  - Koilocytic changes more likely
  - Lack cytoplasmic pallor

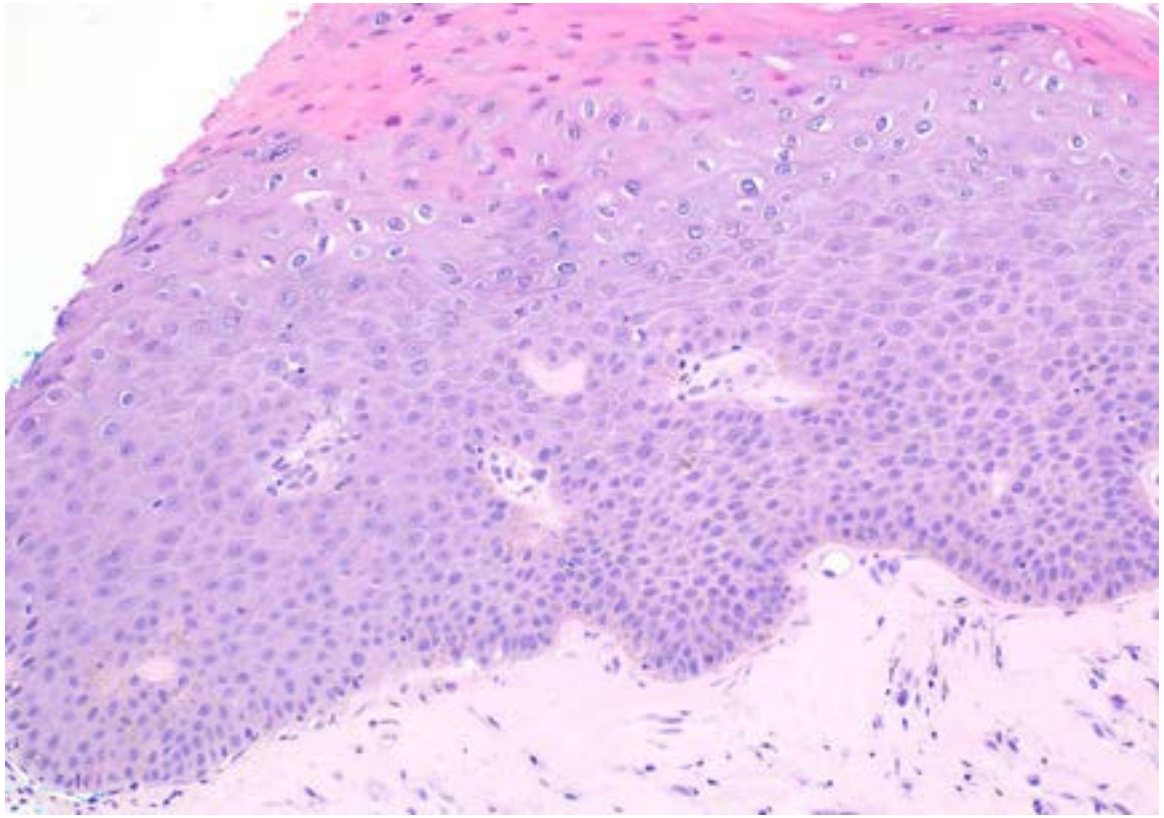

CASE 3a

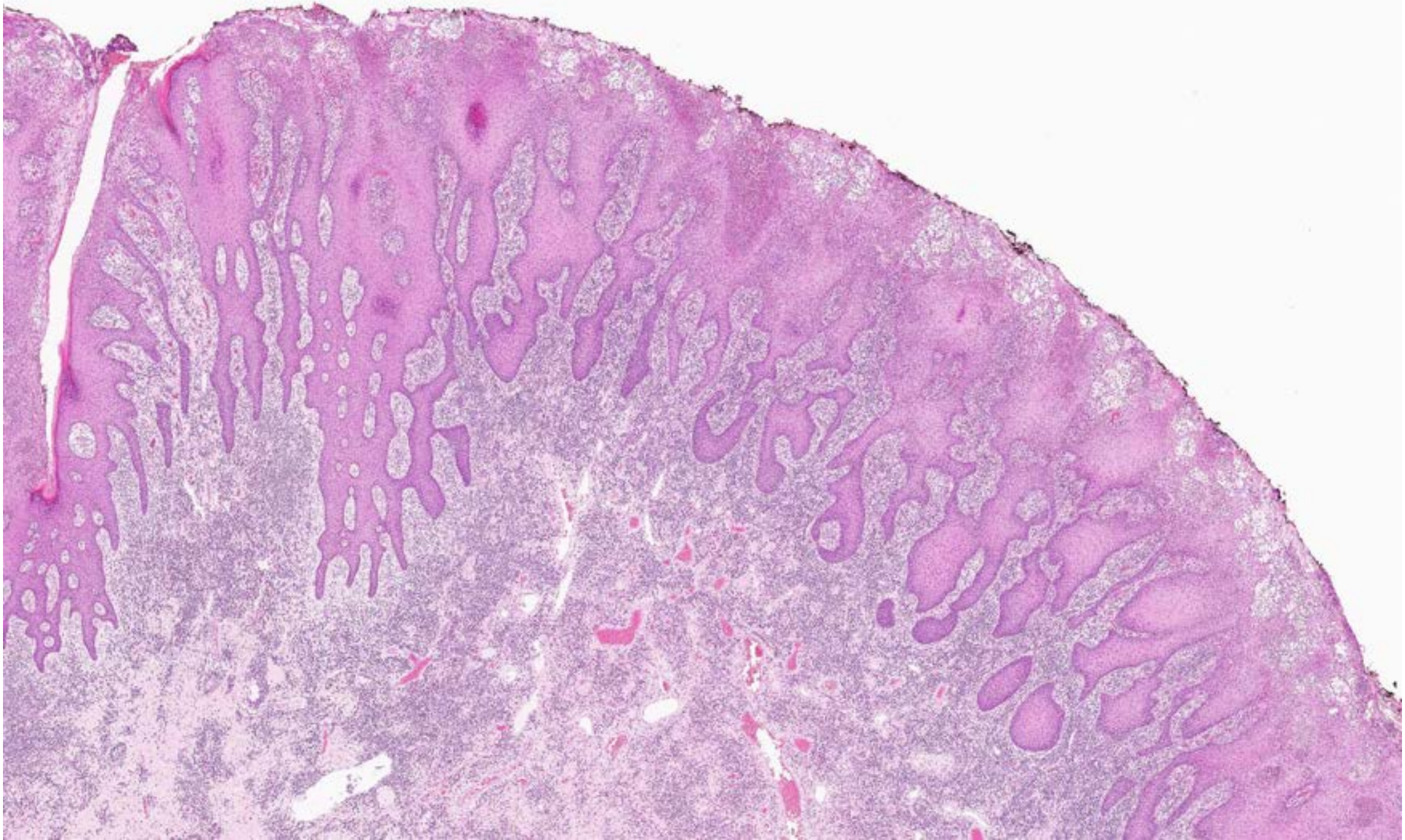

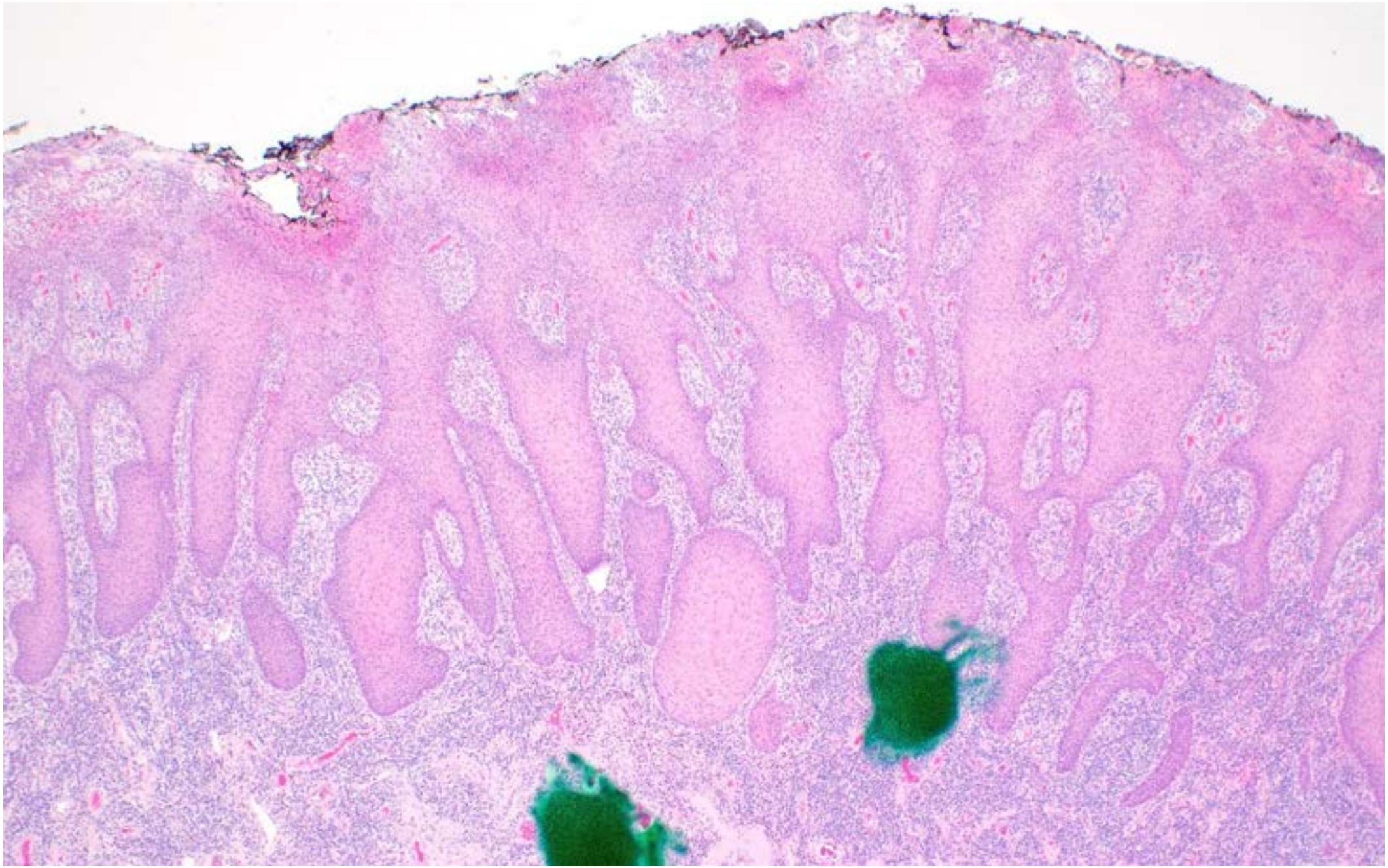

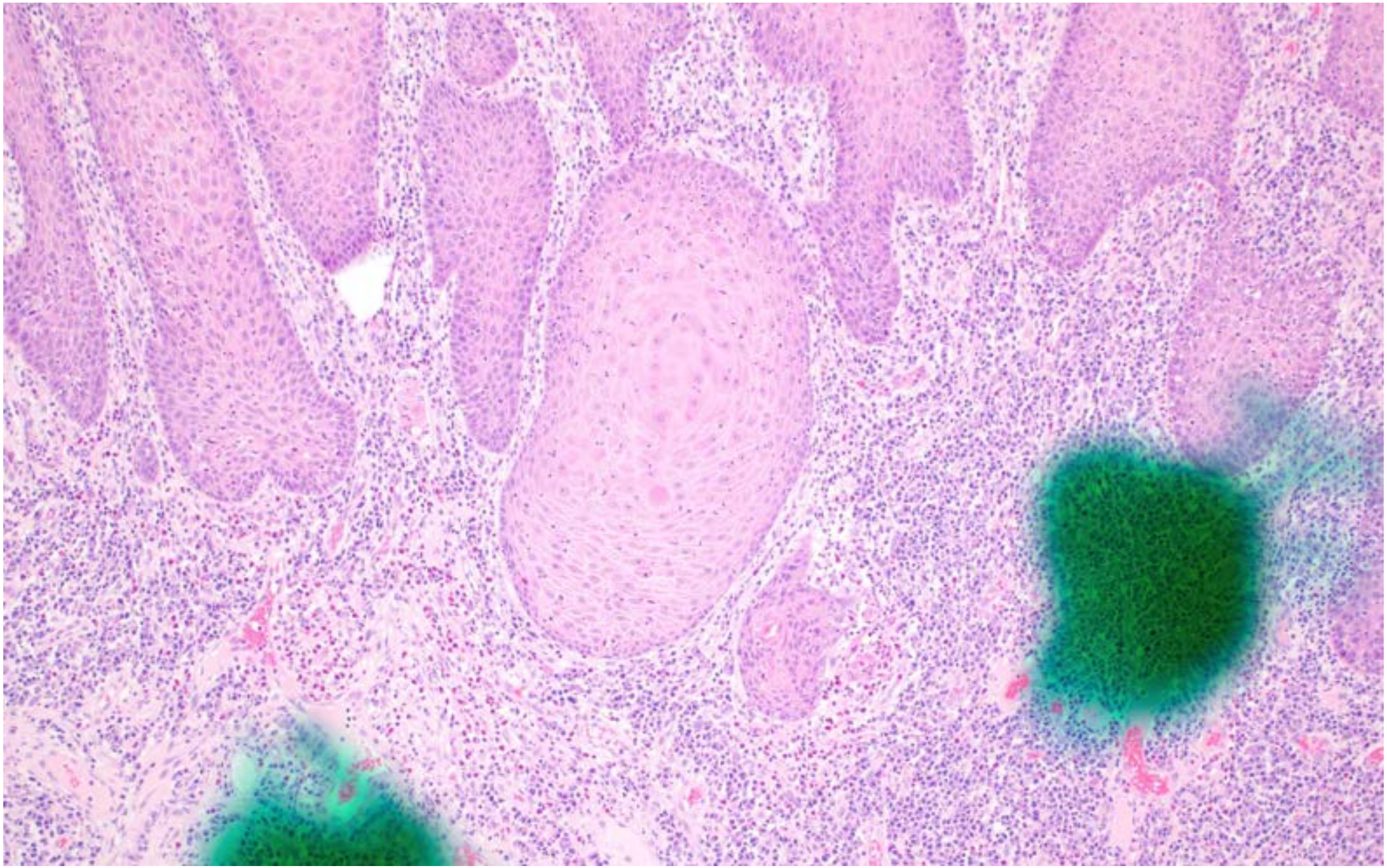

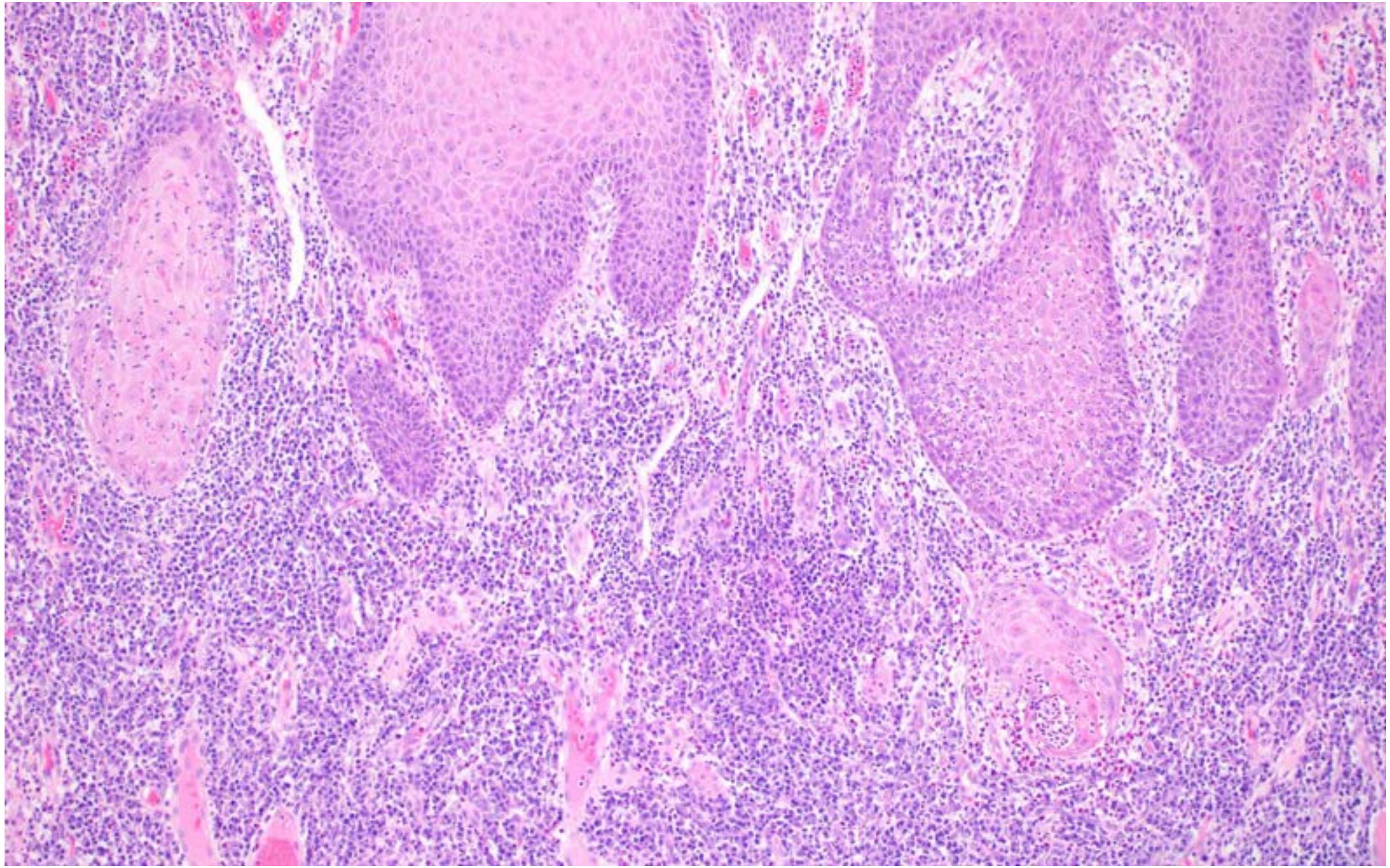

p53

Spirochete

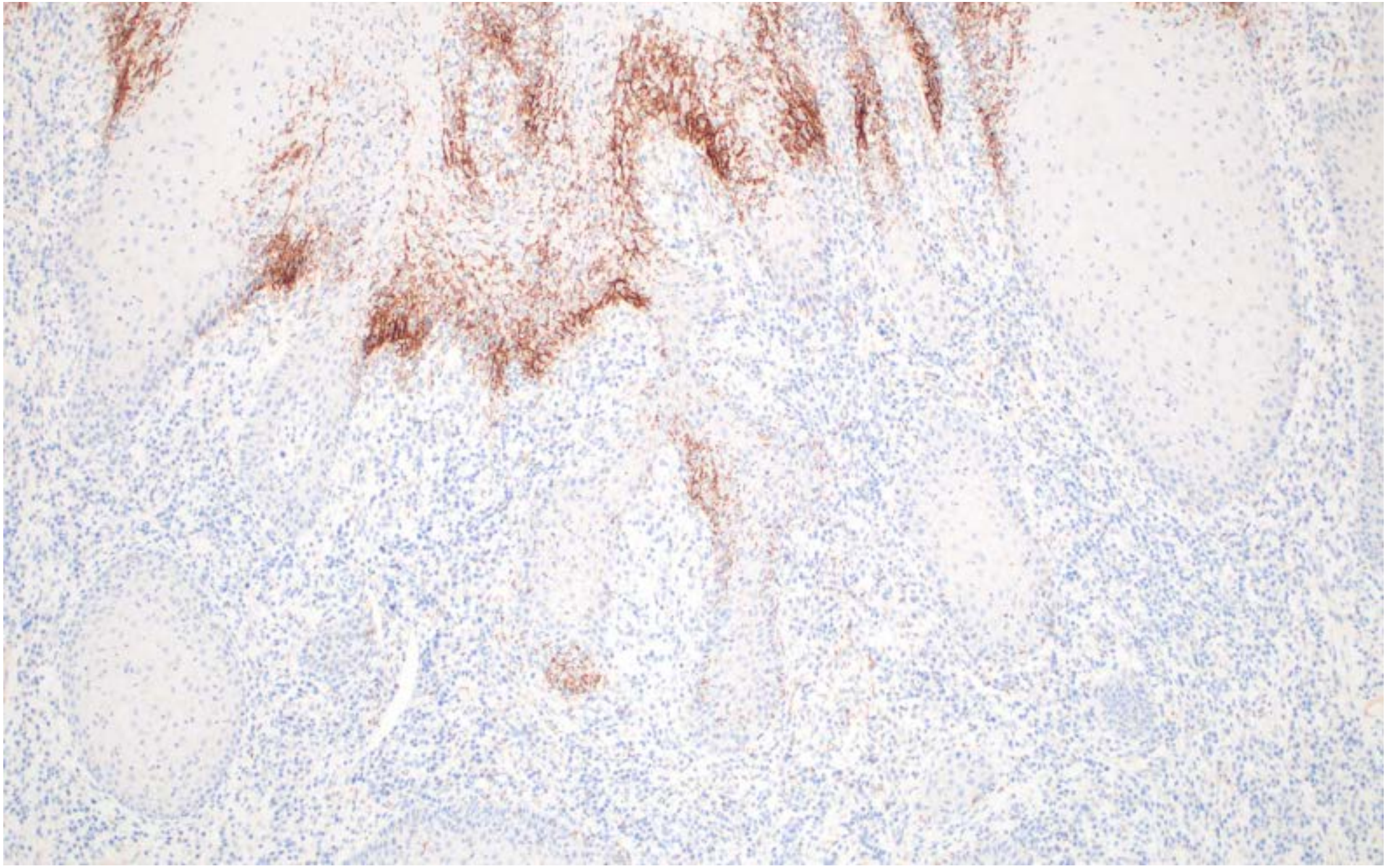

Spirochete

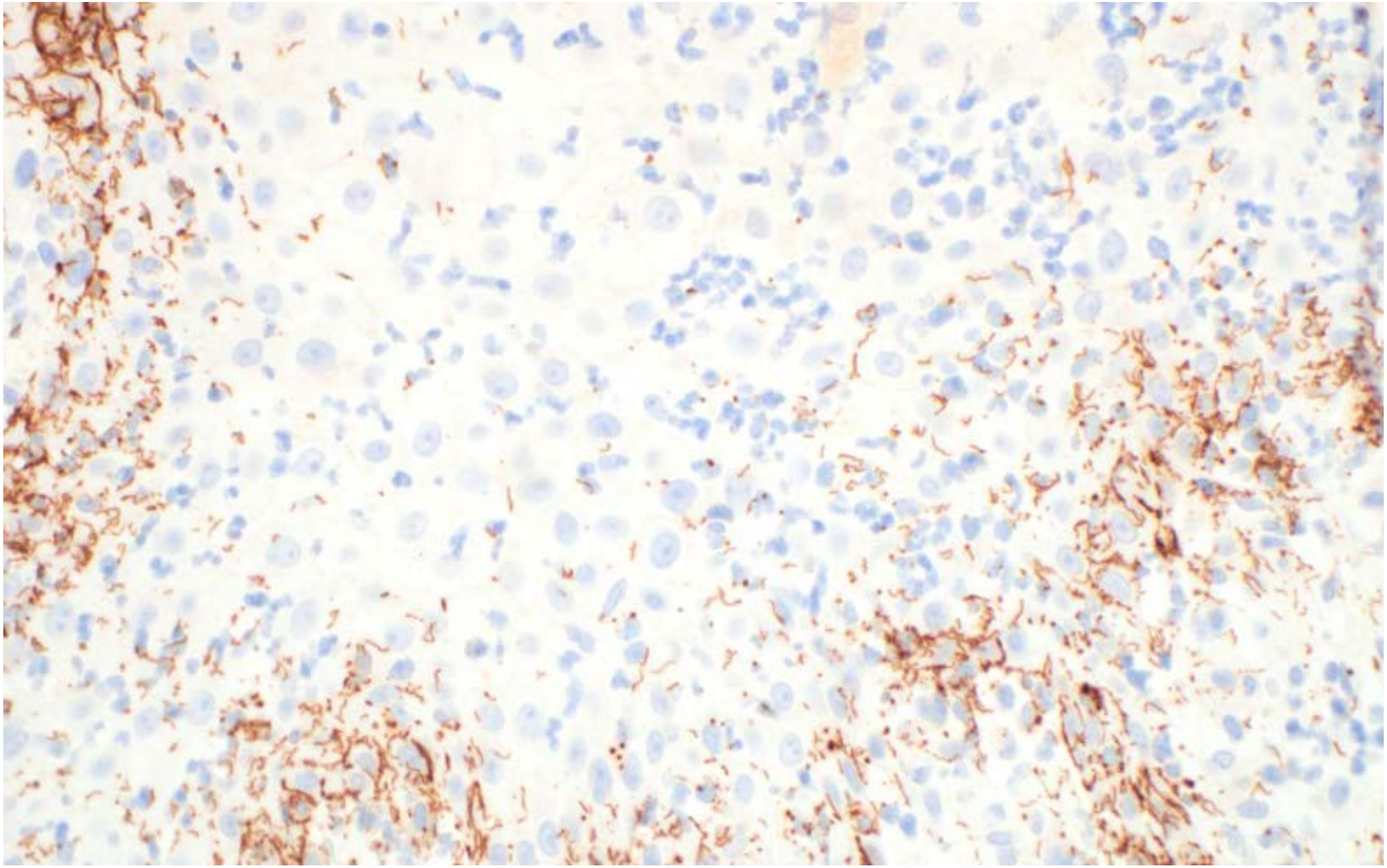

Syphilis / Condyloma Lata

- Morphology overlaps with HPVi VIN
  - Acanthosis and hyperkeratosis
  - Often lichenoid inflammatory infiltrate
  - Pseudoepitheliomatous hyperplasia may mimic invasion

- Key differences from HPVi VIN
  - Marked intraepithelial acute inflammation
  - Marked dermal chronic inflammation including plasma cells
  - May see plasma cell endarteritis
  - Unusual combinations of psoriasiform, lichenoid, spongiotic, and granulomatous patterns*
  - Positive spirochete stain

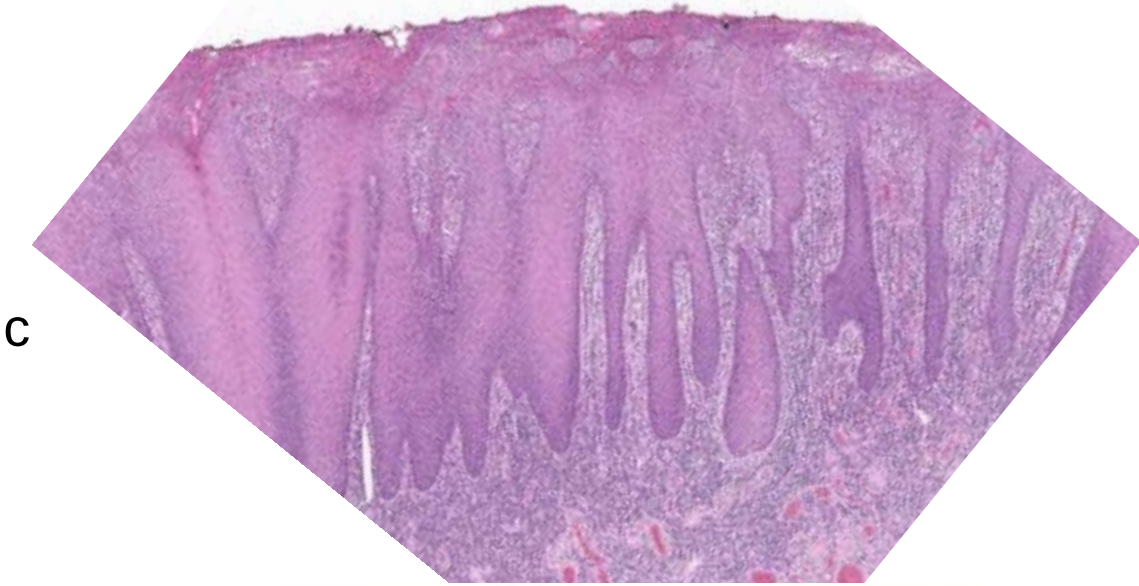

CASE 3b

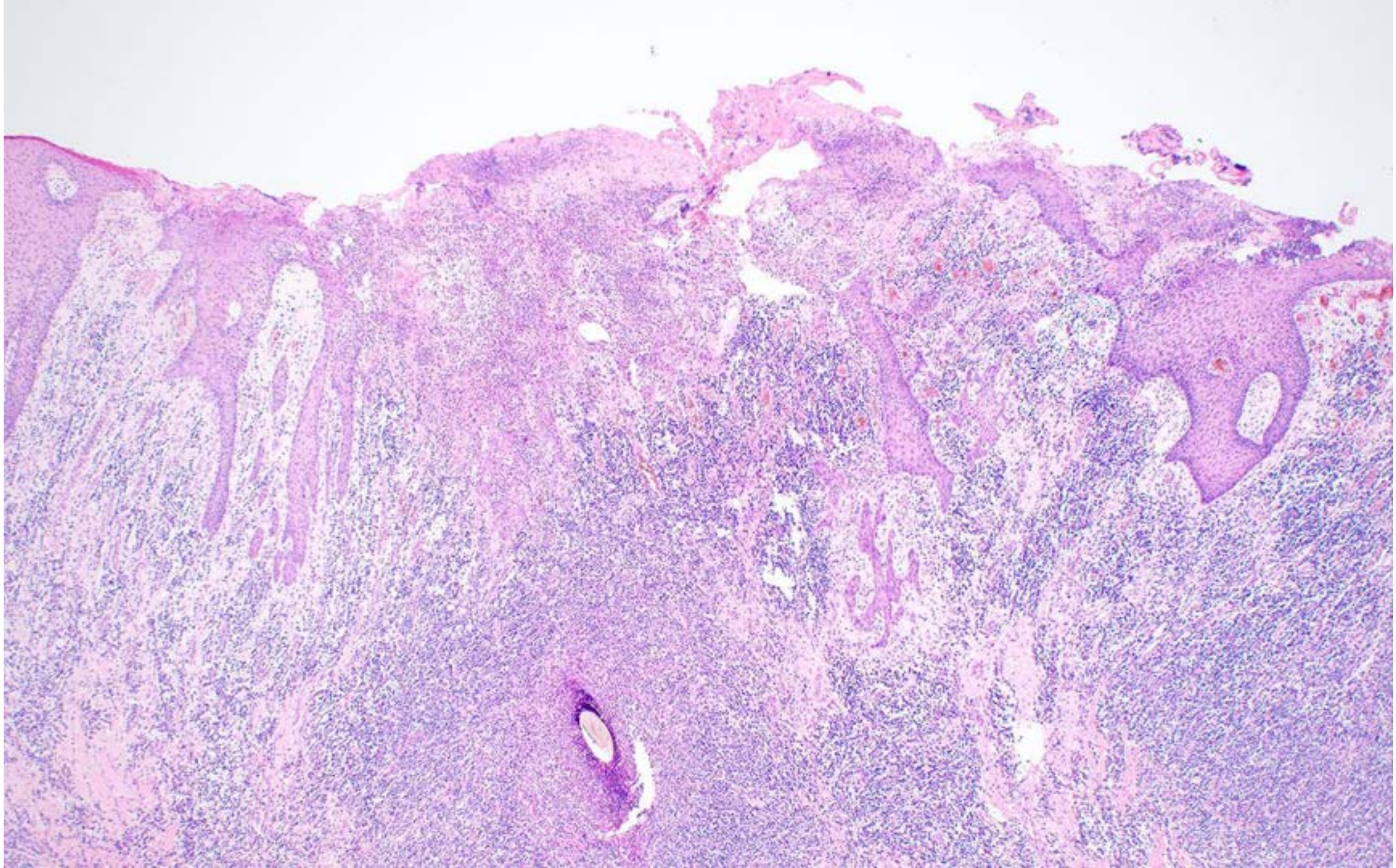

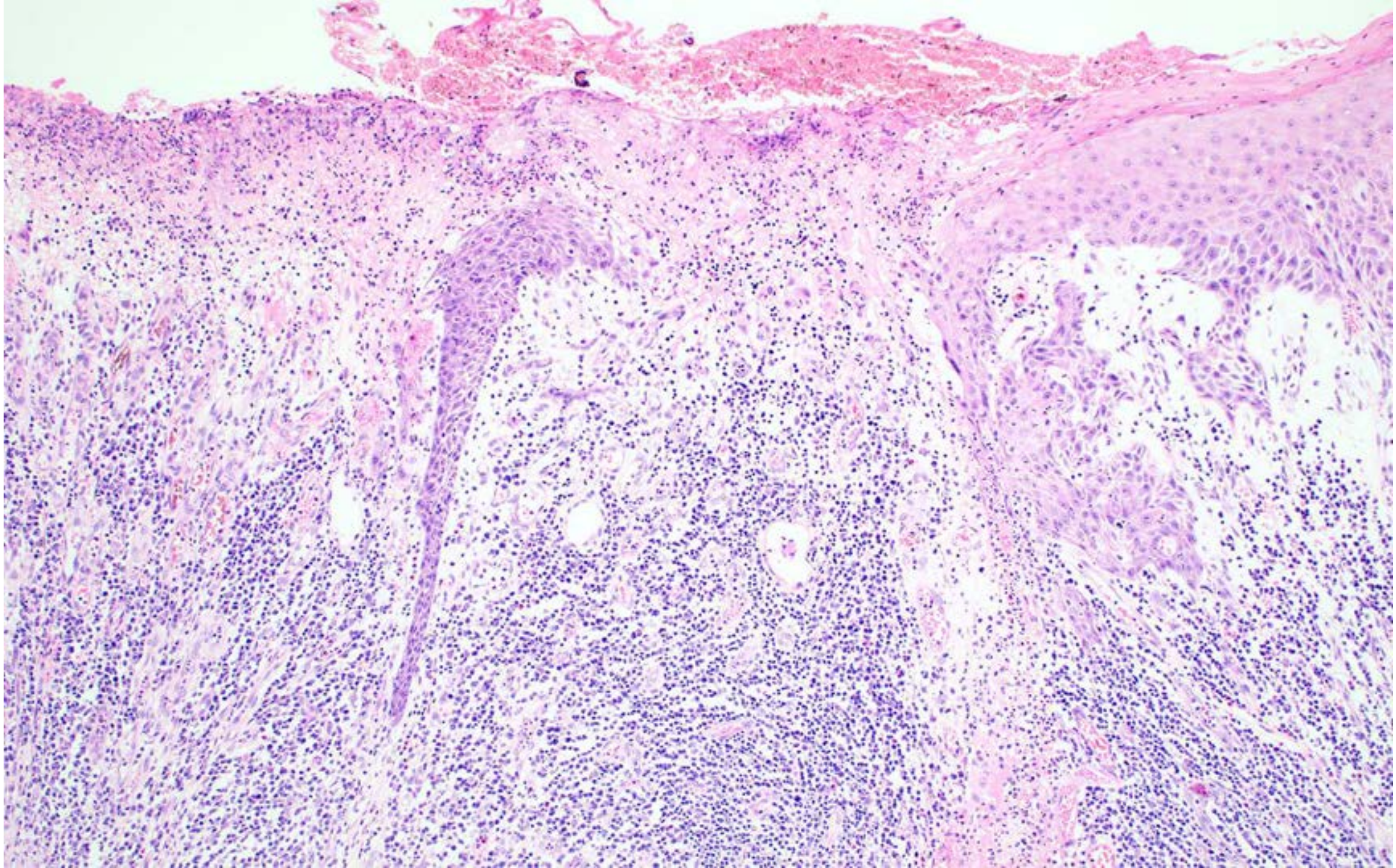

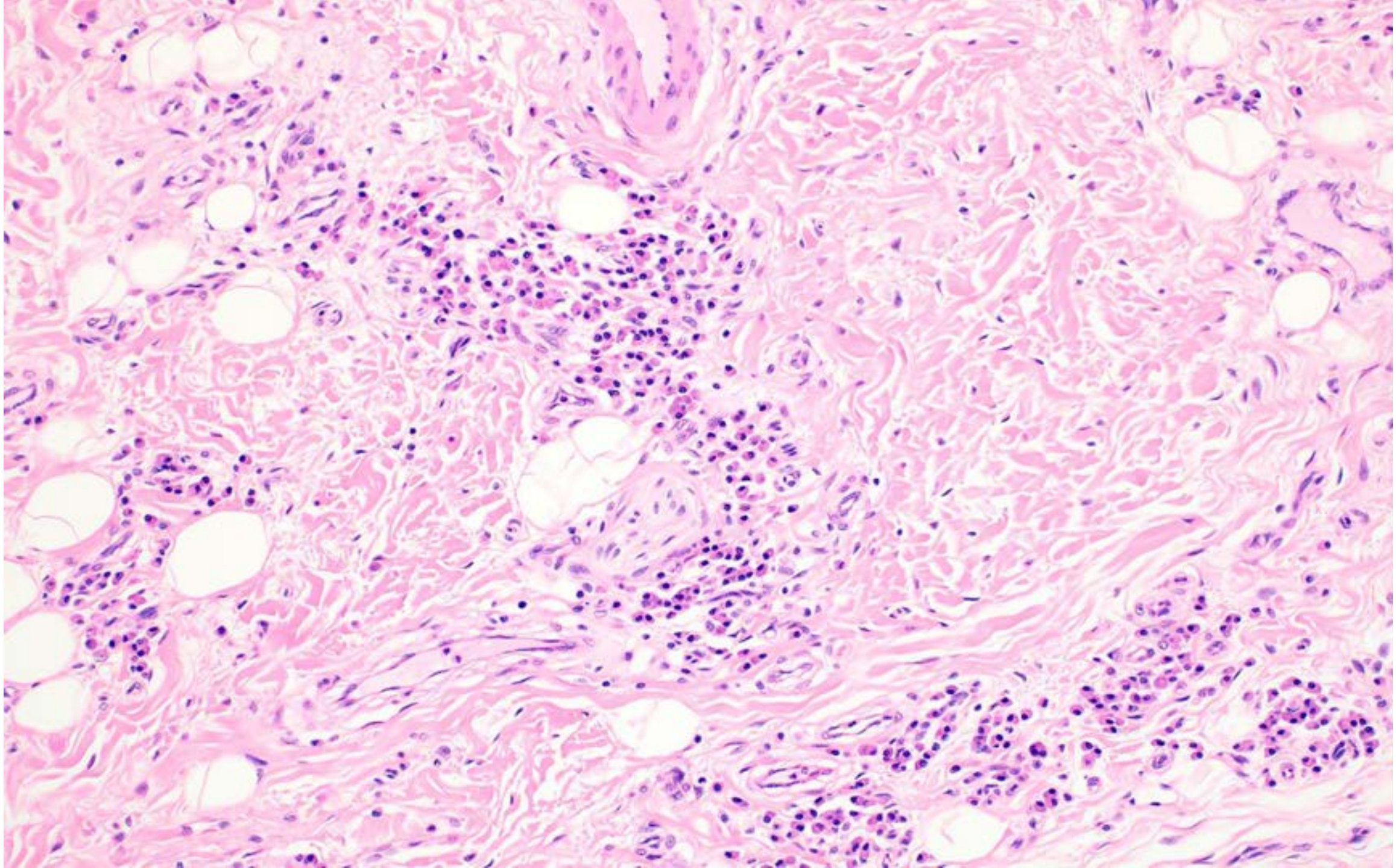

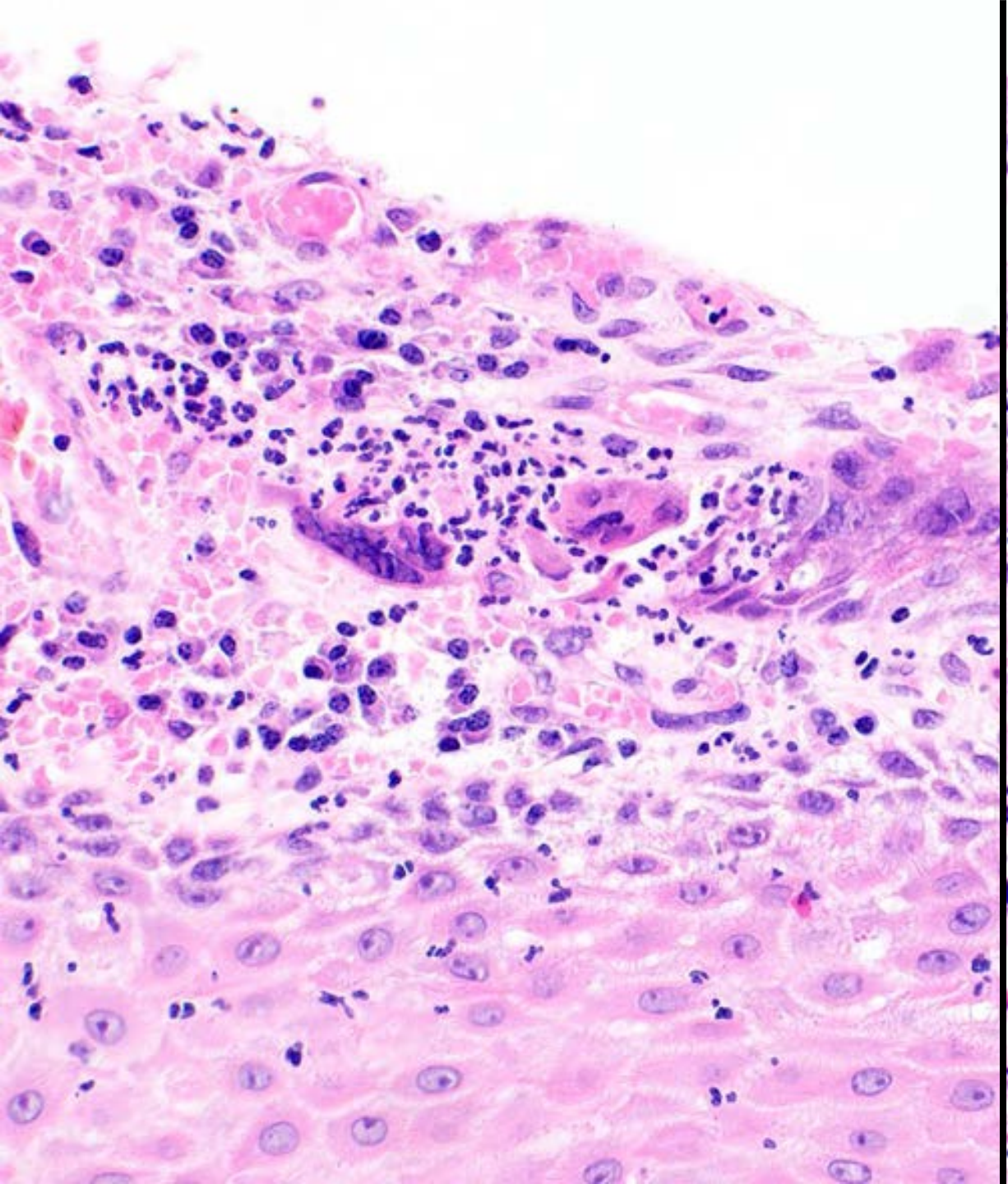

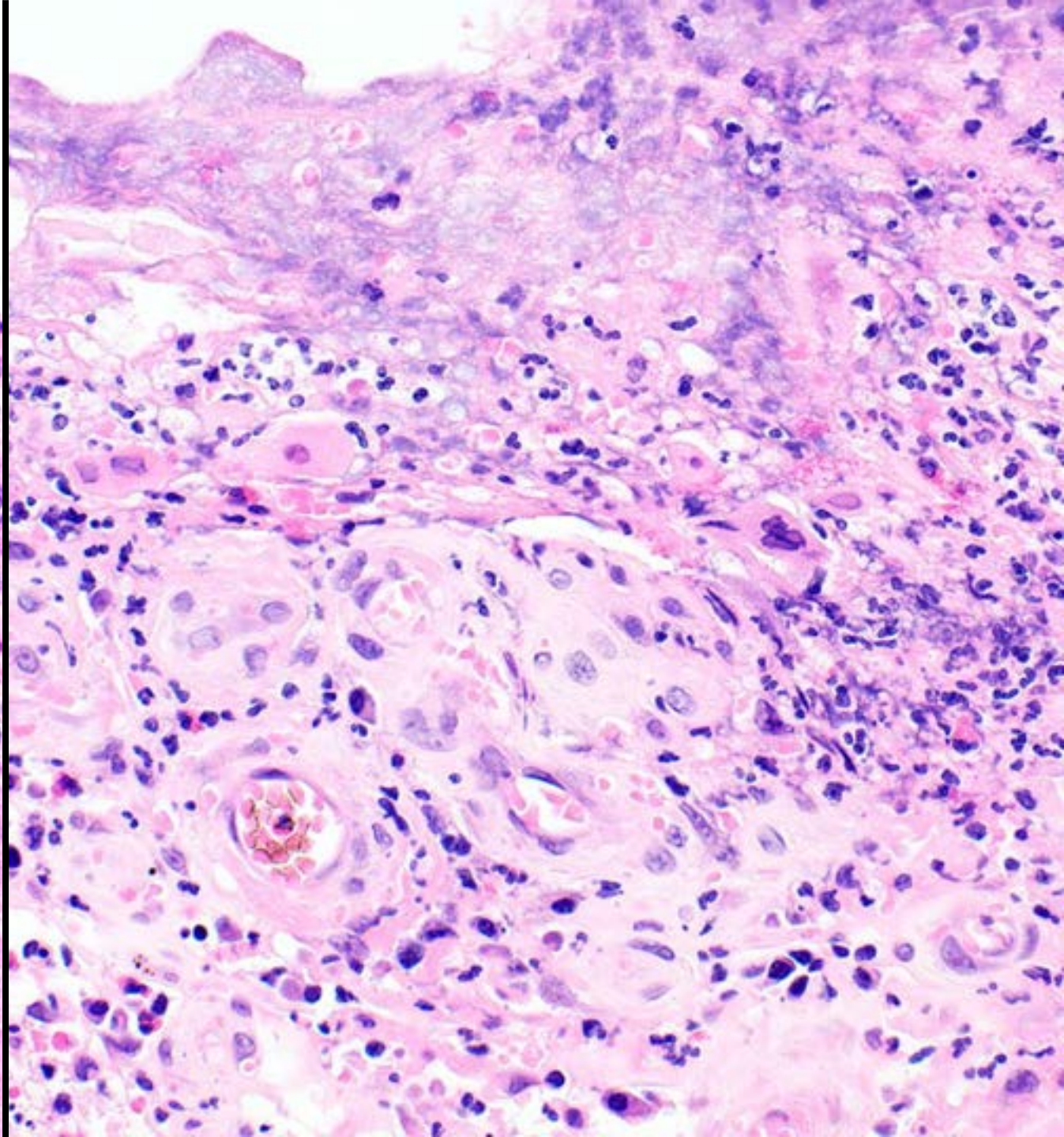

Herpes Simplex Virus (HSV)

- Morphology overlaps with HPVi VIN
  - Pseudoepitheliomatous hyperplasia may mimic invasion, especially in immunocompromised patients
  - May have lichenoid inflammation
  - May show cytologic atypia and mitotic activity

- Key differences from HPVi VIN
  - Acantholytic keratinocytes with multinucleation, nuclear molding, and chromatin margination
  - Marked intraepithelial acute inflammation
  - Marked dermal chronic inflammation including plasma cells
  - Positive HSV1/HSV2 stain

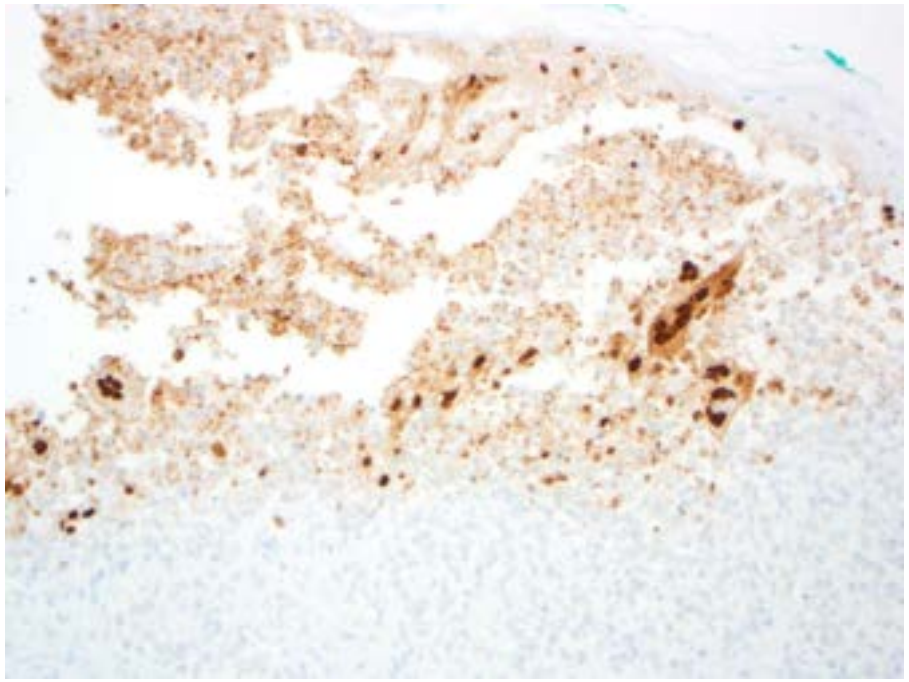

Photo courtesy of University of Michigan Immunohistochemistry Lab
https://www.pathology.med.umich.edu/immunohistochemistry/ihc-antibody-list

References

- WHO Classification of Tumours Editorial Board. WHO Classification of Tumours Series: Female Genital Tumours, Vol 4, 5th ed. International Agency for Research on Cancer; 2020.
- Heller DS, Day T, Allbritton JI, et al. Diagnostic Criteria for Differentiated Vulvar Intraepithelial Neoplasia and Vulvar Aberrant Maturation. J Low Genit Tract Dis 2021;25(1):57-70.
- McAlpine JN, Kim SY, Akbari A, et al. HPV-independent differentiated vulvar intraepithelial neoplasia (dVIN) is associated with an aggressive clinical course. Int J Gynecol Pathol 2017;36(6):507–516.
- Tessier-Cloutier B, Kortekaas KE, Thompson E, et al. Major p53 immunohistochemical patterns in in situ and invasive squamous cell carcinomas of the vulva and correlation with TP53 mutation status. Mod Pathol 2020;33(8):1595-1605.
- Yang B, Hart WR. Vulvar intraepithelial neoplasia of the simplex (differentiated) type: a clinicopathologic study including analysis of HPV and p53 expression. Am J Surg Pathol 2000;24(3):429–441.
- Day T, Marzol A, Pagano R, Jaaback K, Scurry J. Clinicopathologic Diagnosis of Differentiated Vulvar Intraepithelial Neoplasia and Vulvar Aberrant Maturation. J Low Genit Tract Dis 2020;24:392-398.
- Watkins JC, Howitt BE, Horowitz NS, et al. Differentiated exophytic vulvar intraepithelial lesions are genetically distinct from keratinizing squamous cell carcinomas and contain mutations in PIK3CA. Mod Pathol 2017;30:448-458.
- Akbari A, Pinto A, Amemiya Y, Seth A, Mirkovic J, Parra-Herran C. Differentiated exophytic vulvar intraepithelial lesion: clinicopathologic and molecular analysis documenting its relationship with verrucous carcinoma of the vulva. Mod Pathol 2020;33:2011-2018.
- Neville G, Chapel DB, Crum CP, et al. Interobserver reproducibility of differentiated exophytic vulvar intraepithelial lesion (DEVIL) and distinction from its mimics. Histopathol 2021;79:957-965.
- Nascimento AF, Granter SR, Cviko A, Yuan L, Hecht JL, Crum CP. Vulvar acanthosis with altered differentiation: a precursor to verrucous carcinoma? Am J Surg Pathol 2004;28(5):638-43.
- Roy SF, Wong J, Le Page C, et al. DEVIL, VAAD and vLSC constitute a spectrum of HPV-independent, p53-independent intraepithelial neoplasia of the vulva. Histopathol 2021;79:975-988.
- Parra-Herran C, Nucci MR, Singh N, et al. HPV-independent, p53-wild-type vulvar intraepithelial neoplasia: a review of nomenclature and the journey to characterize verruciform and acanthotic precursor lesions of the vulva. Mod Pathol. 2022 Oct;35(10):1317-1326.
- Bohl T, Day T, Heller D, et al. Comment on HPV-independent, p53-wild-type vulvar intraepithelial neoplasia: a review of nomenclature and the journey to characterize acanthotic precursor lesions of the vulva. Parra-Herran C. et al Mod Pathol 2022 Apr 18 doi: 10.1038/s41379-022-01079-7. Mod Pathol. 2022 Dec;35(12):2031-2032.
- Rakislova N, Alemany L,Clavero O, et al. Differentiated Vulvar Intraepithelial Neoplasia-like and Lichen Sclerosus-like Lesions in HPV-associated Squamous Cell Carcinomas of the Vulva. Am J Surg Pathol. 2018 Jun;42(6):828-835.
- Watkins JC, Yang E, Crum CP, et al. Classic Vulvar Intraepithelial Neoplasia With Superimposed Lichen Simplex Chronicus: A Unique Variant Mimicking Differentiated Vulvar Intraepithelial Neoplasia. Int J Gynecol Pathol. 2019 Mar;38(2):175-182.
- Griesinger LM, Walline H, Wang GY, et al. Expanding the Morphologic, Immunohistochemical, and HPV Genotypic Features of High-grade Squamous Intraepithelial Lesions of the Vulva With Morphology Mimicking Differentiated Vulvar Intraepithelial Neoplasia and/or Lichen Sclerosus. Int J Gynecol Pathol. 2021 May 1;40(3):205-213.
- Domfeh AB, Silasi D-A, Lindo F, Parkash V. Chronic hypertrophic vulvar herpes simulating neoplasia. Int J Gynecol Pathol. 2012 Jan;31(1):33-7.
- McKean R, Wolf J, Wong TT, Yin YM, Kanis MJ. Recurrent herpes simplex virus mimicking vulvar carcinoma in patient with Human Immunodeficiency Virus: A case report. Gynecol Oncol Rep. 2023 Jan 24;45:101142.
- ExpertPath

Questions?

sskala@med.umich.edu

THANK YOU!