

# DECEPTIVE MIMICS OF HPV-ASSOCIATED ENDOCERVICAL ADENOCARCINOMA IN SITU

**Dr Karen Talia**

Royal Children's Hospital & Royal Women's Hospital  
Australian Centre for the Prevention of Cervical Cancer



Australian Centre  
for the Prevention of  
Cervical Cancer



VCS Pathology



Population Health



Digital Health



C4  
Centre of Research  
Excellence in  
Cervical Cancer




compass  
Clinical Research  
Program



ROSE  
Research on  
Ovarian and  
Endometrial  
Stigma

Australian Centre for the Prevention of Cervical Cancer acknowledges the people and the Elders of the Aboriginal and Torres Strait Islander Nations who are the Traditional Owners of the land and seas of Australia.



# Important Information Regarding CME

The **CME/evaluation** process will only be available on the USCAP website until **September 30, 2023**.

**No claims can be processed after that date!**

After **September 30, 2023** you will NOT be able to obtain any CME credits for attending this meeting.



# Disclosure of Relevant Financial Relationships

The faculty, committee members, and staff who are in position to control the content of this activity are required to disclose to USCAP and to learners any financial relationships that have occurred within the last 24 months with ineligible companies whose primary business is producing, marketing, selling, re-selling, or distributing healthcare products used by or on patients. USCAP has reviewed the disclosures and mitigated all relevant financial relationships.

**The following faculty reported no relevant financial relationships:** Karen Talia

USCAP staff associated with the development of content for this activity reported no relevant financial relationships.

# Overview

HPVA AIS

## Morphology and IHC

Mimics

### Easy

Reactive change  
Microglandular hyperplasia  
Radiation atypia  
Arias-Stella  
Mesonephric hyperplasia  
Tunnel clusters

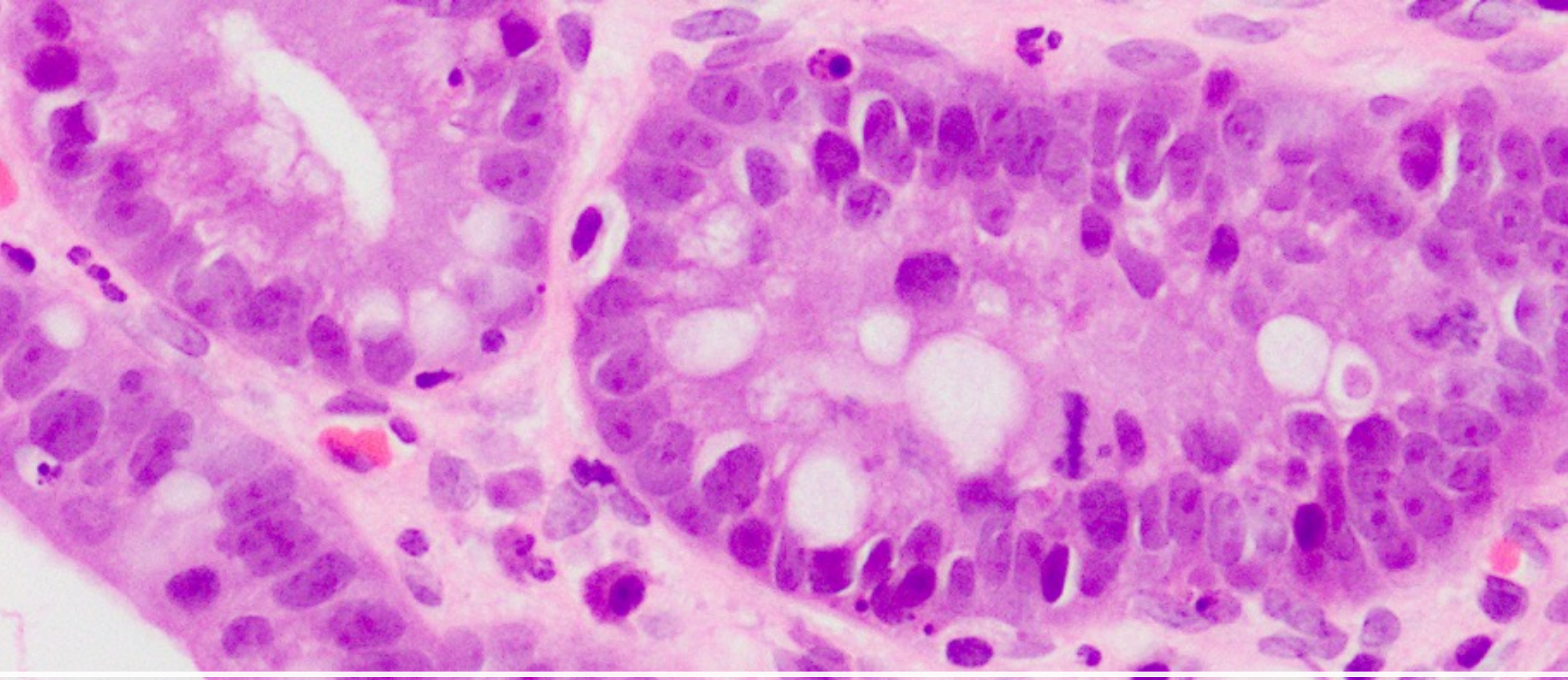
### Hard

Tubo-endometrioid metaplasia  
Endometriosis  
Endometrioid adenocarcinoma  
Serous carcinoma  
HPVI AIS, gastric type  
Metastases

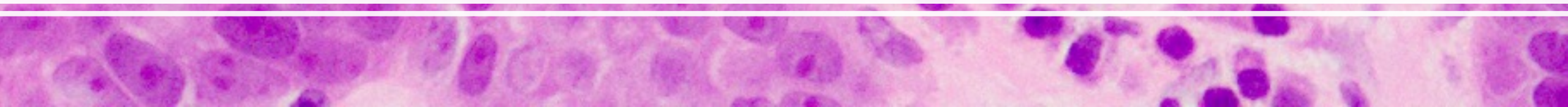
### Impossible!

Silva Pattern A adenocarcinoma





**HPV-associated adenocarcinoma in situ (AIS)**



# Terminology and classification

## Pre-2000s

### AIS

- Usual/Endocervical
- Endometrioid
- Intestinal
- Tubal

### EGD

*Cancer* 1953;6:887-97  
*Cancer* 1988;61:1171-81  
*IJGP* 1999;18:1-4

## WHO 2003,2014

### AIS

- Usual/endocervical
- Endometrioid
- Intestinal
- Tubal

### SMILE added 2014

### LGCGIN/EGD

*AJSP* 2000;24:1414-1419

## WHO 5<sup>th</sup> Edition

### HPVA AIS

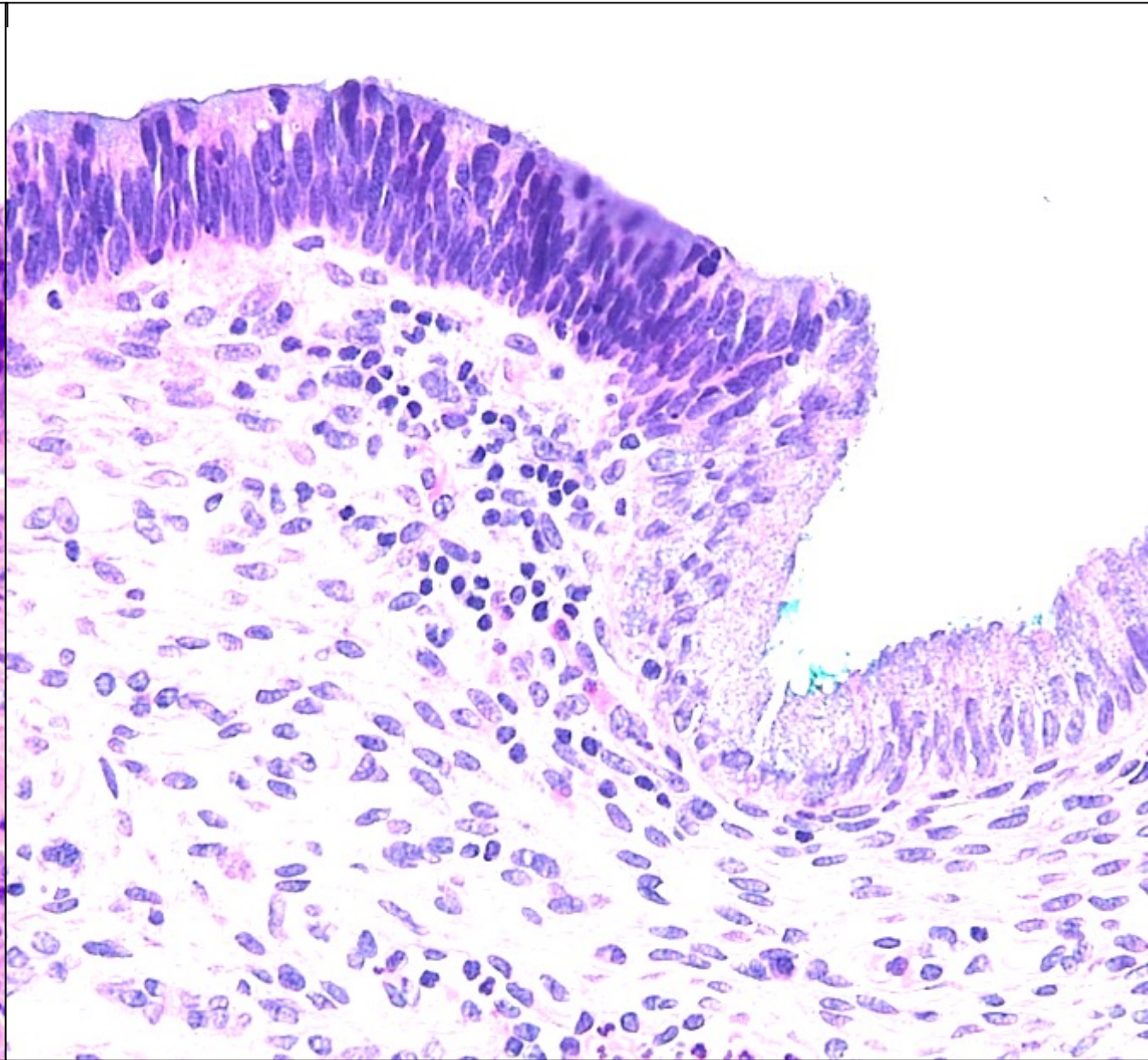
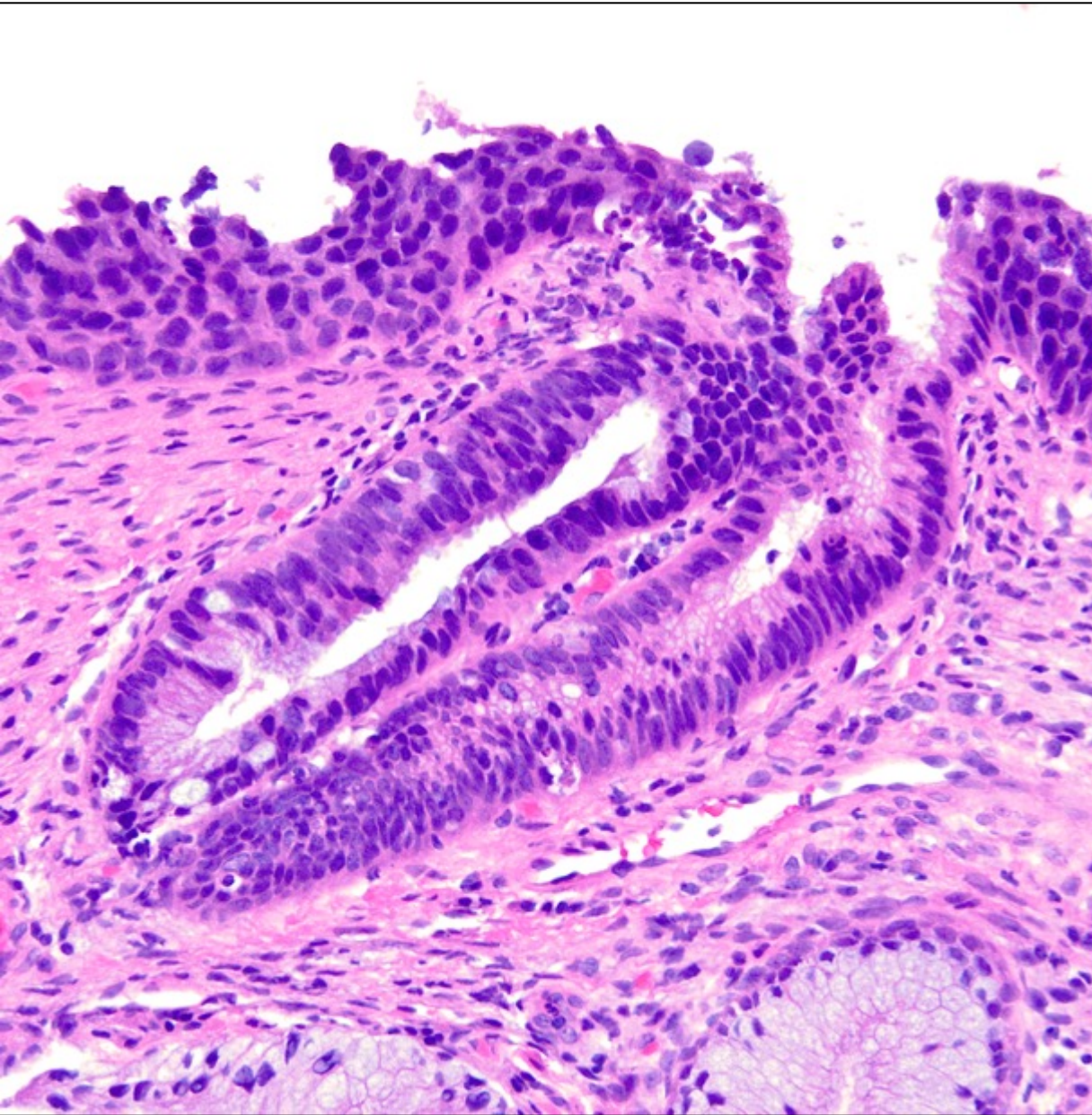
- Usual type
- SMILE

### HPVI AIS

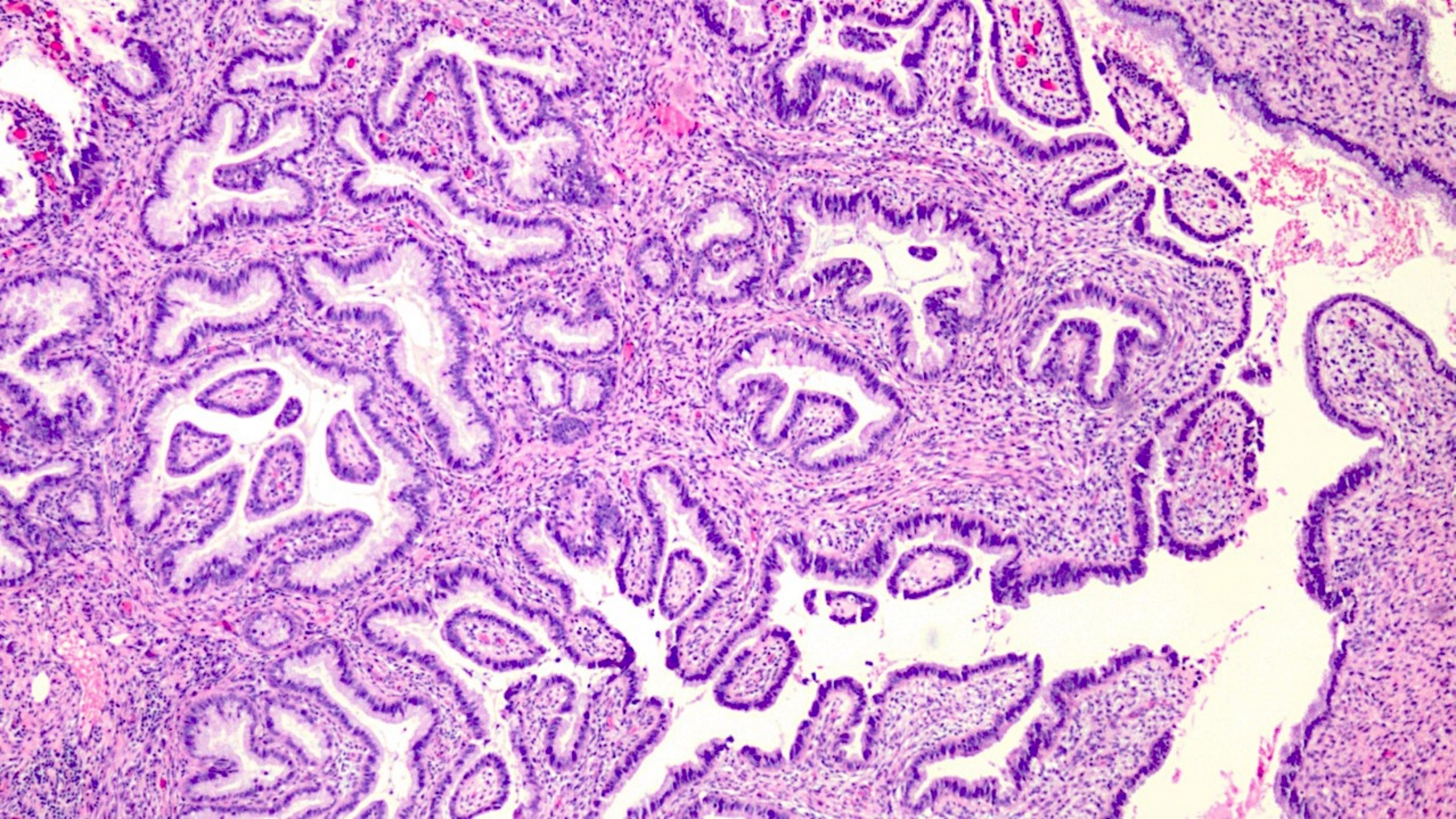
- Gastric-type
- Atypical LEGH

*AJSP* 2018;42:214-26  
*Histopathology* 2020;76:112-7

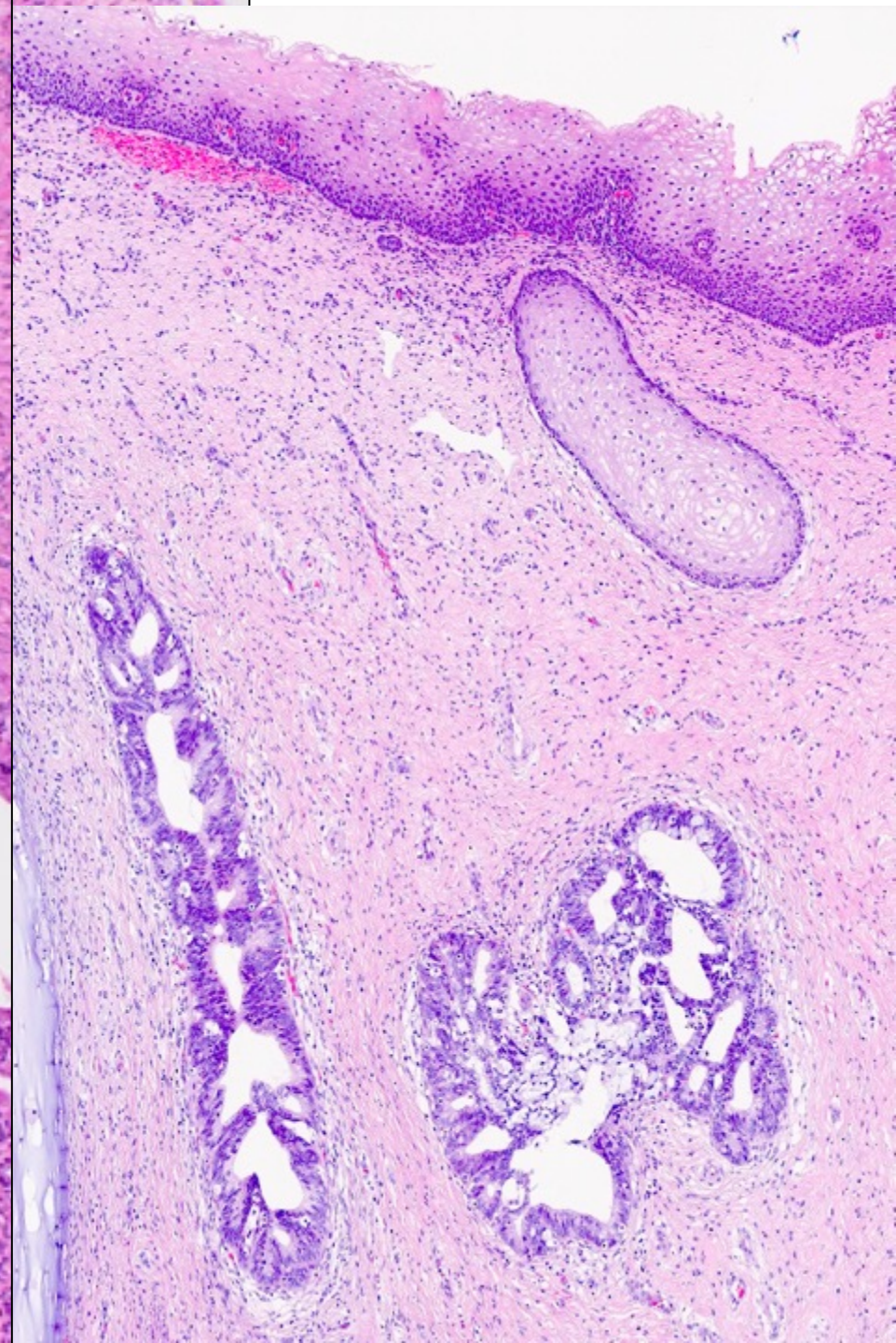
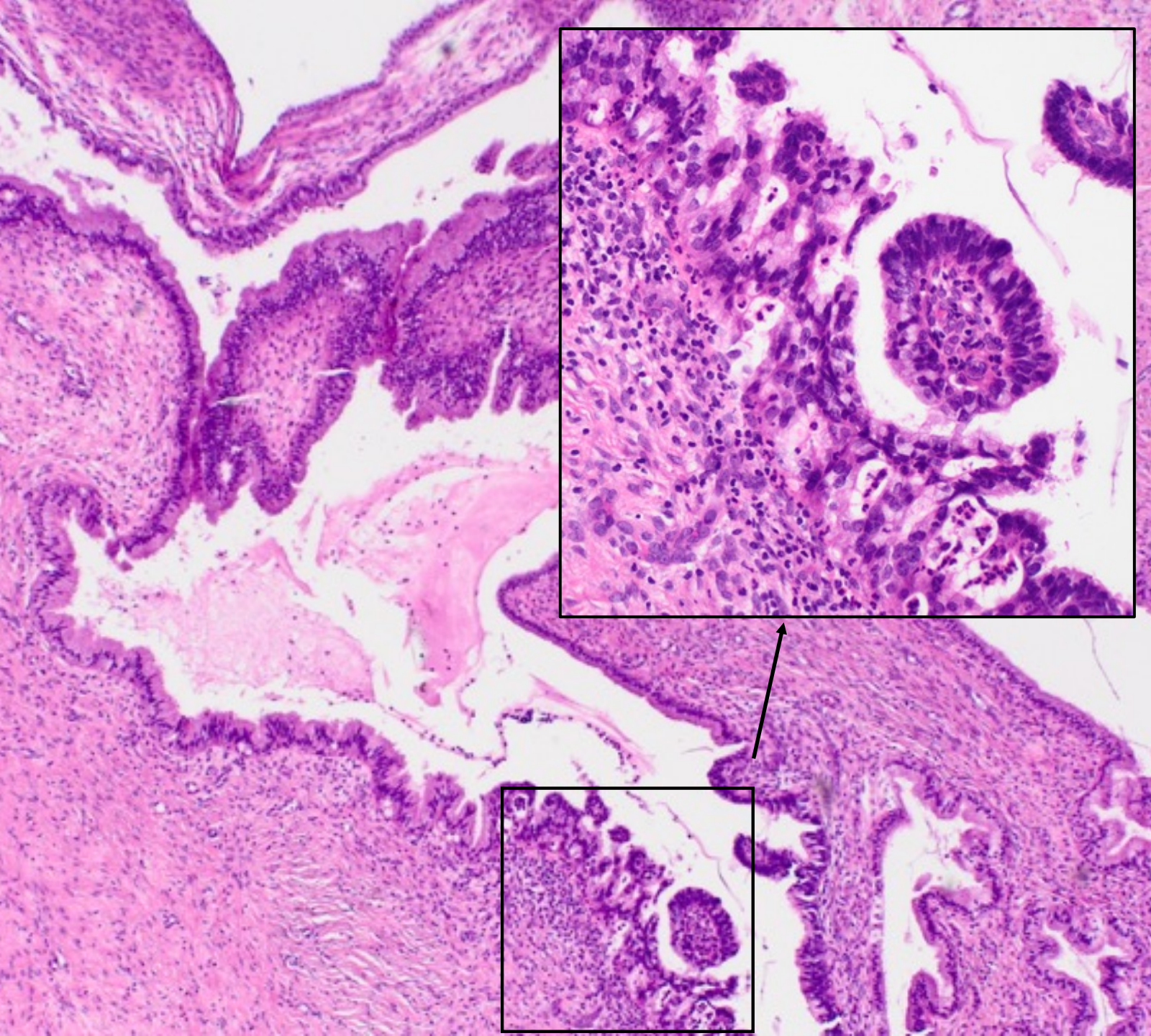




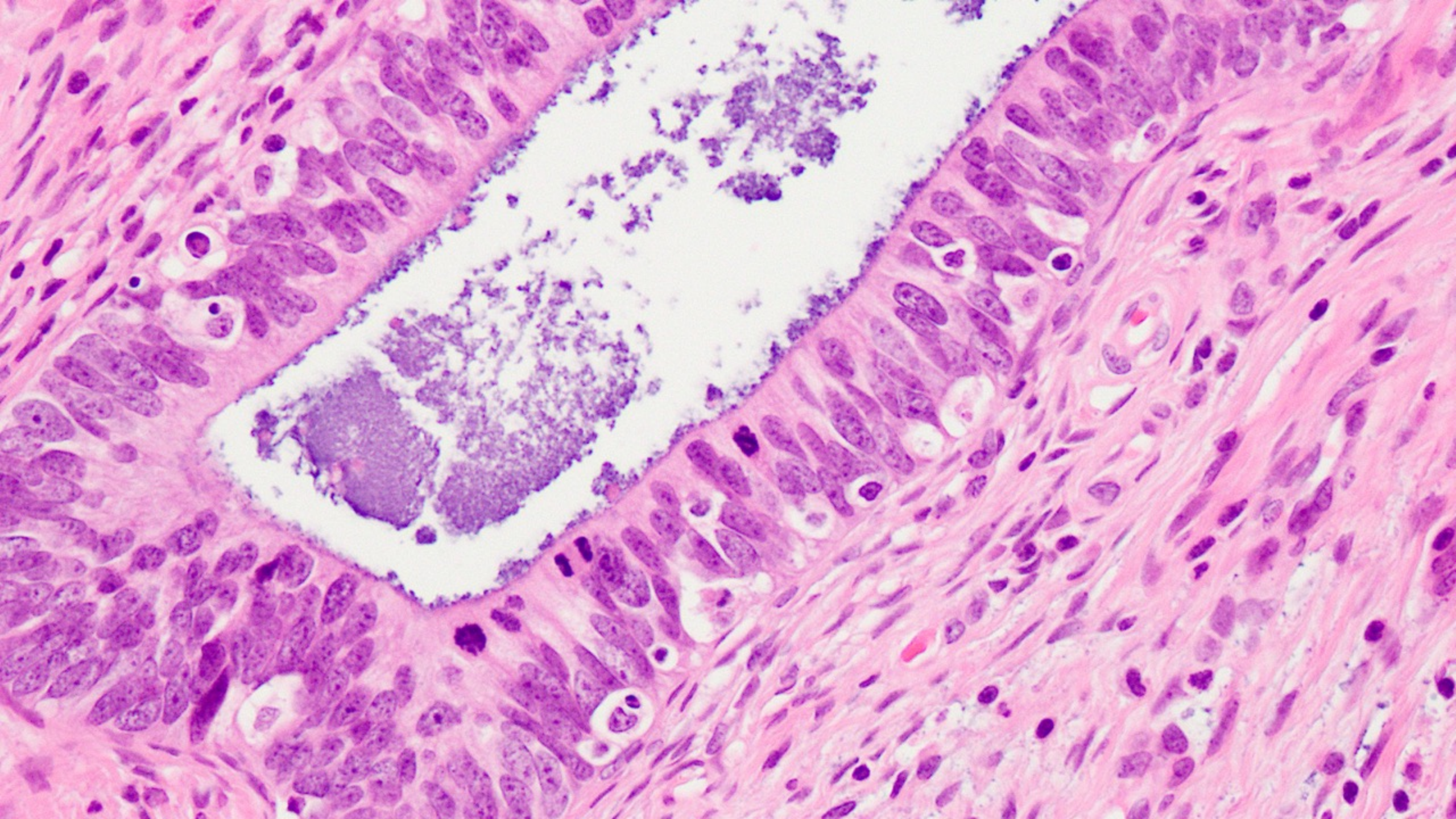




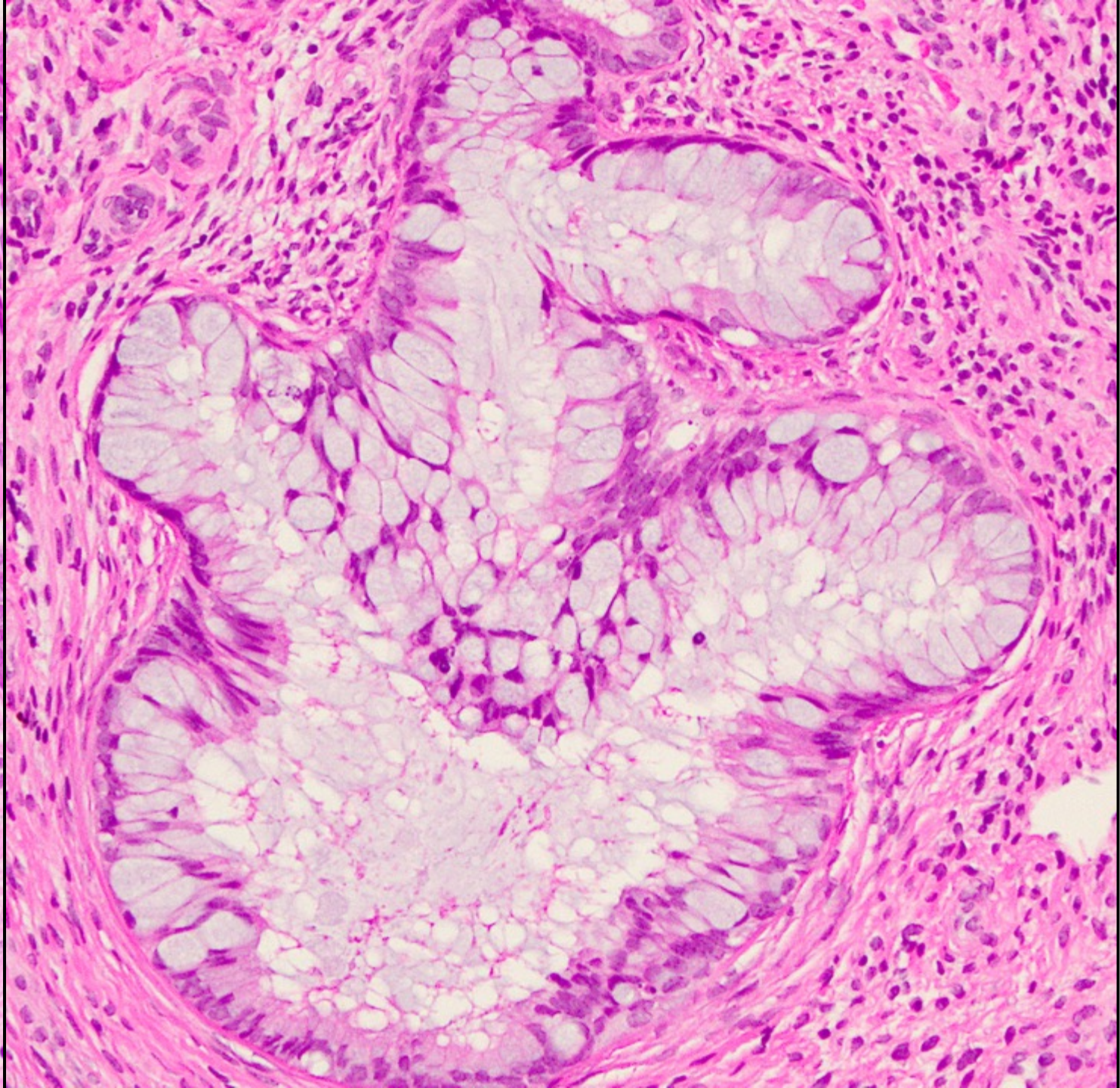
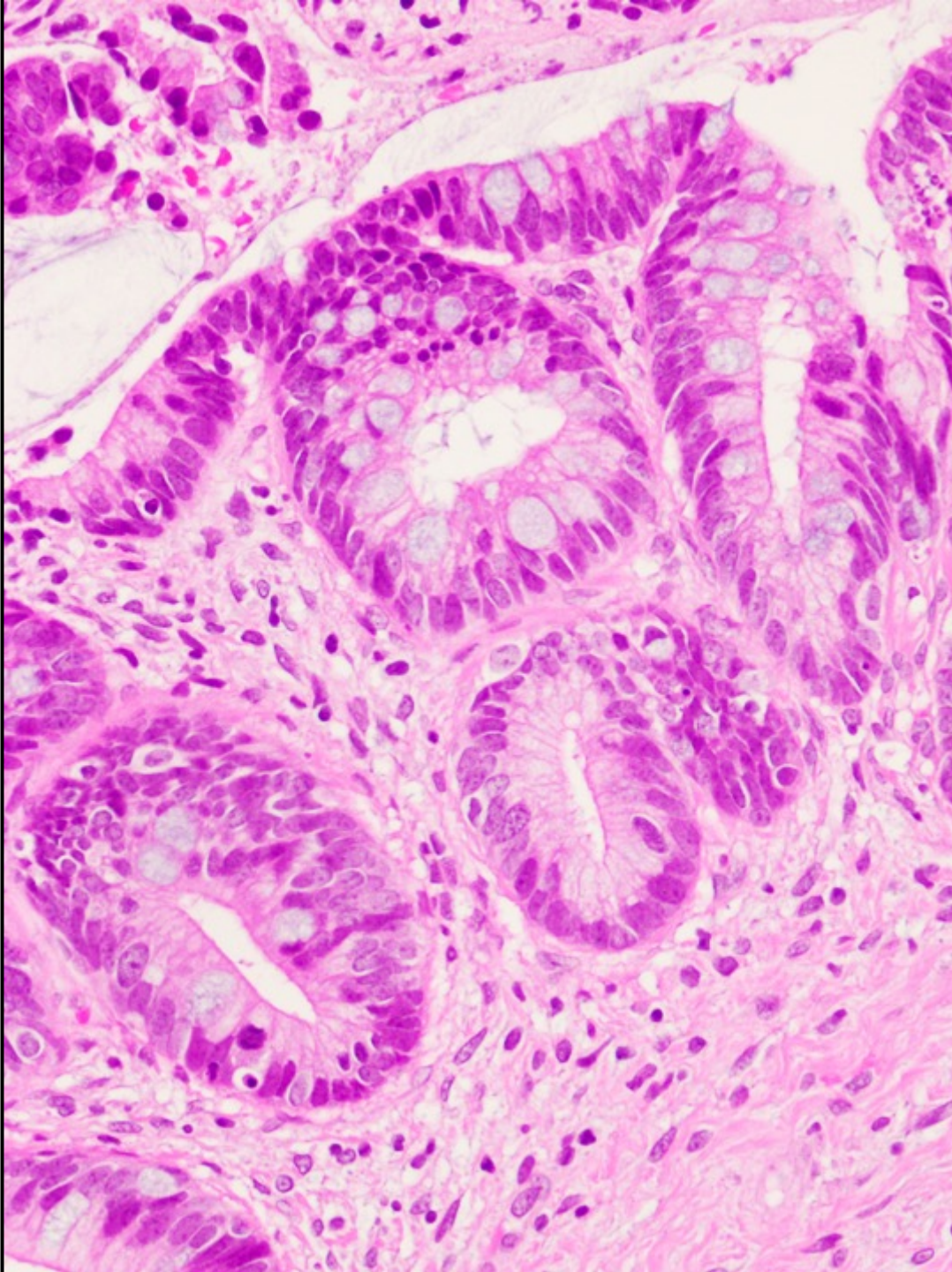




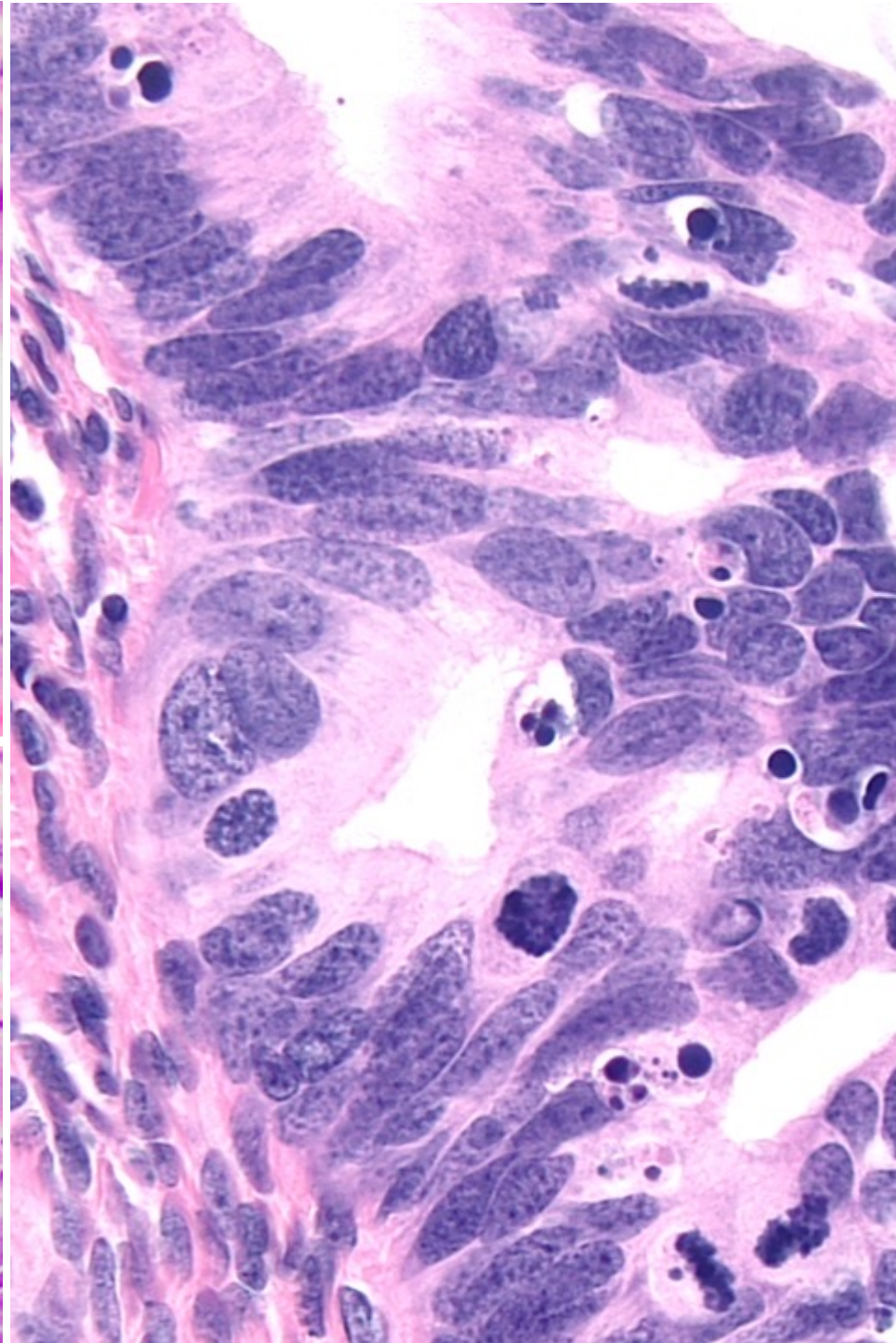
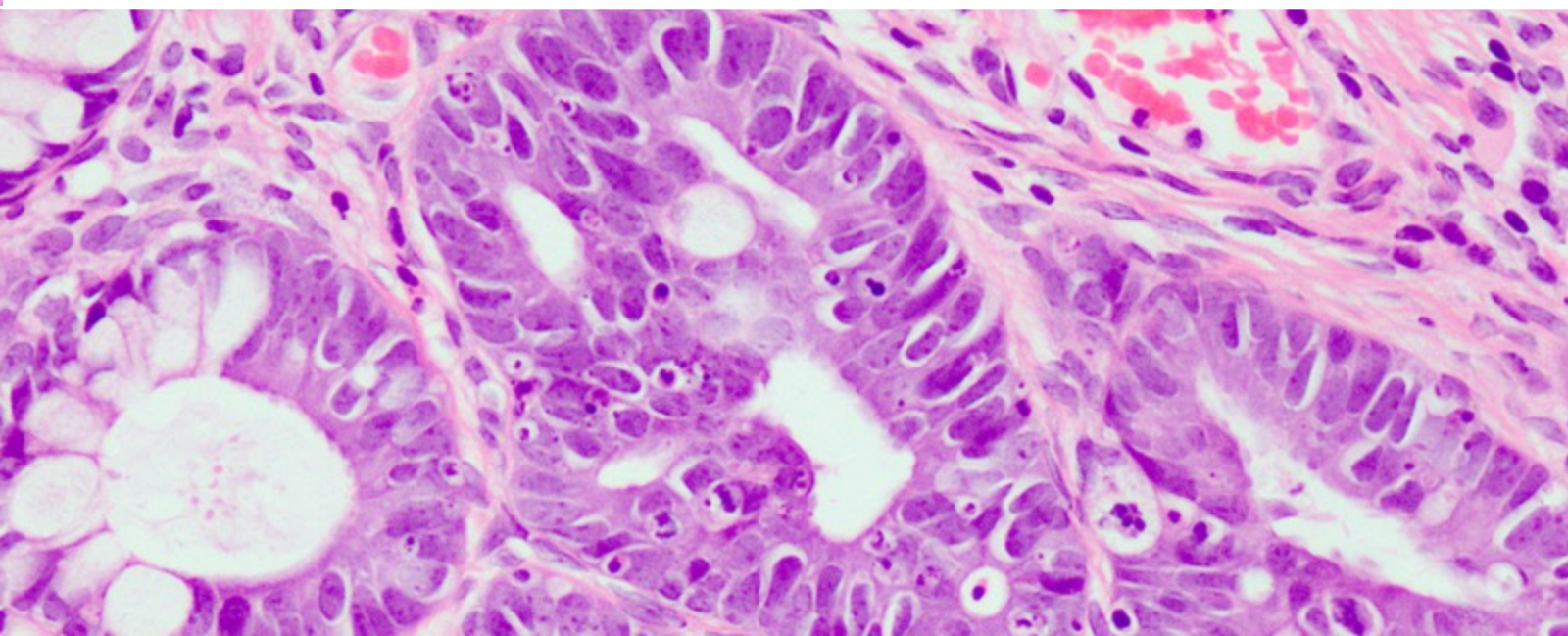
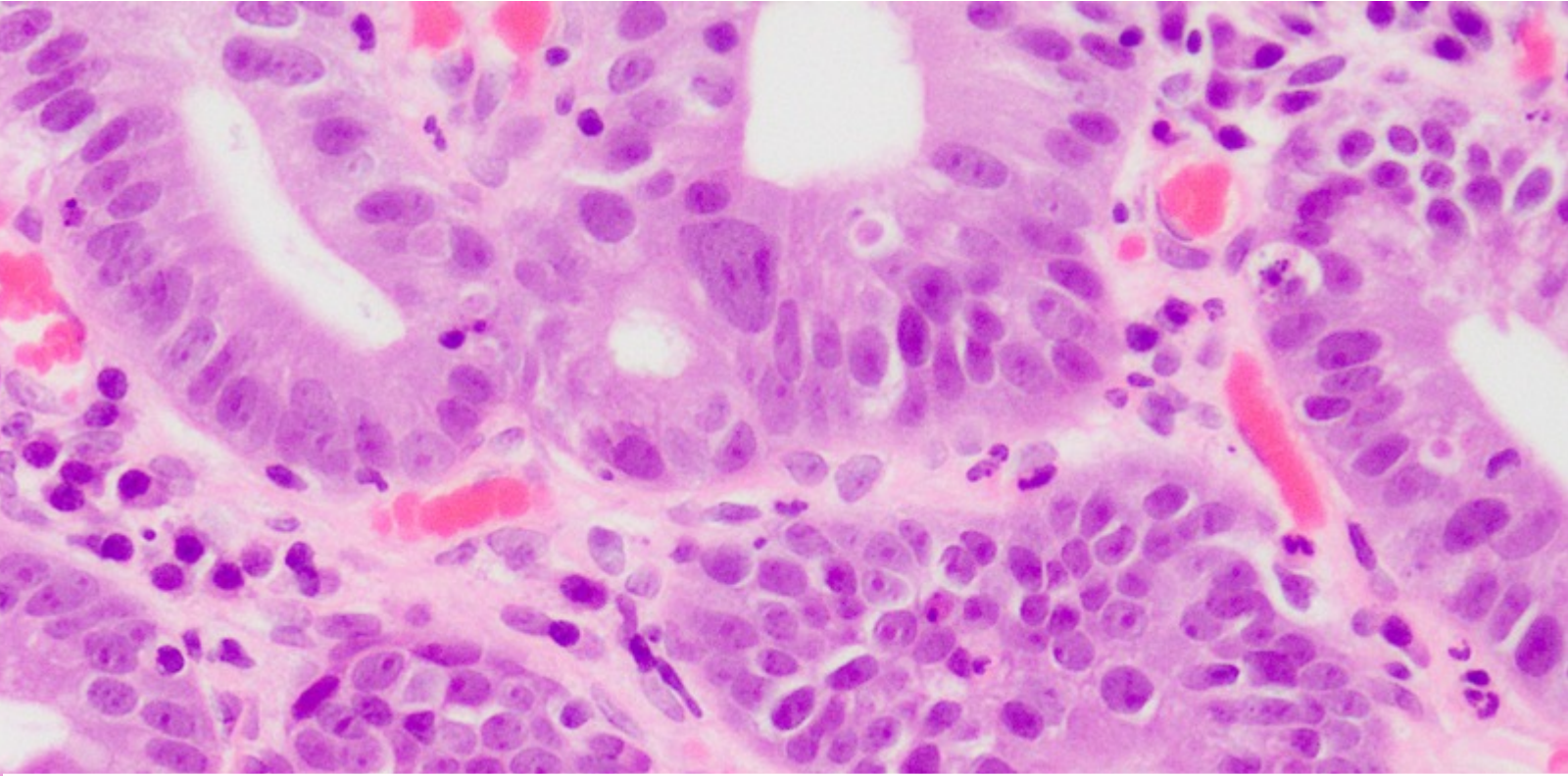




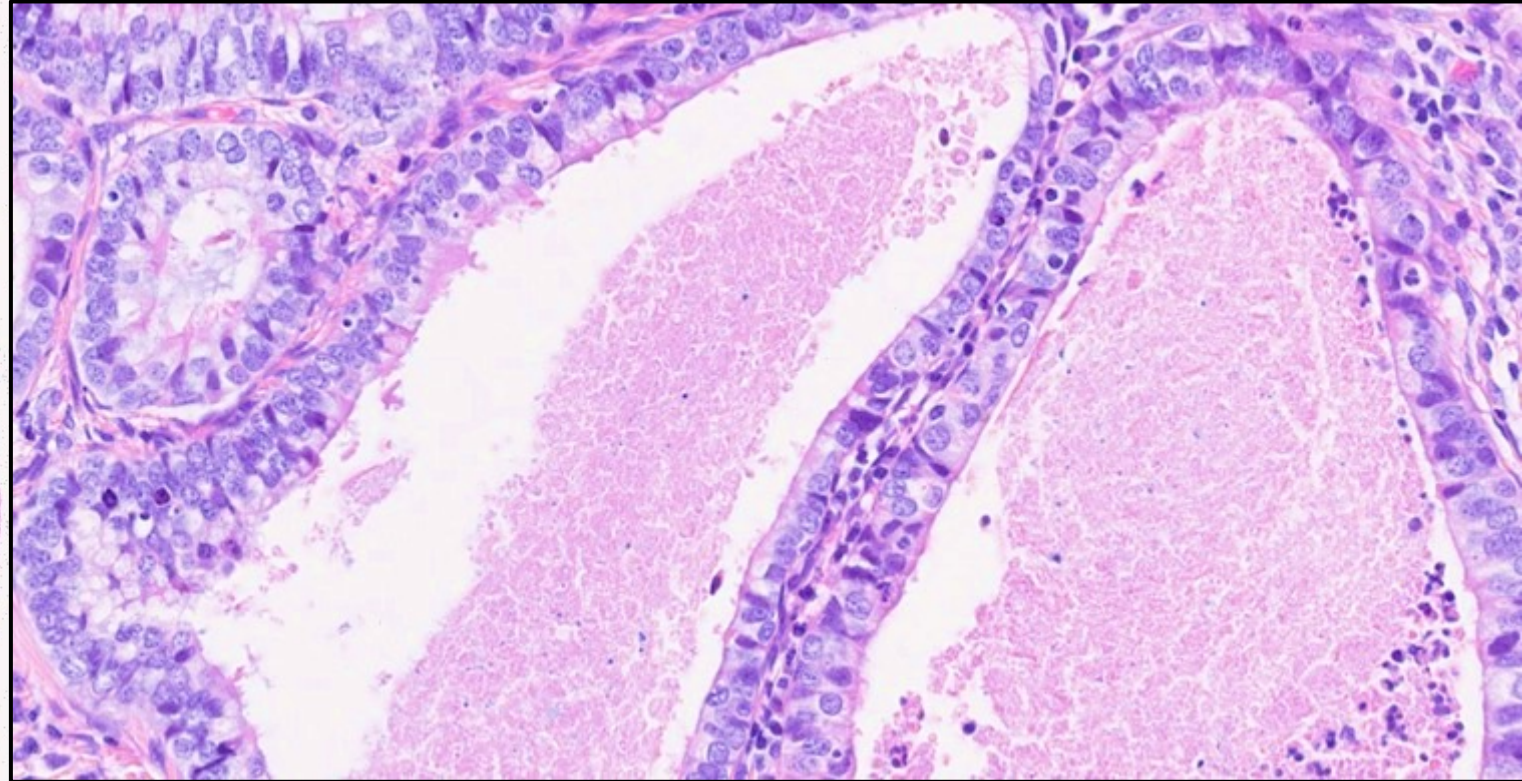
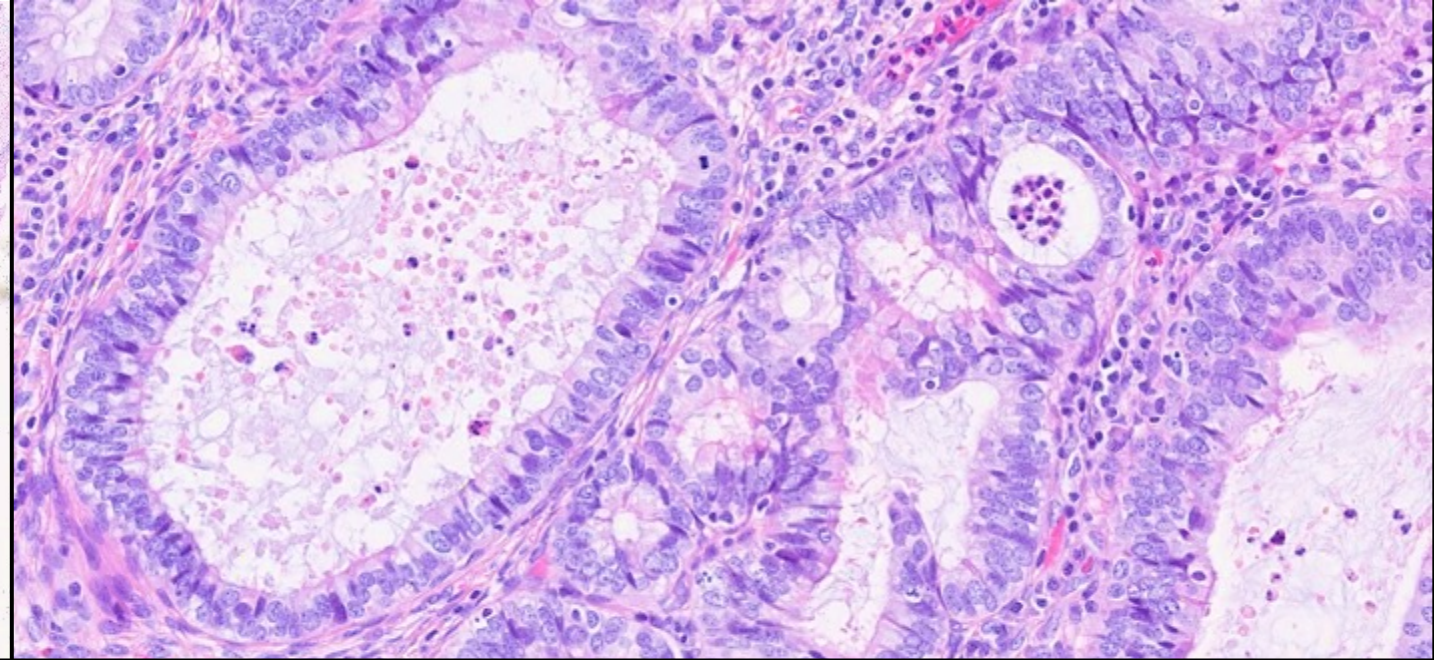
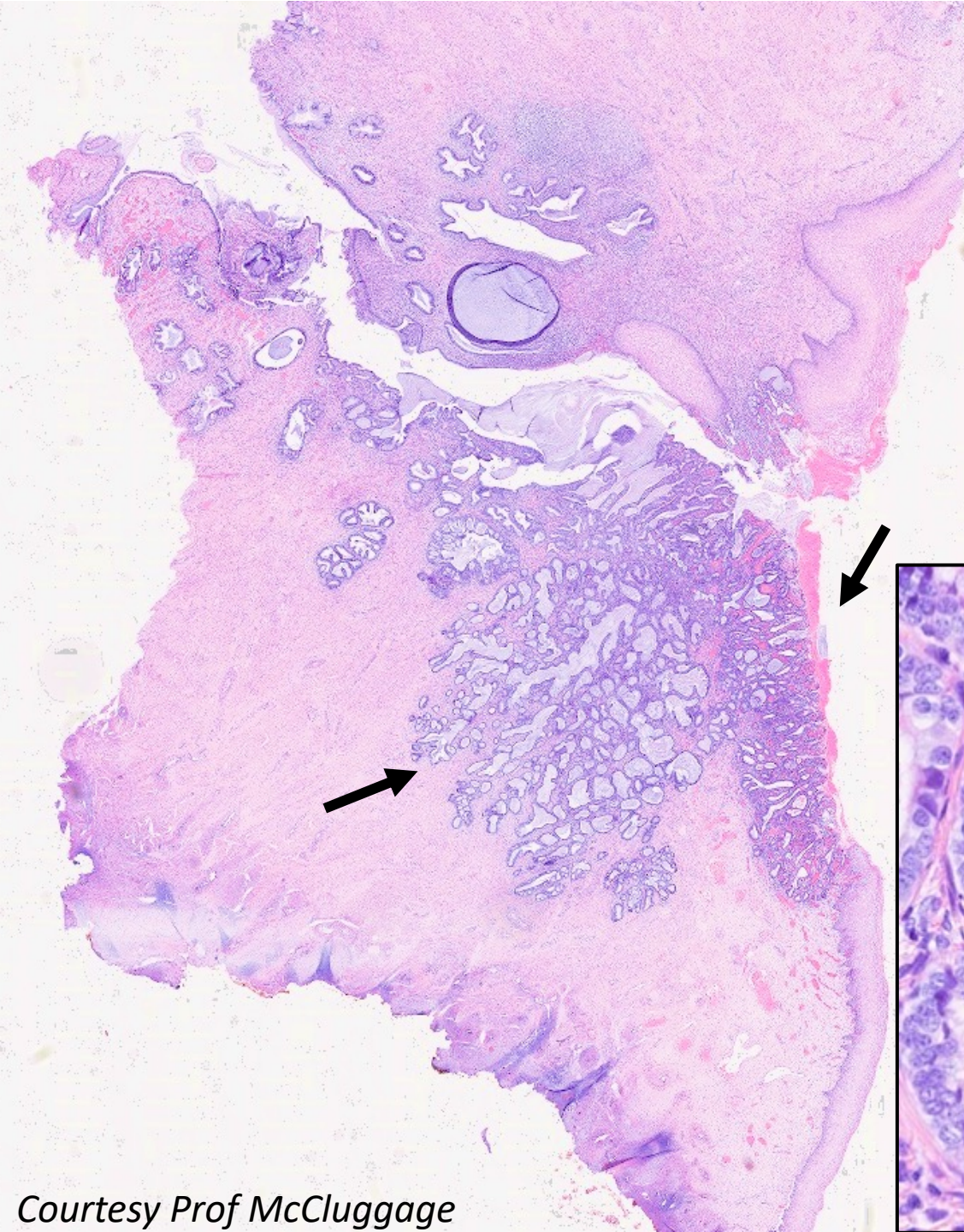




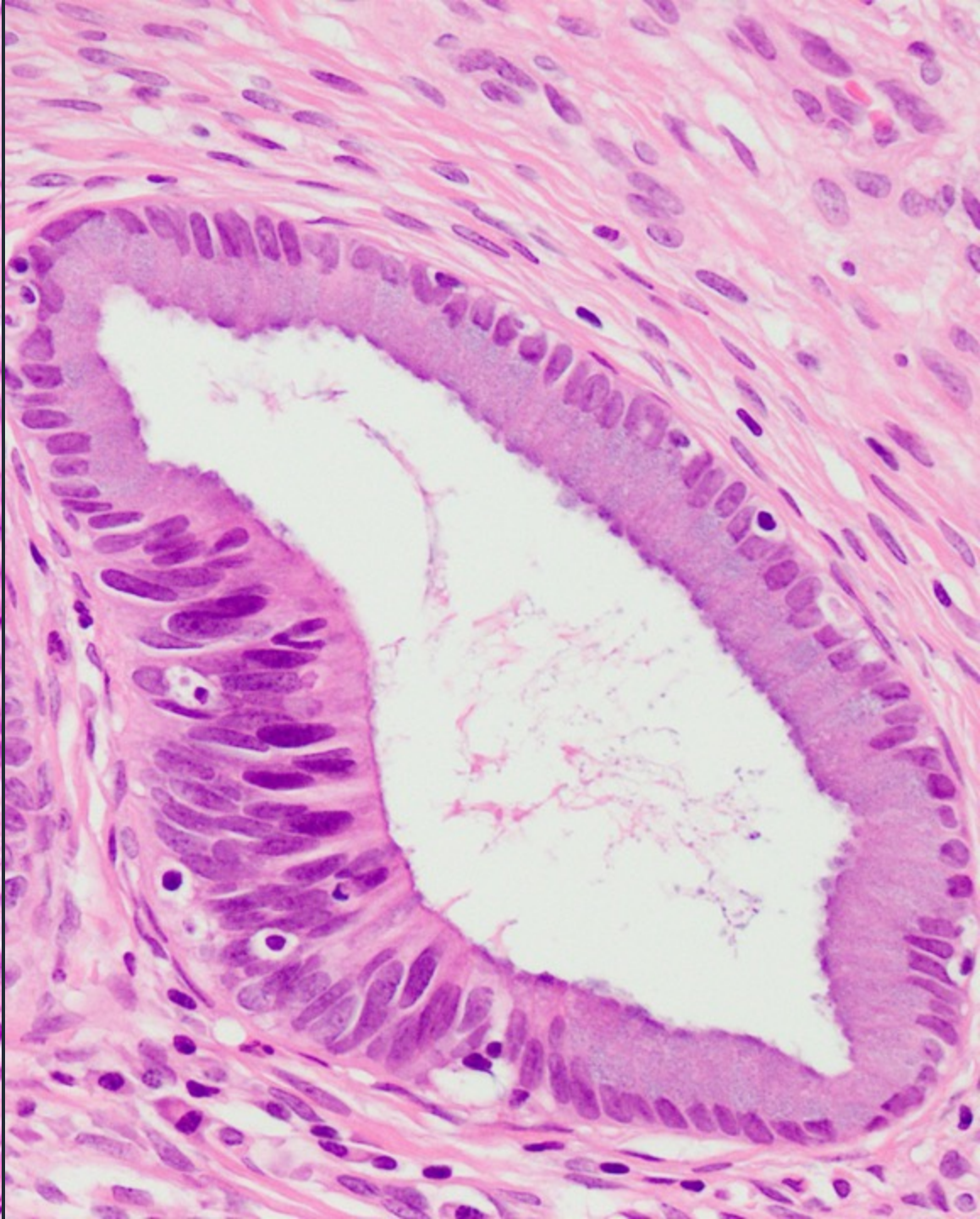
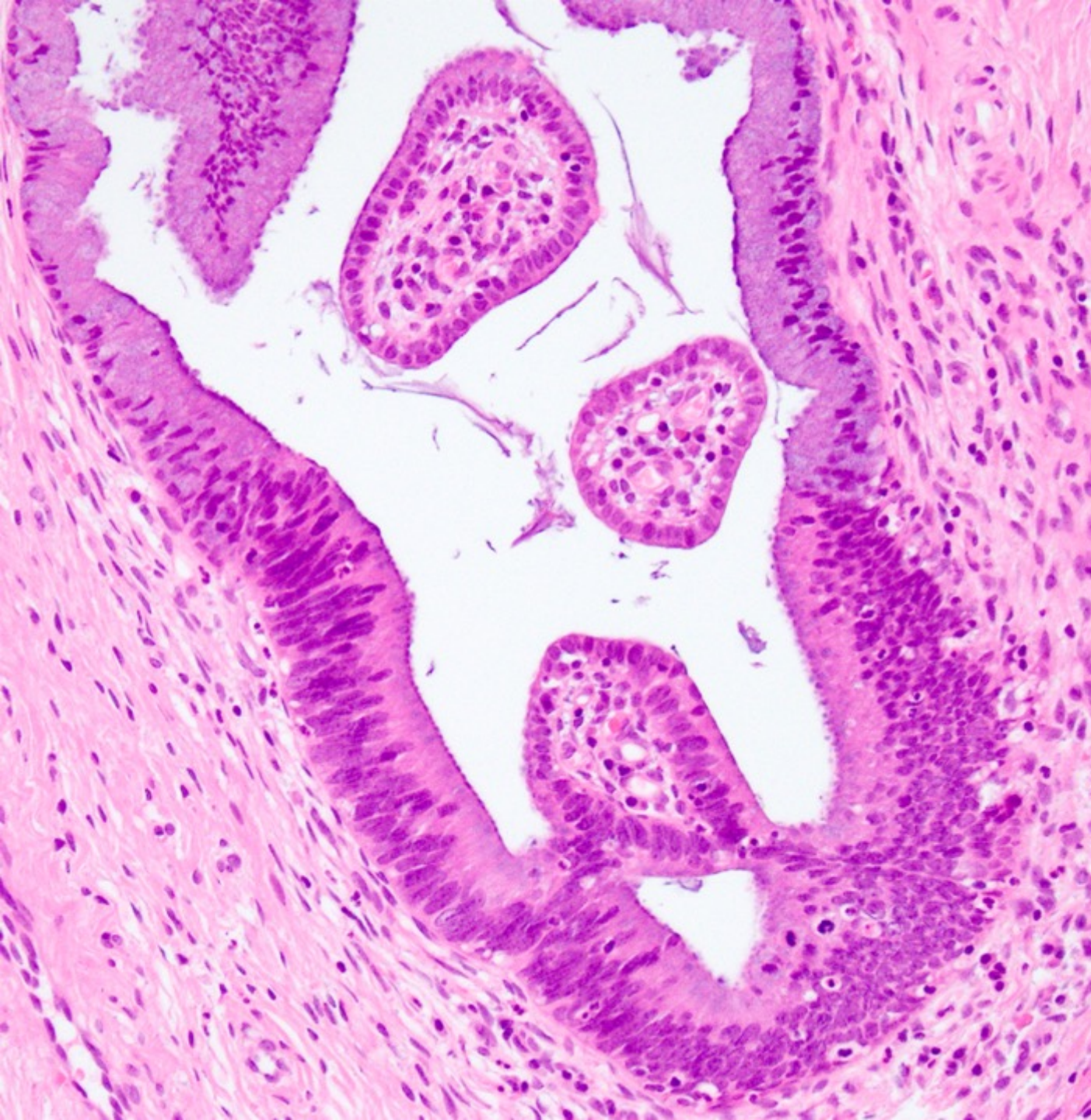




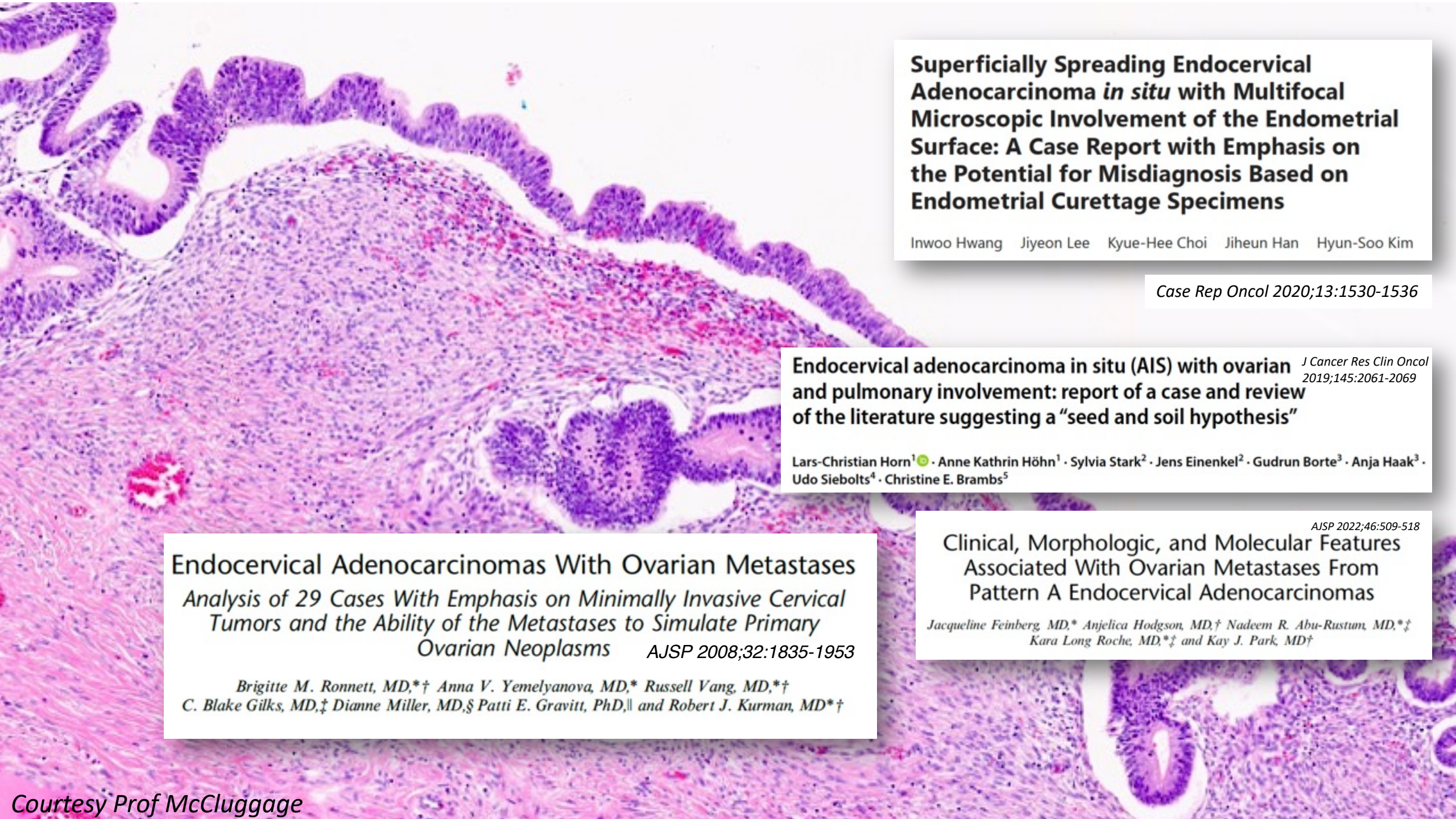












**Superficially Spreading Endocervical Adenocarcinoma *in situ* with Multifocal Microscopic Involvement of the Endometrial Surface: A Case Report with Emphasis on the Potential for Misdiagnosis Based on Endometrial Curettage Specimens**

Inwoo Hwang · Jiyeon Lee · Kyue-Hee Choi · Jiheun Han · Hyun-Soo Kim

*Case Rep Oncol* 2020;13:1530-1536

**Endocervical adenocarcinoma in situ (AIS) with ovarian and pulmonary involvement: report of a case and review of the literature suggesting a "seed and soil hypothesis"**

*J Cancer Res Clin Oncol* 2019;145:2061-2069

Lars-Christian Horn<sup>1</sup> · Anne Kathrin Höhn<sup>1</sup> · Sylvia Stark<sup>2</sup> · Jens Eienenkel<sup>2</sup> · Gudrun Borte<sup>3</sup> · Anja Haak<sup>3</sup> · Udo Siebolts<sup>4</sup> · Christine E. Brambs<sup>5</sup>

**Endocervical Adenocarcinomas With Ovarian Metastases**

*Analysis of 29 Cases With Emphasis on Minimally Invasive Cervical Tumors and the Ability of the Metastases to Simulate Primary Ovarian Neoplasms* *AJSP* 2008;32:1835-1953

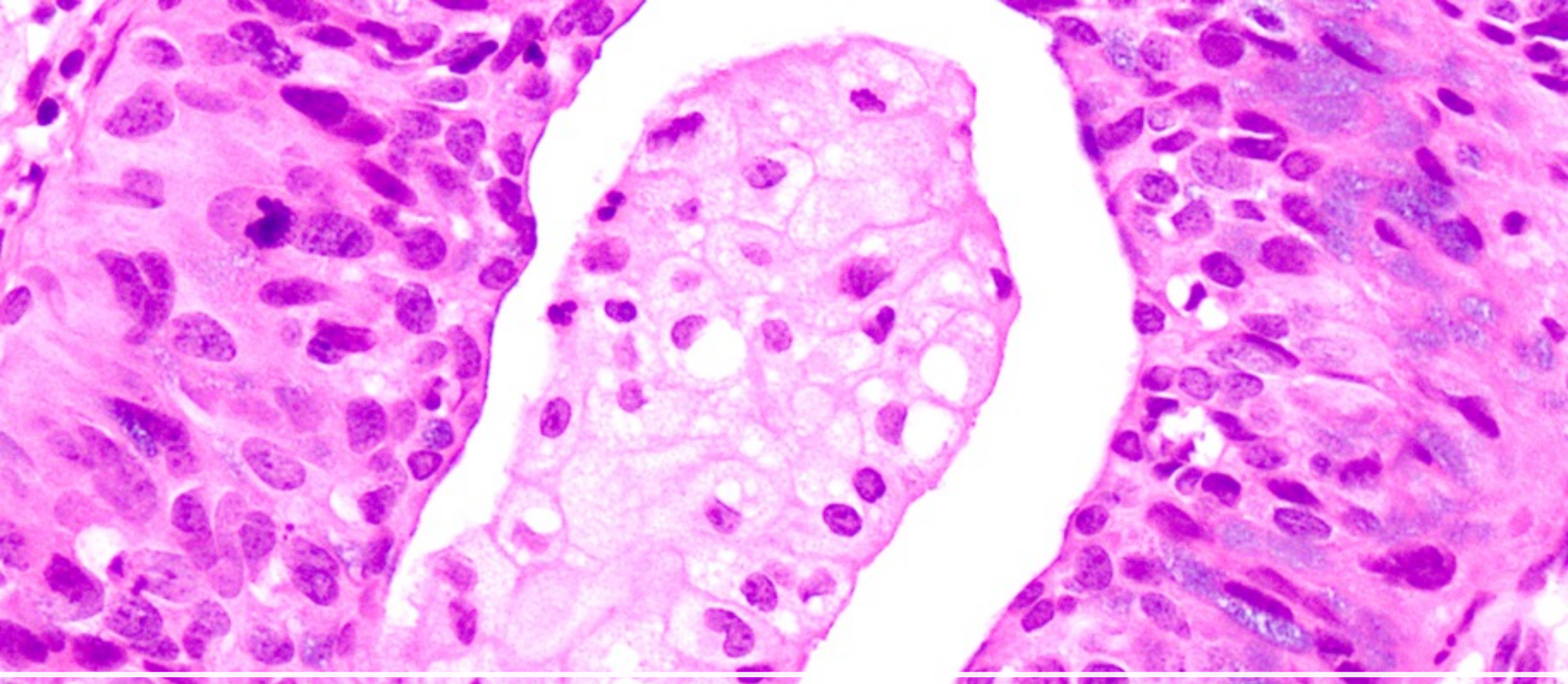
Brigitte M. Ronnett, MD,\*† Anna V. Yemelyanova, MD,\* Russell Vang, MD,\*†  
C. Blake Gilks, MD,‡ Dianne Miller, MD,§ Patti E. Gravitt, PhD,|| and Robert J. Kurman, MD\*†

**Clinical, Morphologic, and Molecular Features Associated With Ovarian Metastases From Pattern A Endocervical Adenocarcinomas**

*AJSP* 2022;46:509-518

Jacqueline Feinberg, MD,\* Anjelica Hodgson, MD,† Nadeem R. Abu-Rustum, MD,\*‡  
Kara Long Roche, MD,\*‡ and Kay J. Park, MD†





**Stratified Mucin-Producing Intraepithelial Lesion (SMILE)**



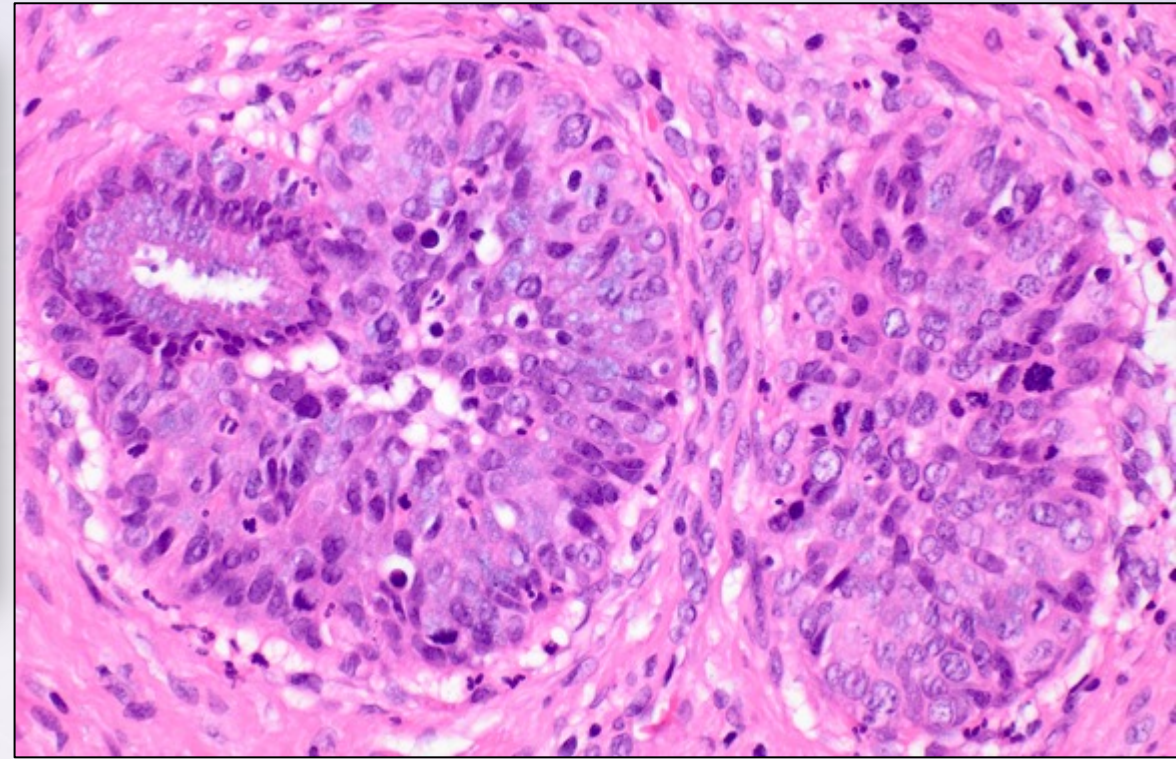


# Stratified Mucin-Producing Intraepithelial Lesions of the Cervix

Adenosquamous or Columnar Cell Neoplasia?

Jeong-Ja Park, M.D., Deqin Sun, M.S., Bradley J. Quade, M.D., Ph.D.,  
Cythia Flynn, M.D., Ellen E. Sheets, M.D., Annie Yang, B.S.,  
Frank McKeon, Ph.D., and Christopher P. Crum, M.D.

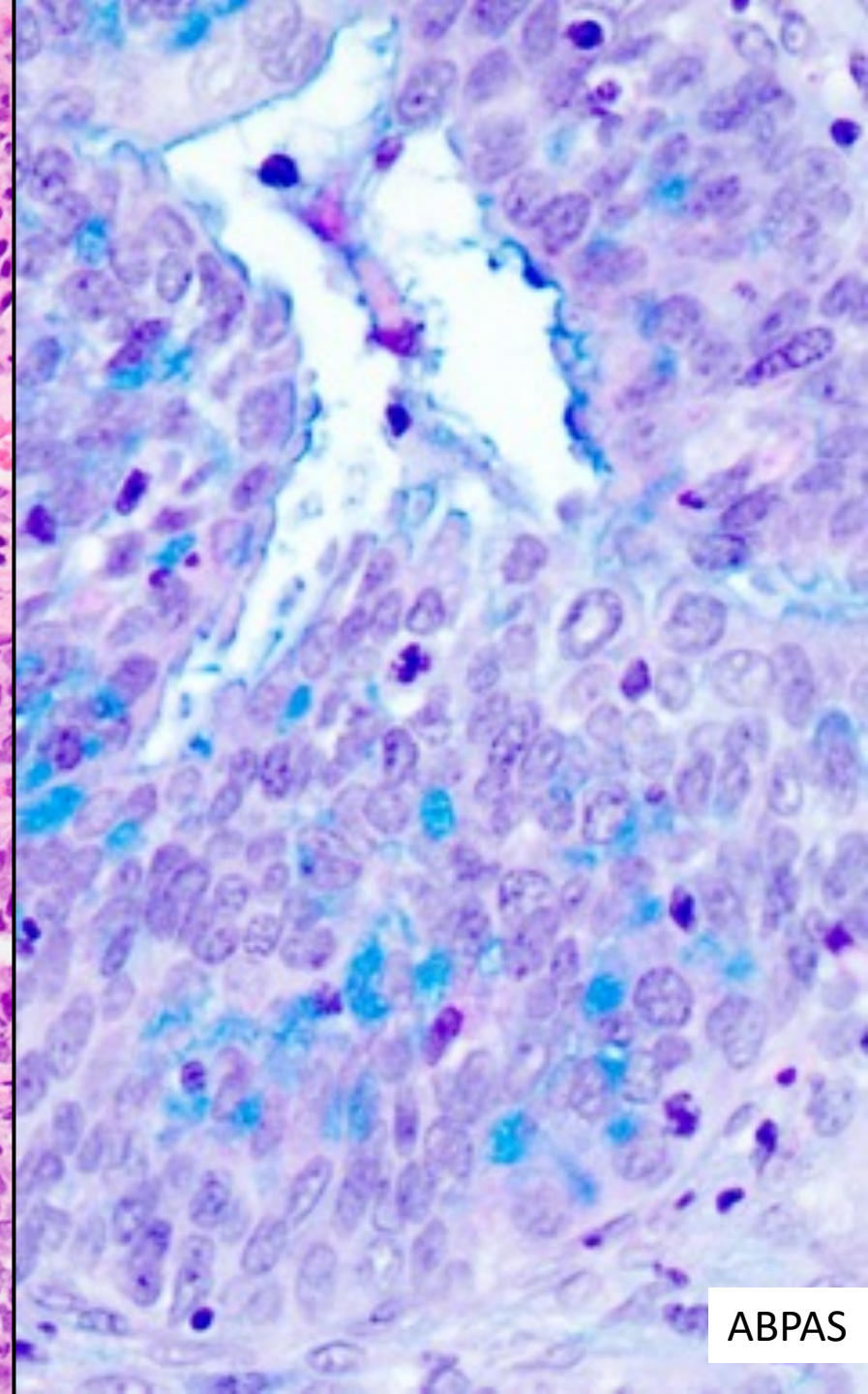
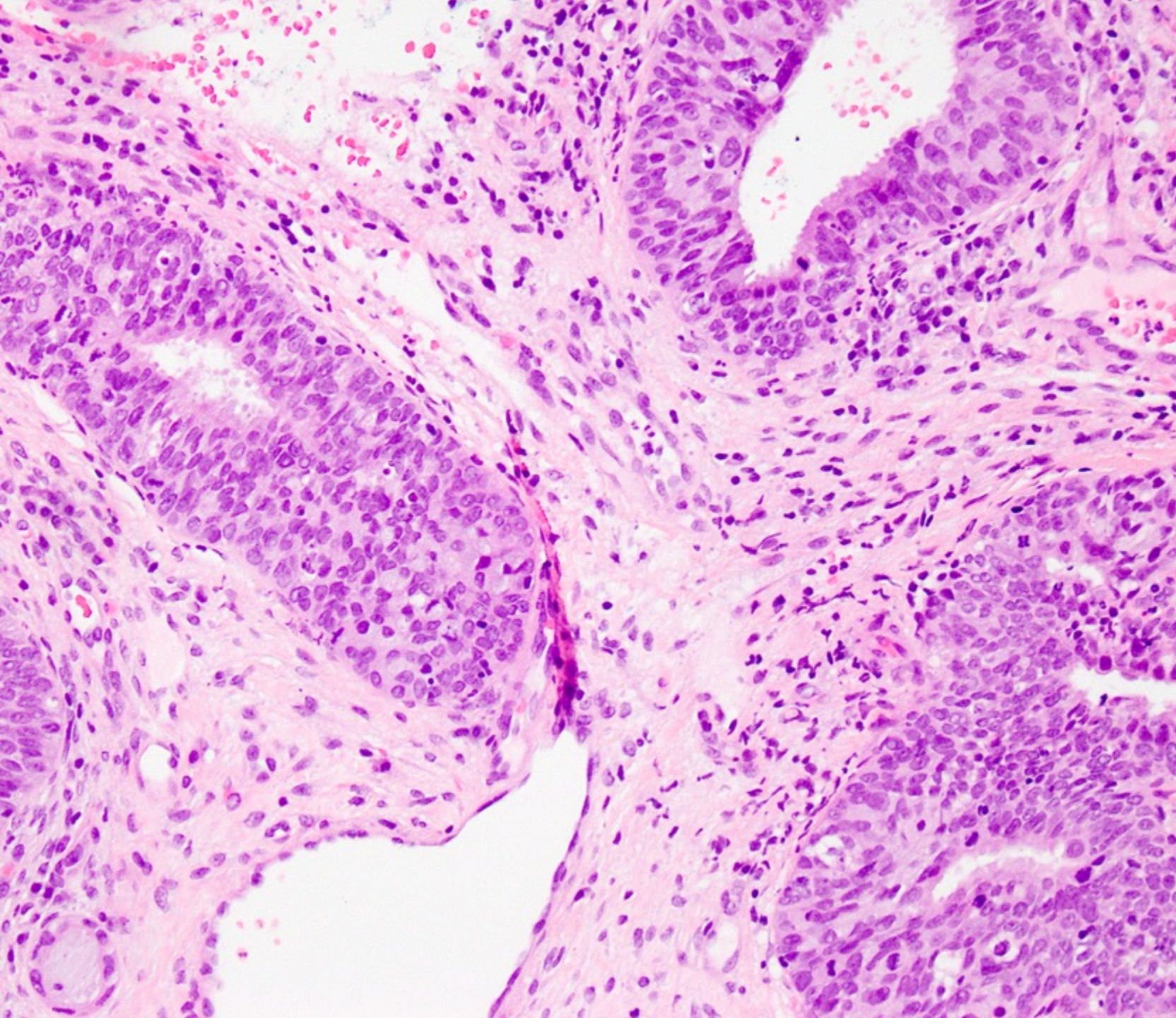
*AJSP 2000;24:1414-1419*



- Added to 4<sup>th</sup> Edition WHO 2014: Subtype of AIS
- Uncommon; 0.6% of 69 cervical cervical loop / punch biopsies
- Rare in pure form; 4% in a series of 69
- Usually admixed HSIL 93% / AIS 42% / carcinoma 10%
- Marker of phenotypic instability

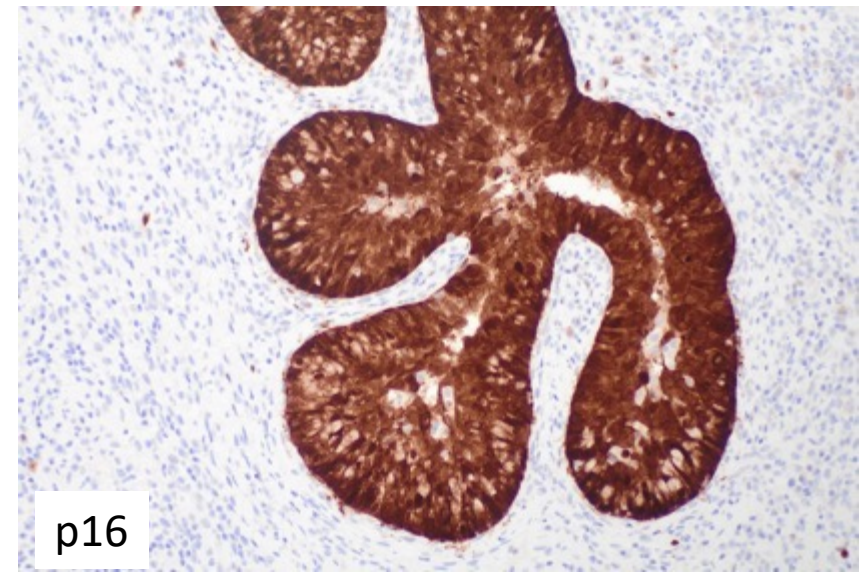
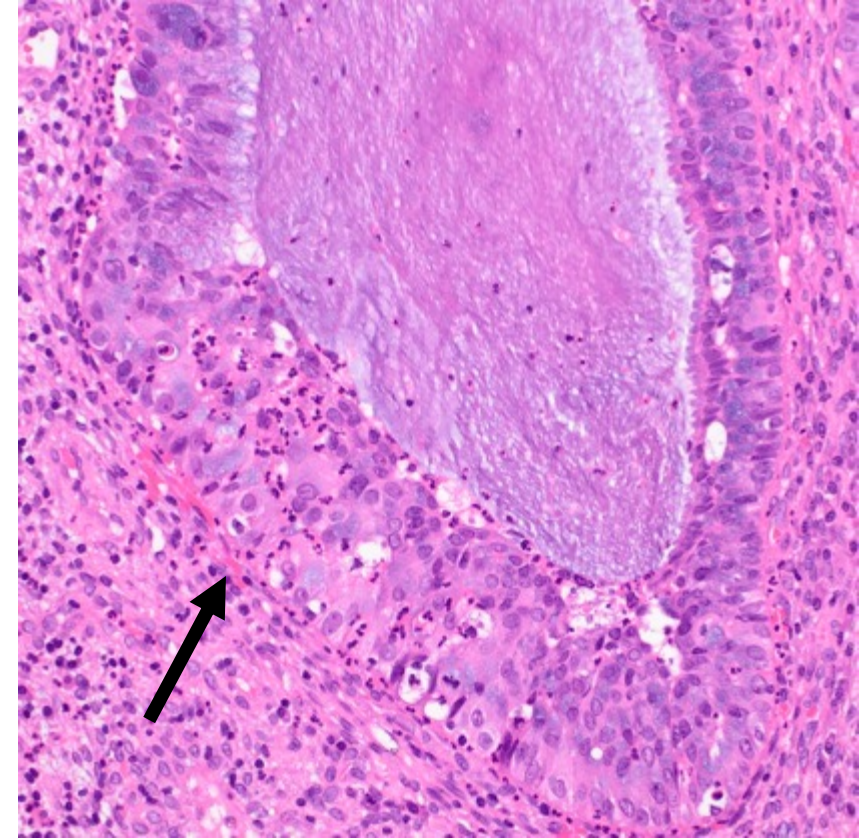
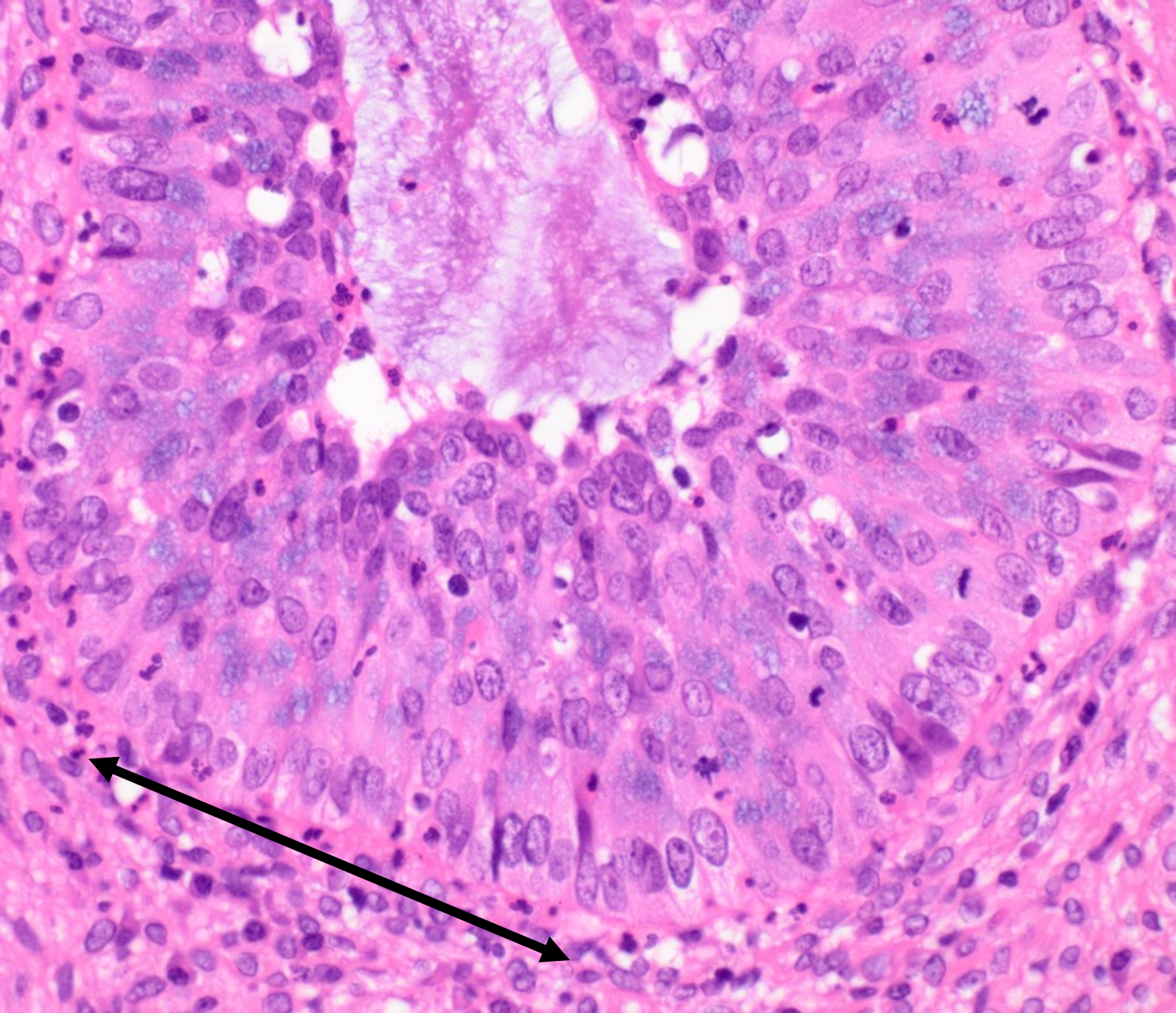
*Histopathol 2015;66:658-663*  
*Diagn Cytopthol 2016;44:20-25*  
*AJSP 2016;40:262-269*  
*Acta Cytologica 2016;60:225-231*





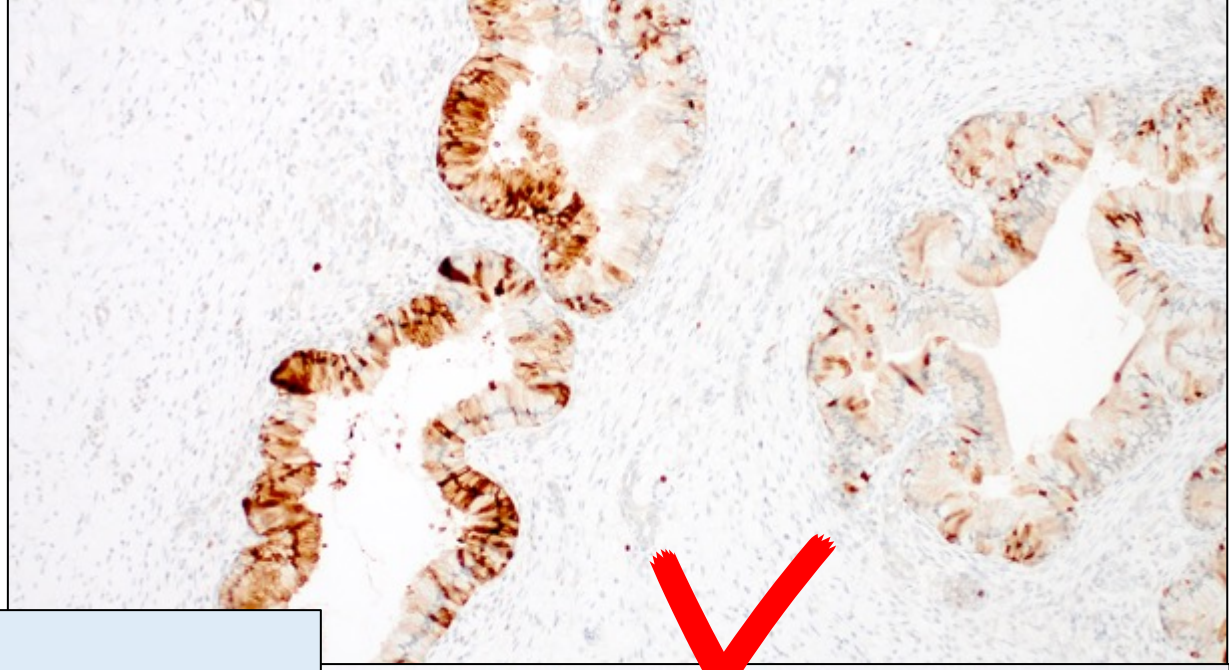
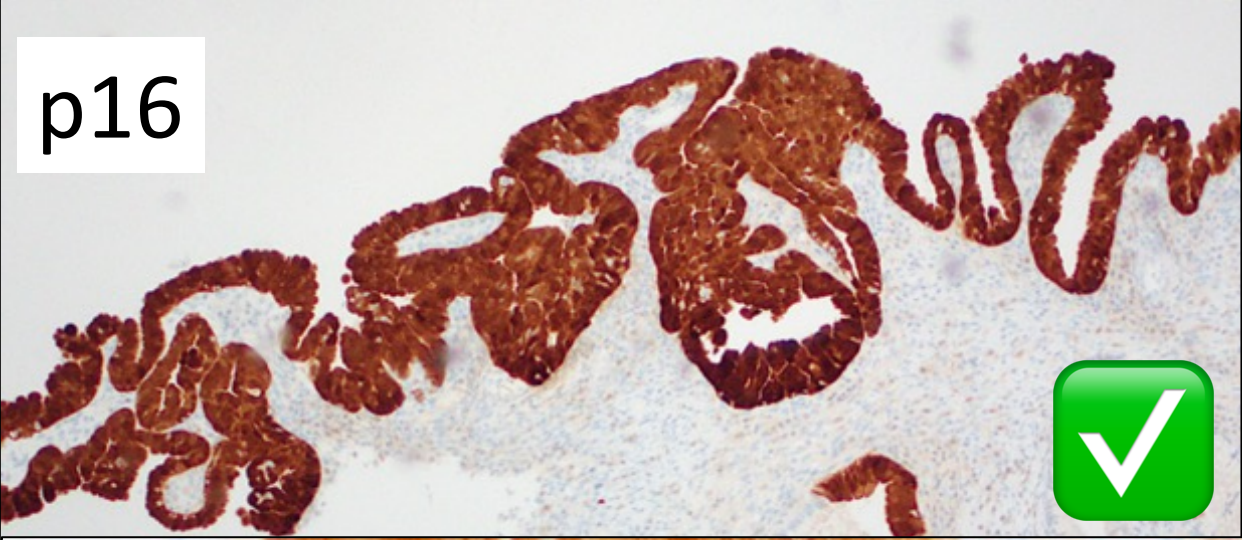
ABPAS





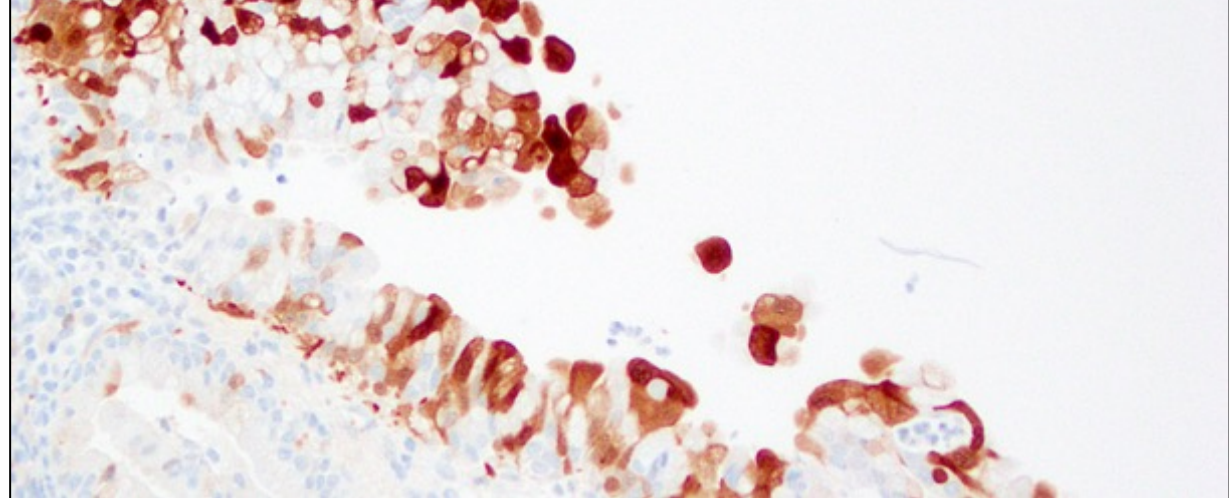
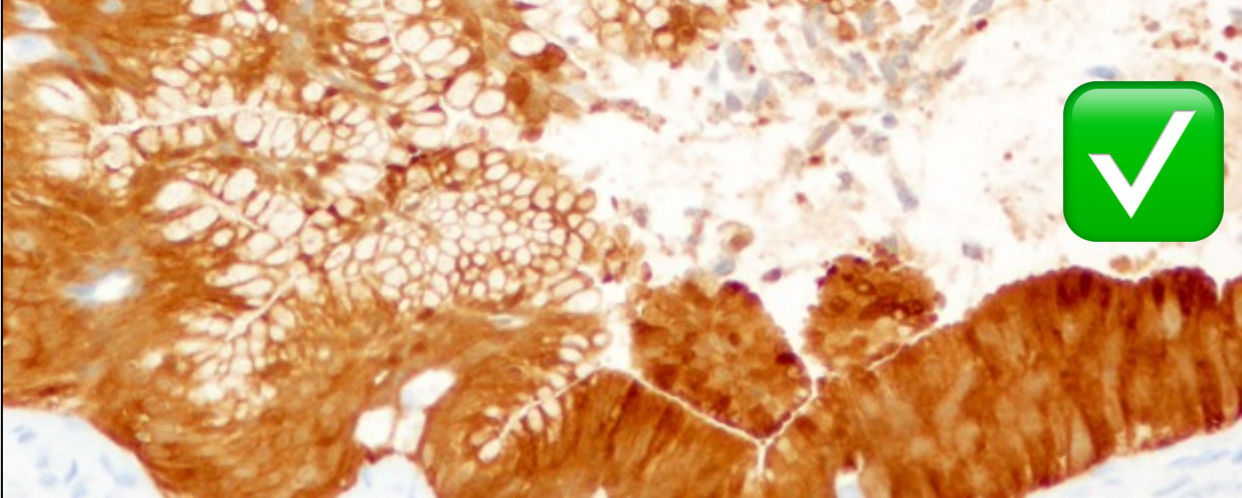
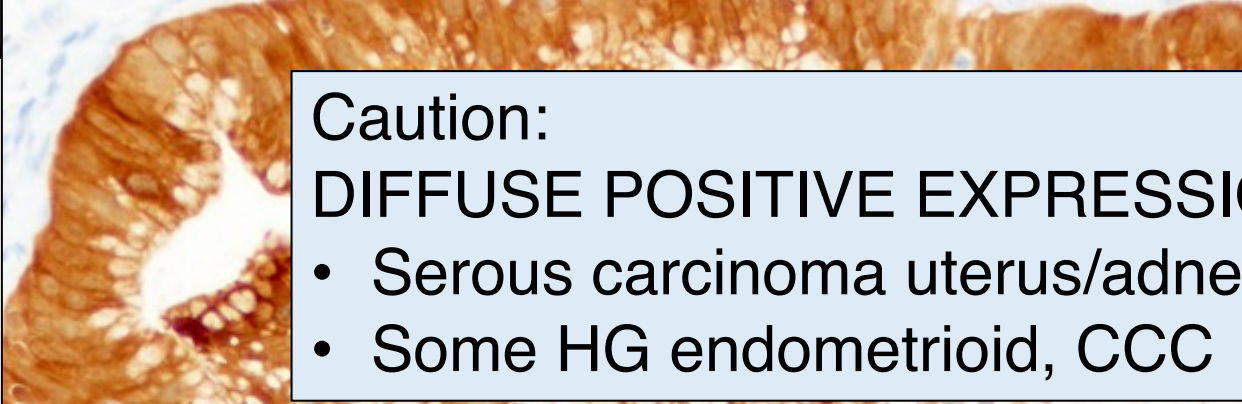


p16



Caution:  
DIFFUSE POSITIVE EXPRESSION

- Serous carcinoma uterus/adnexa (HGSC)
- Some HG endometrioid, CCC





# Immunohistochemistry

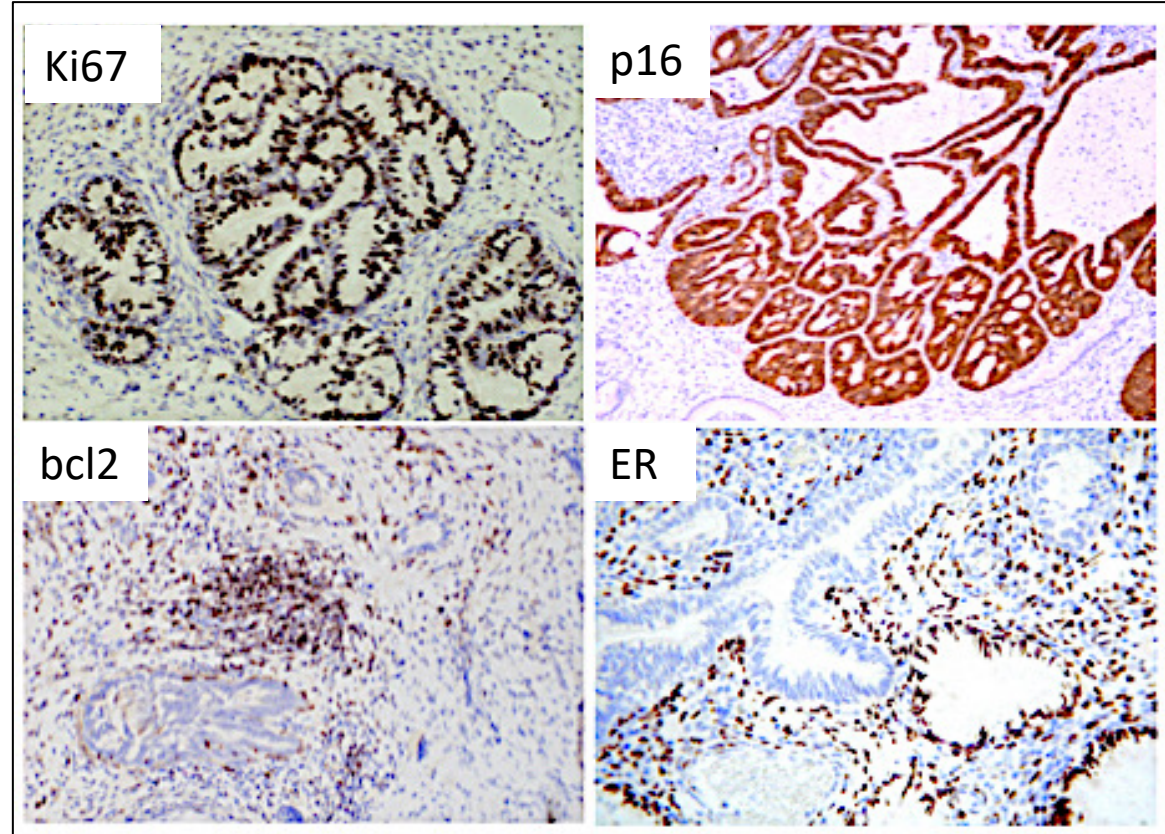
ER/PR  
Vimentin  
bcl2  
PAX2

} AIS usually negative

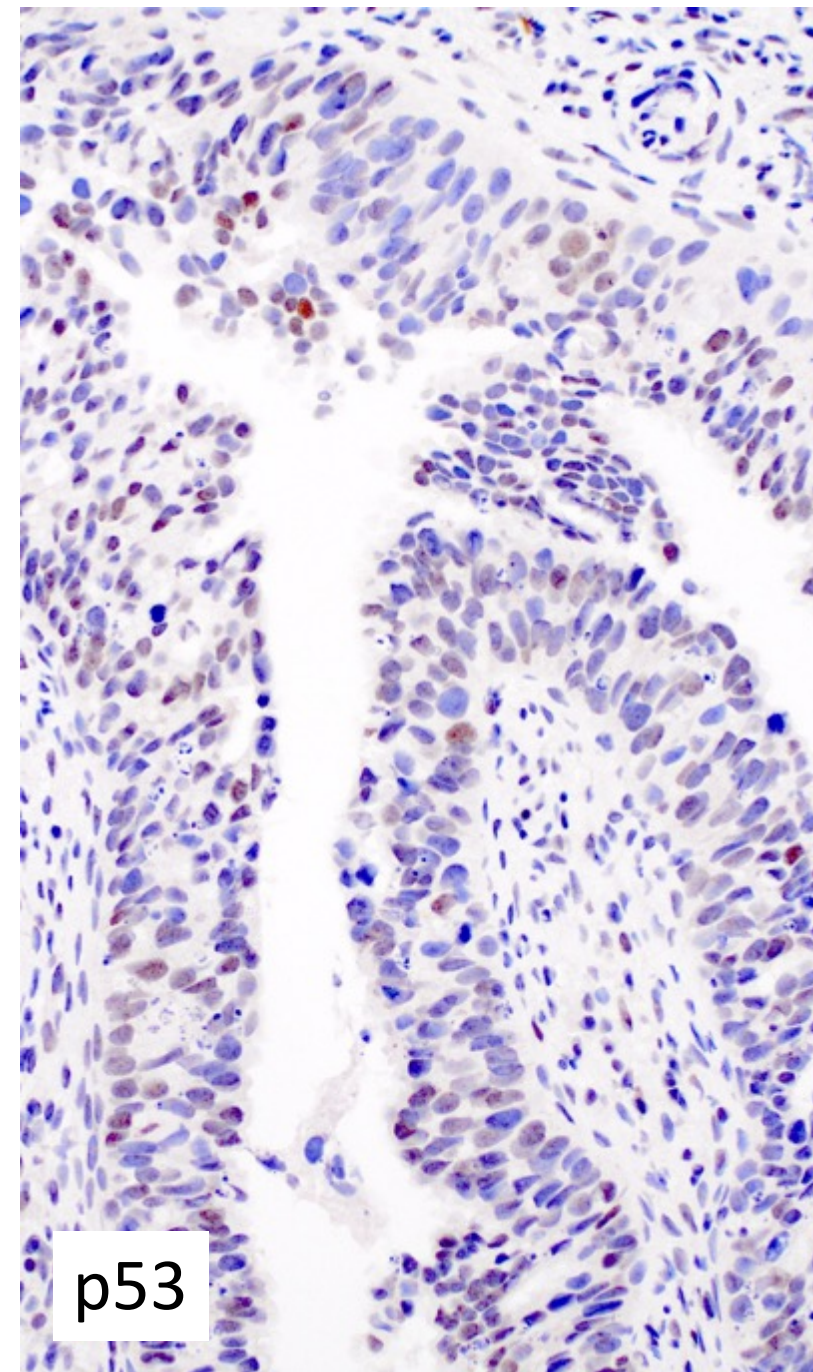
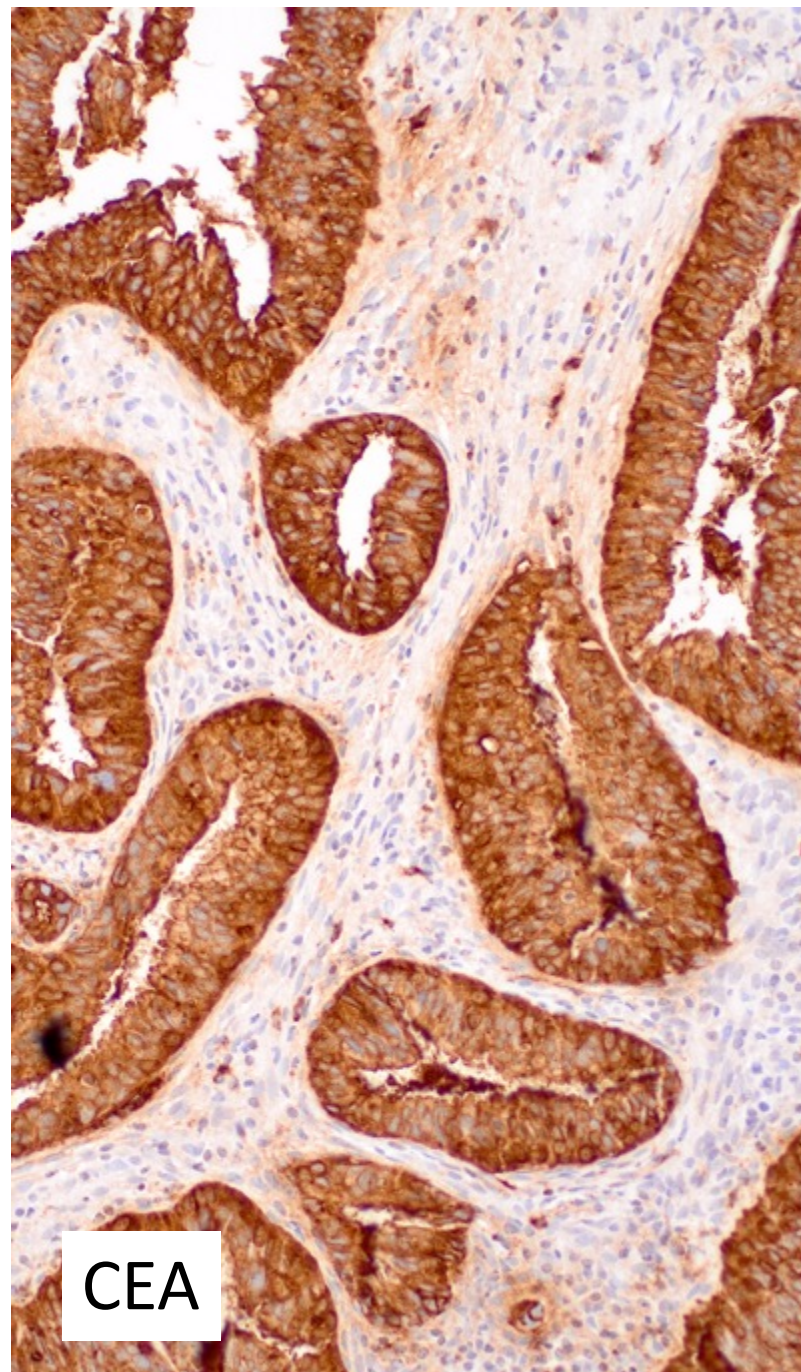
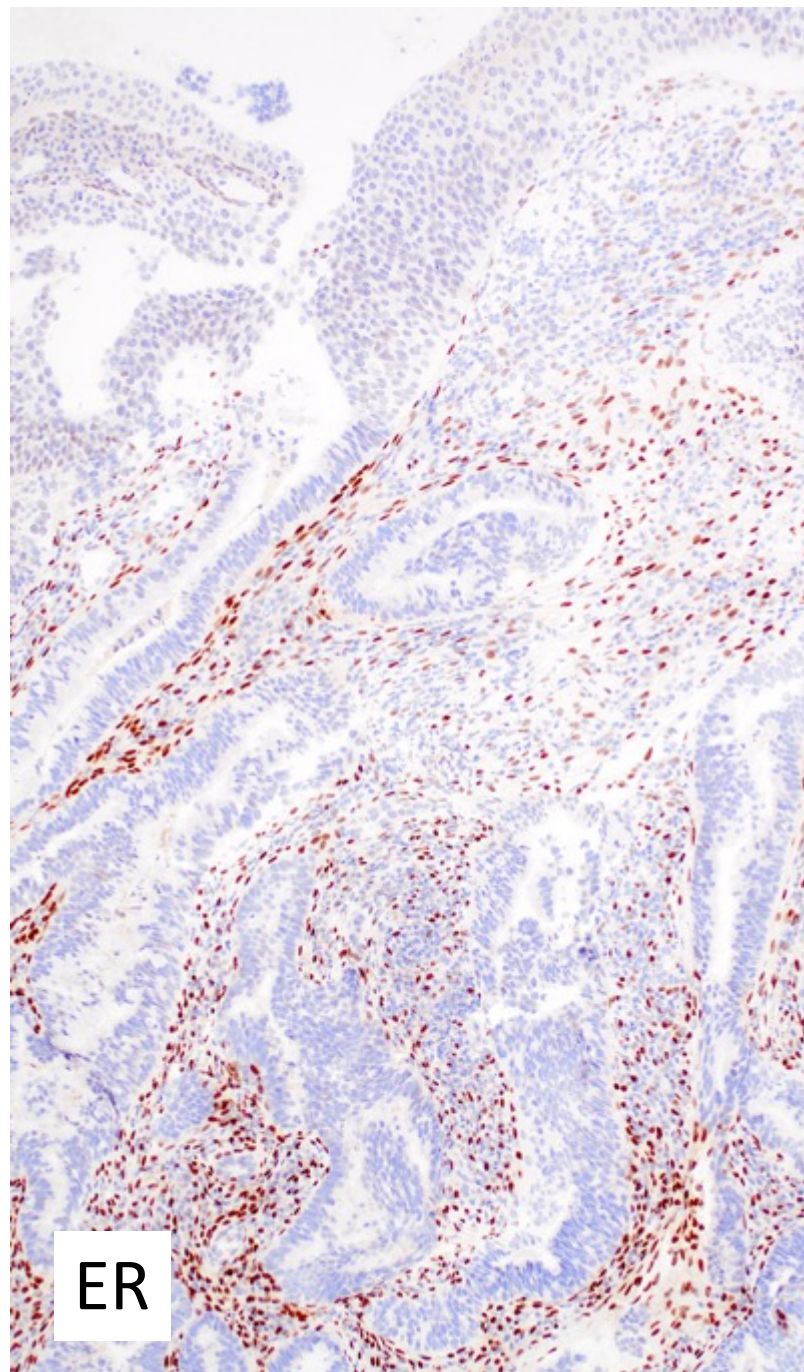
**Ki-67**  
Increased, >30-75% in most  
<10% in benign glandular lesions

**CEA**  
Often positive in AIS

**CDX2**  
Intestinal differentiation

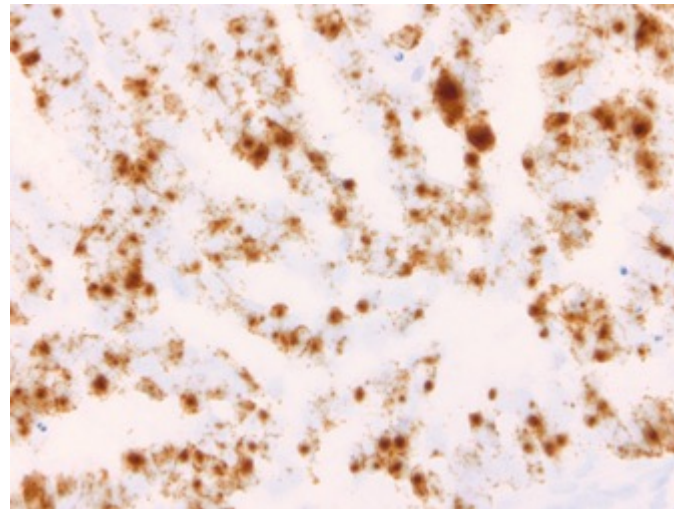
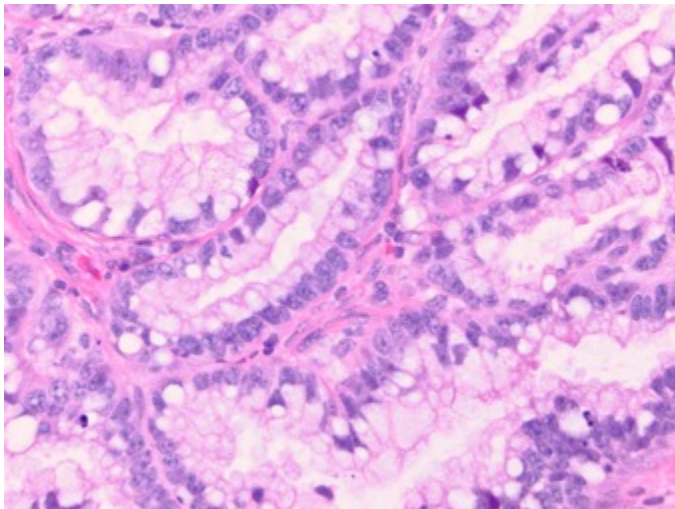
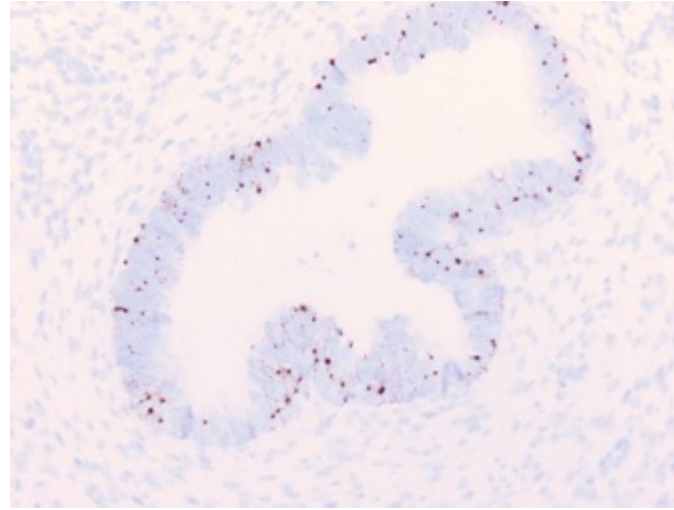
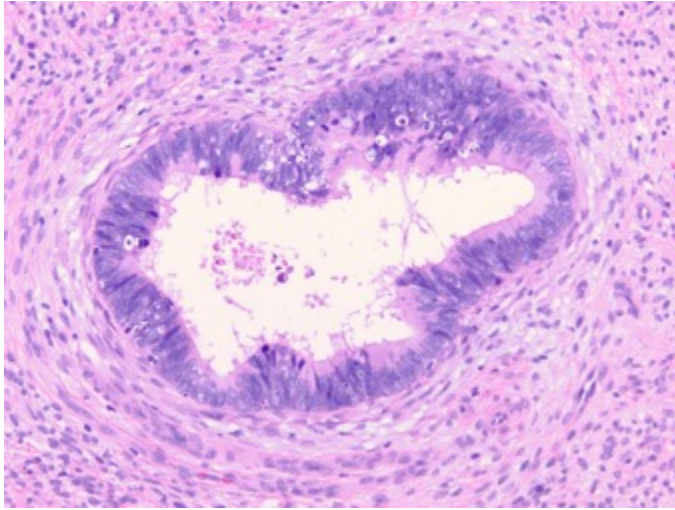








# HPV In Situ Hybridization

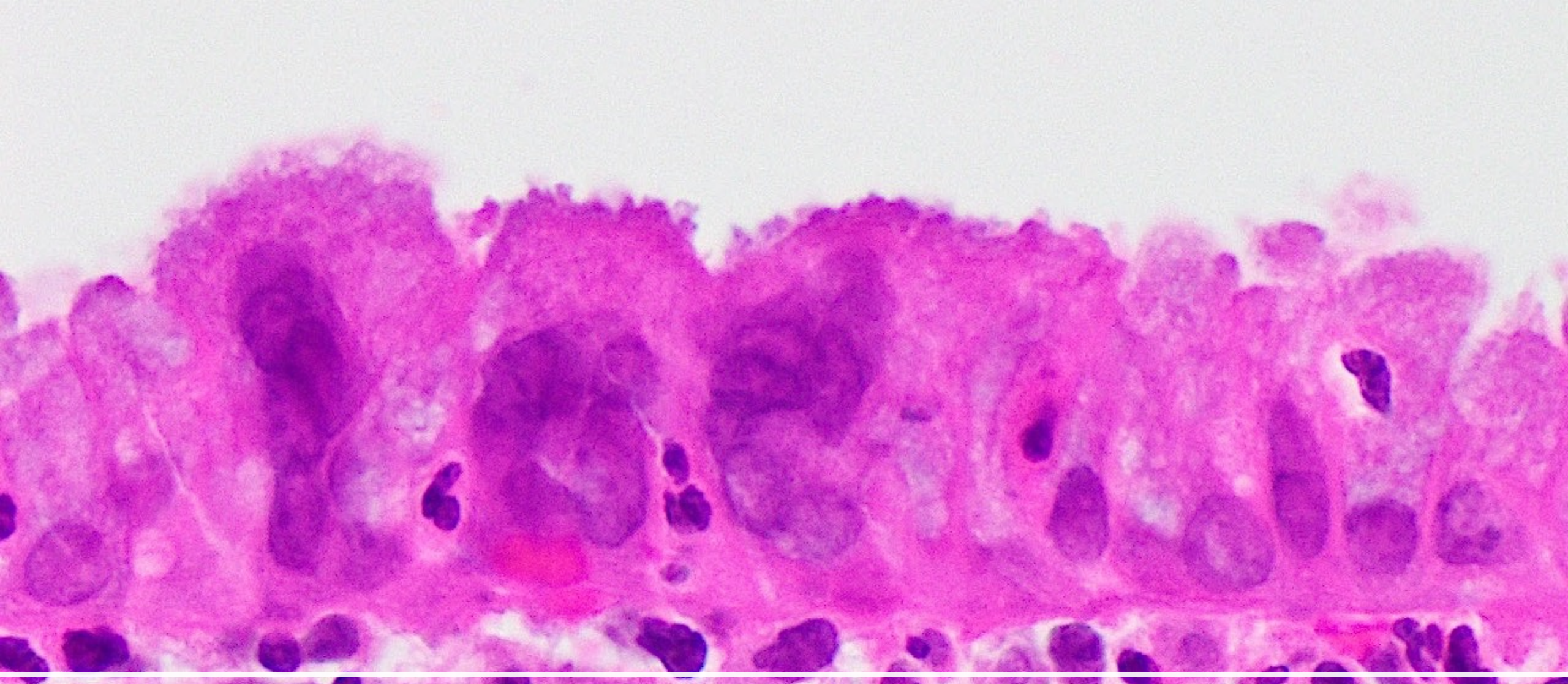


## RNA ISH:

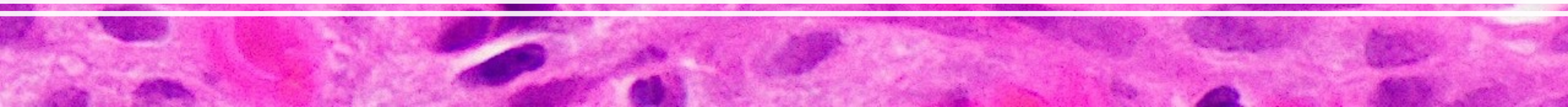
- Detects transcriptionally active HPV
- Localized to nuclei and/or cytoplasm
- Most ubiquitous test detects 18 HR HPV subtypes

16, 18, 26, 31, 33, 35,  
39, 45, 51, 52, 53, 56,  
58, 59, 66, 68, 73, 82





**Reactive change – a not so deceptive mimic**





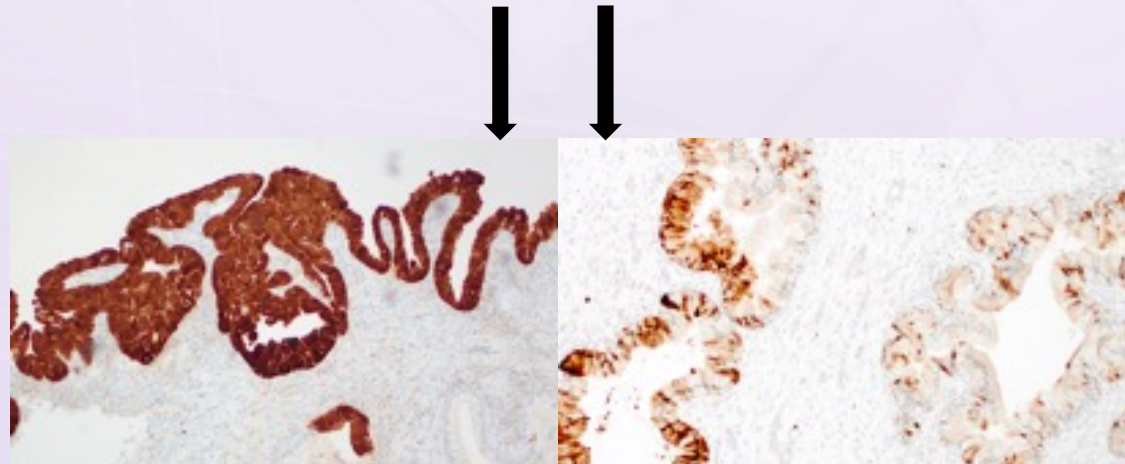
# Reactive change in endocervical cells

Not well defined in the literature

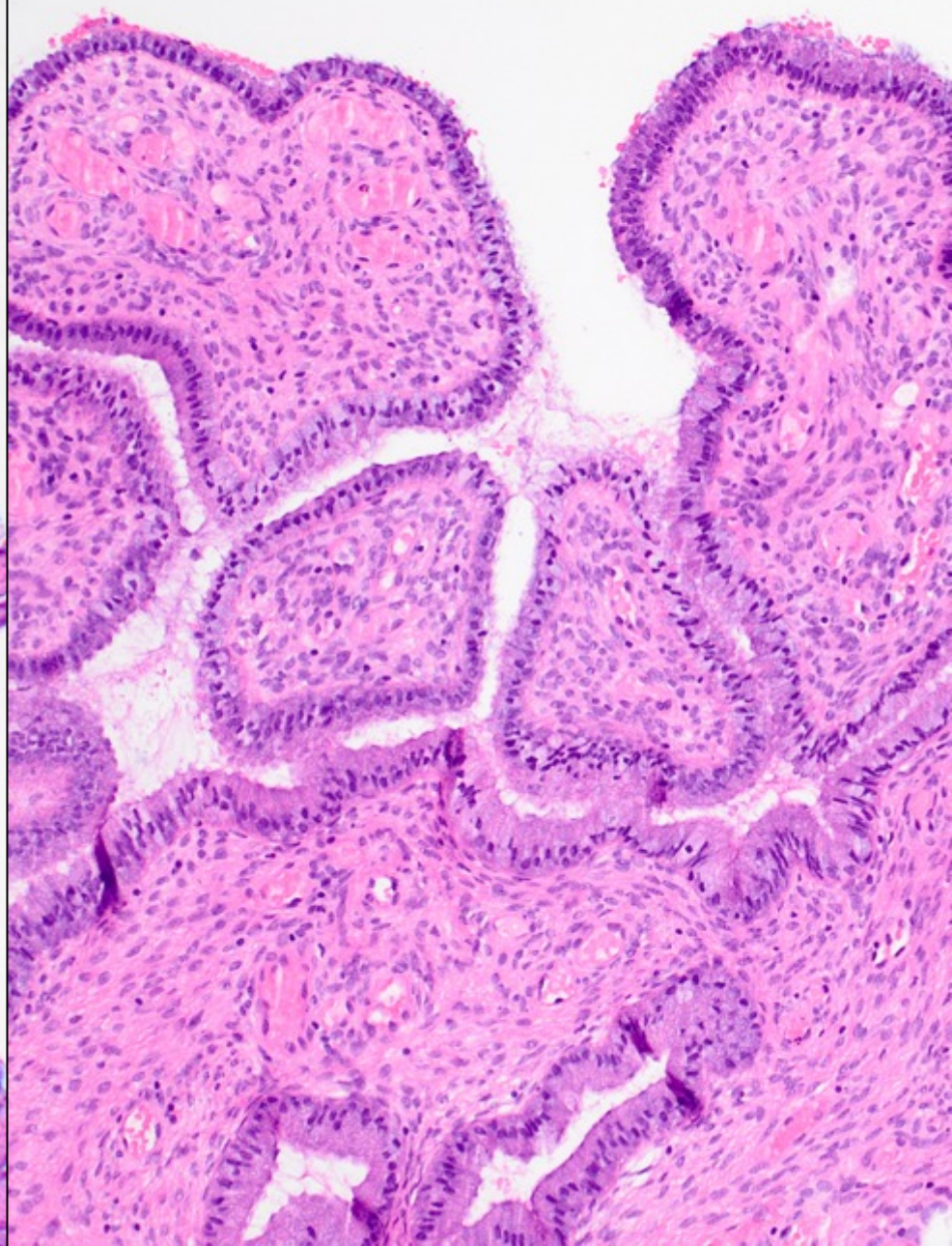
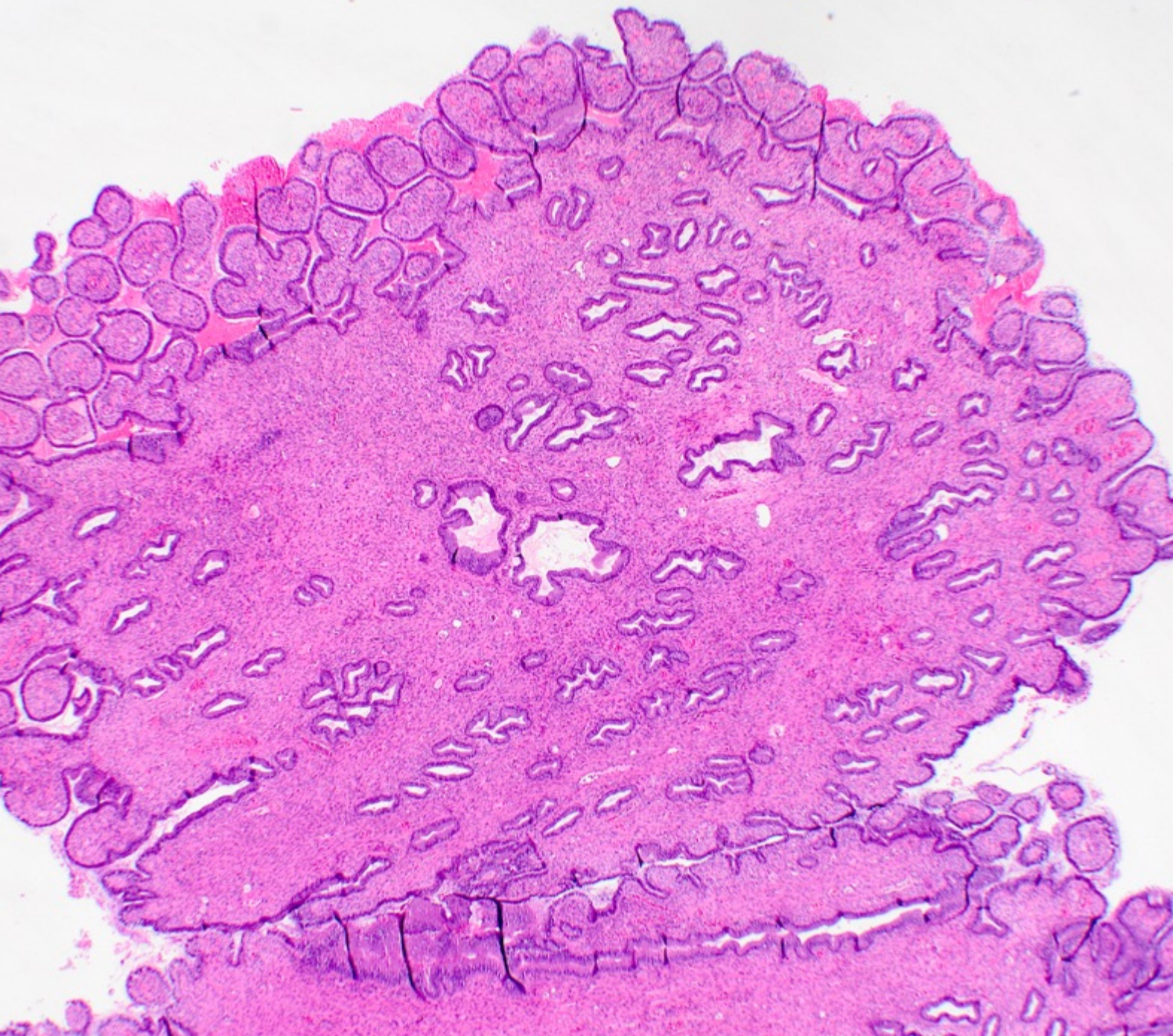
Implies response to inflammation/infection, mechanical trauma, radiation

2 scenarios

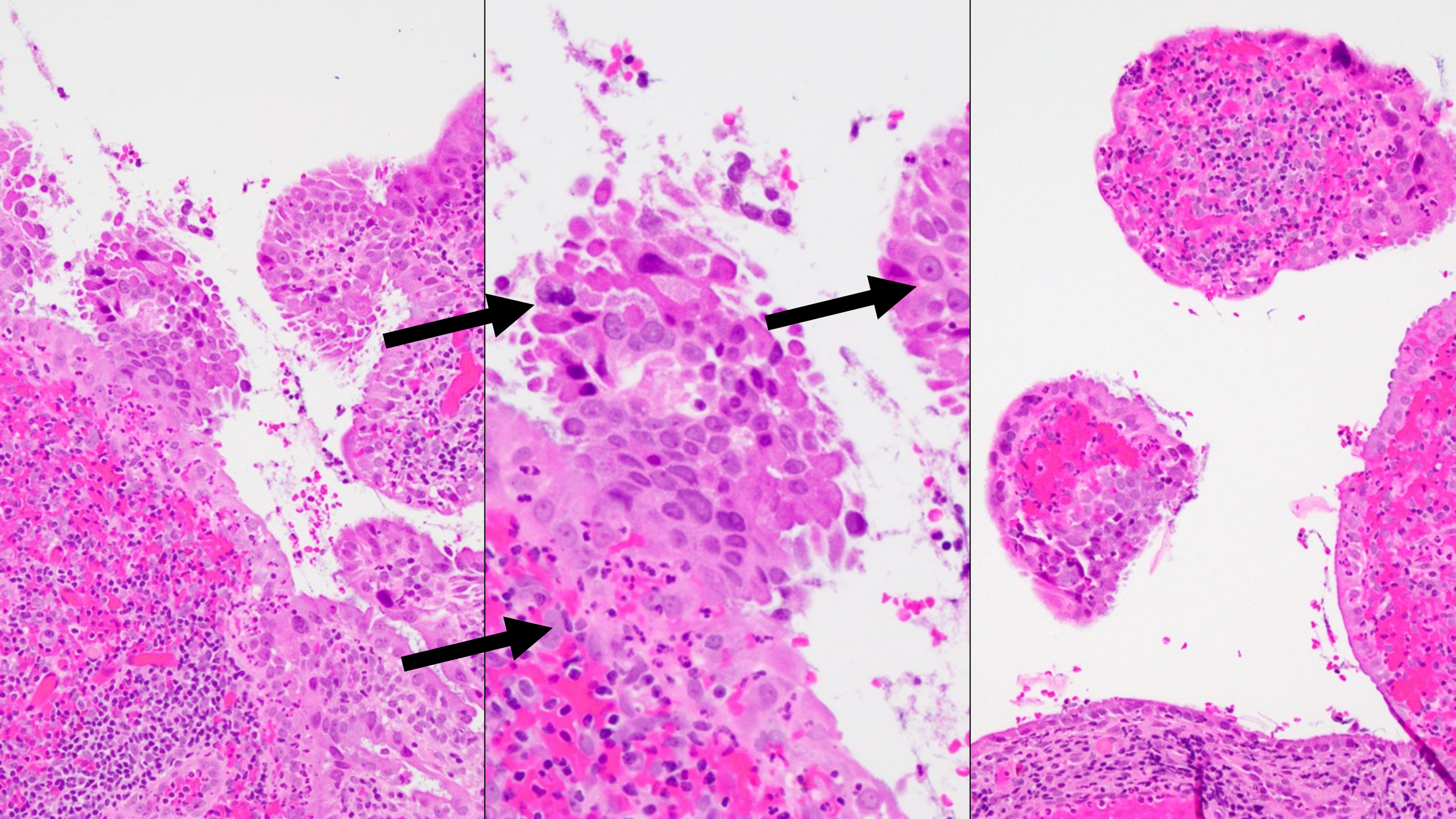
- Comfortably dismissed as benign – most cases
- Could this be AIS? ... former endocervical glandular dysplasia ~~LGCGIN?~~



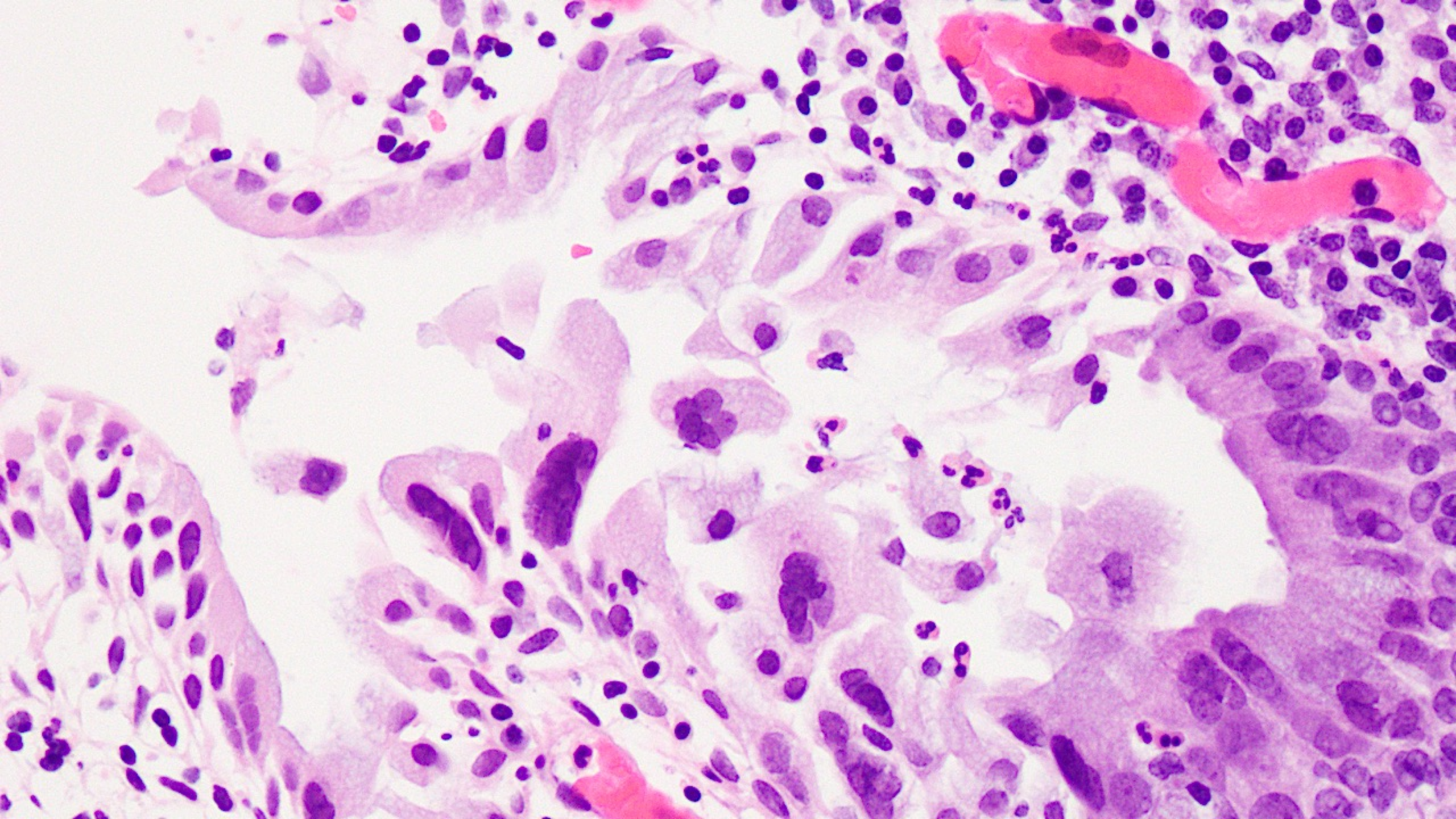




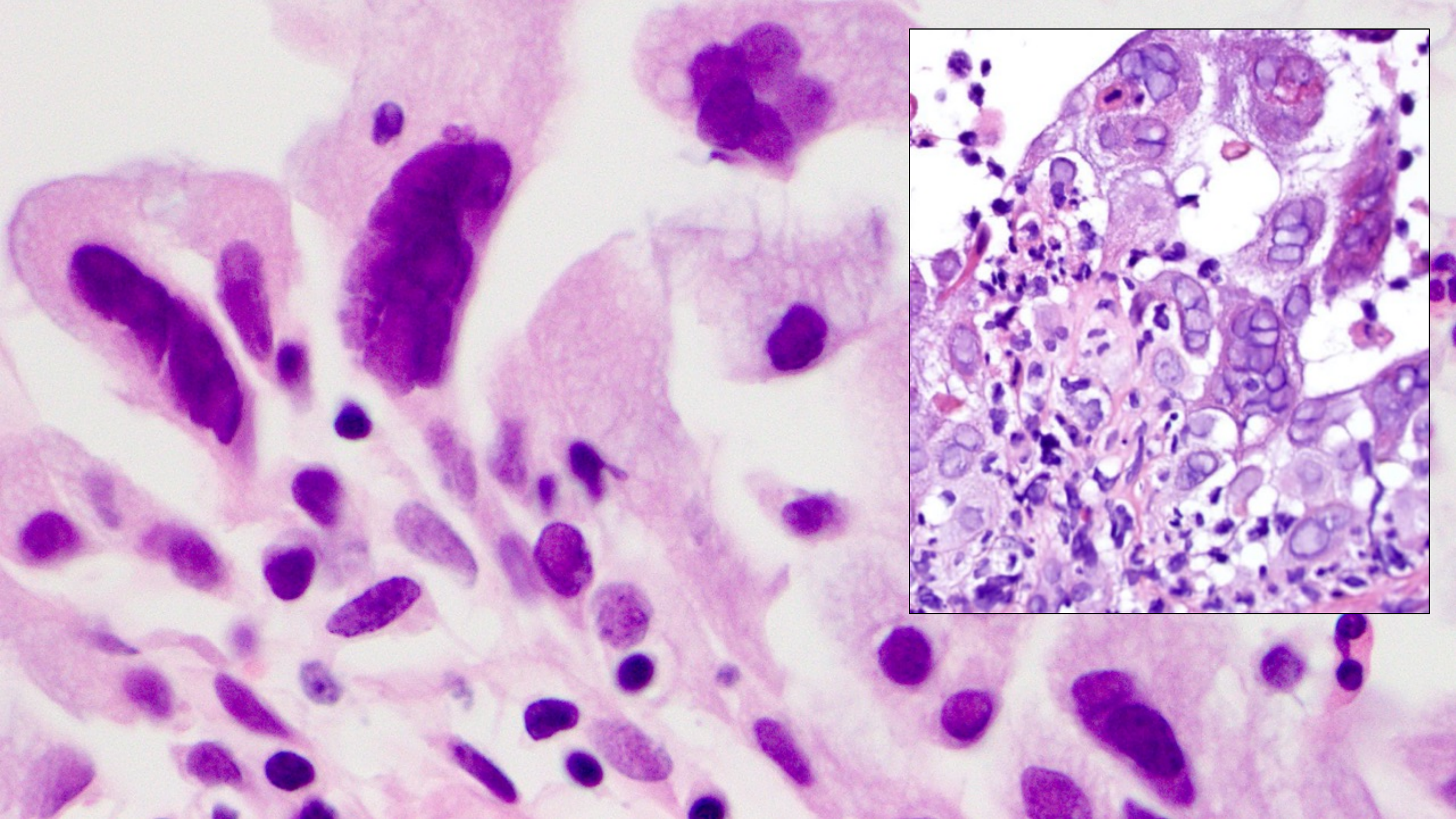




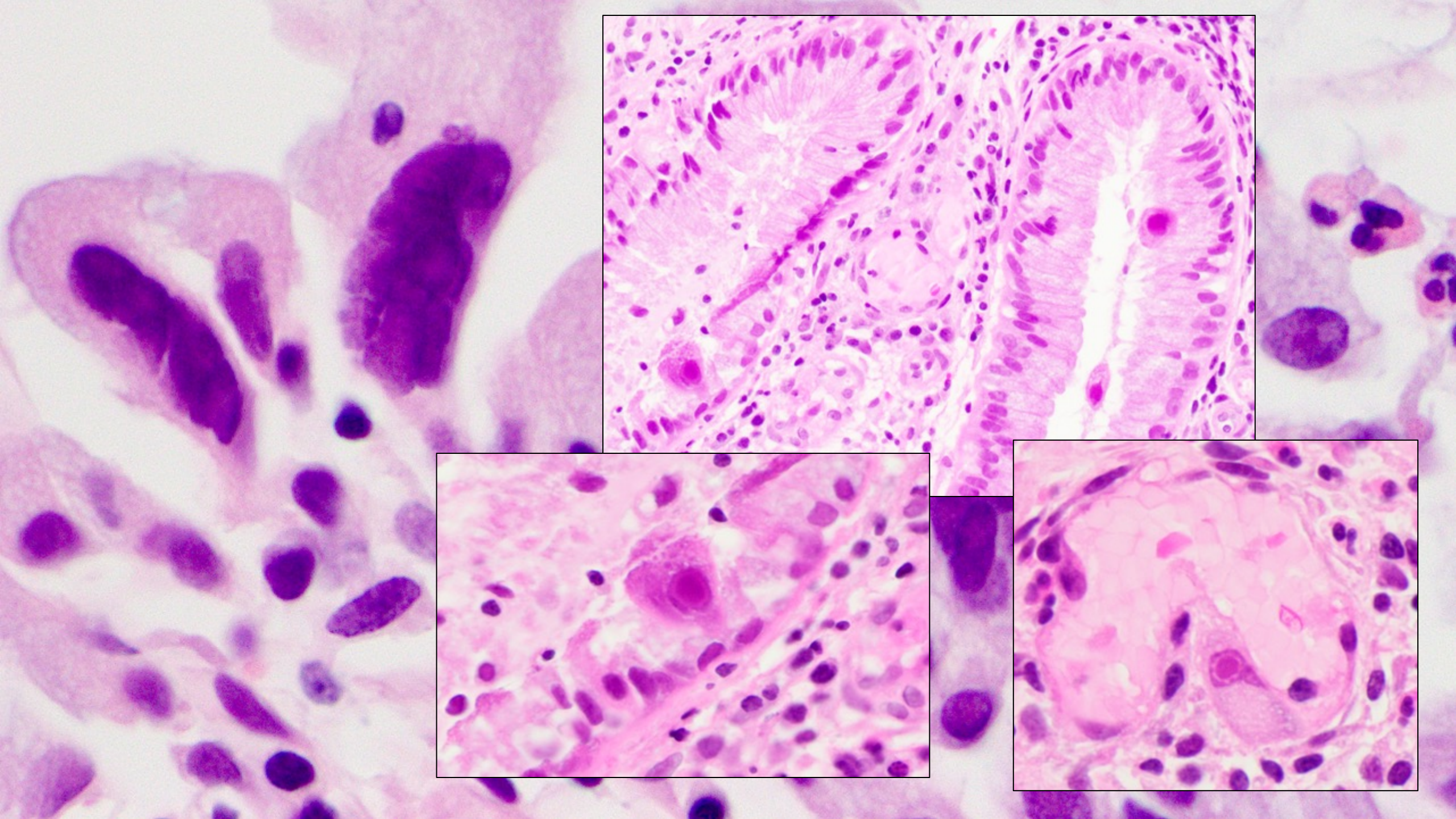














## ORIGINAL ARTICLE

# Cytomegalovirus infection of the cervix: morphological observations in five cases of a possibly under-recognised condition

C E McGalie, H A McBride, W G McCluggage

---

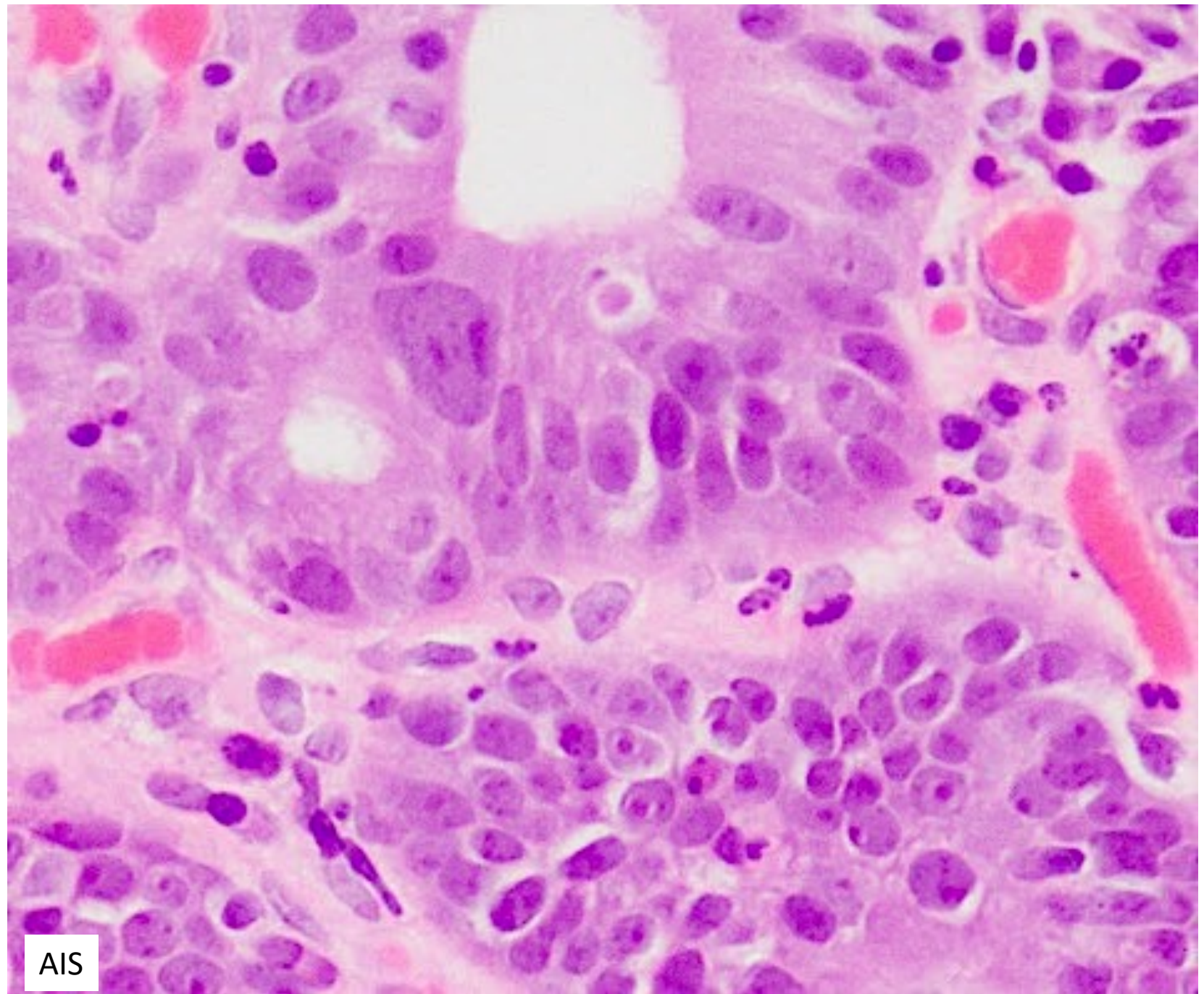
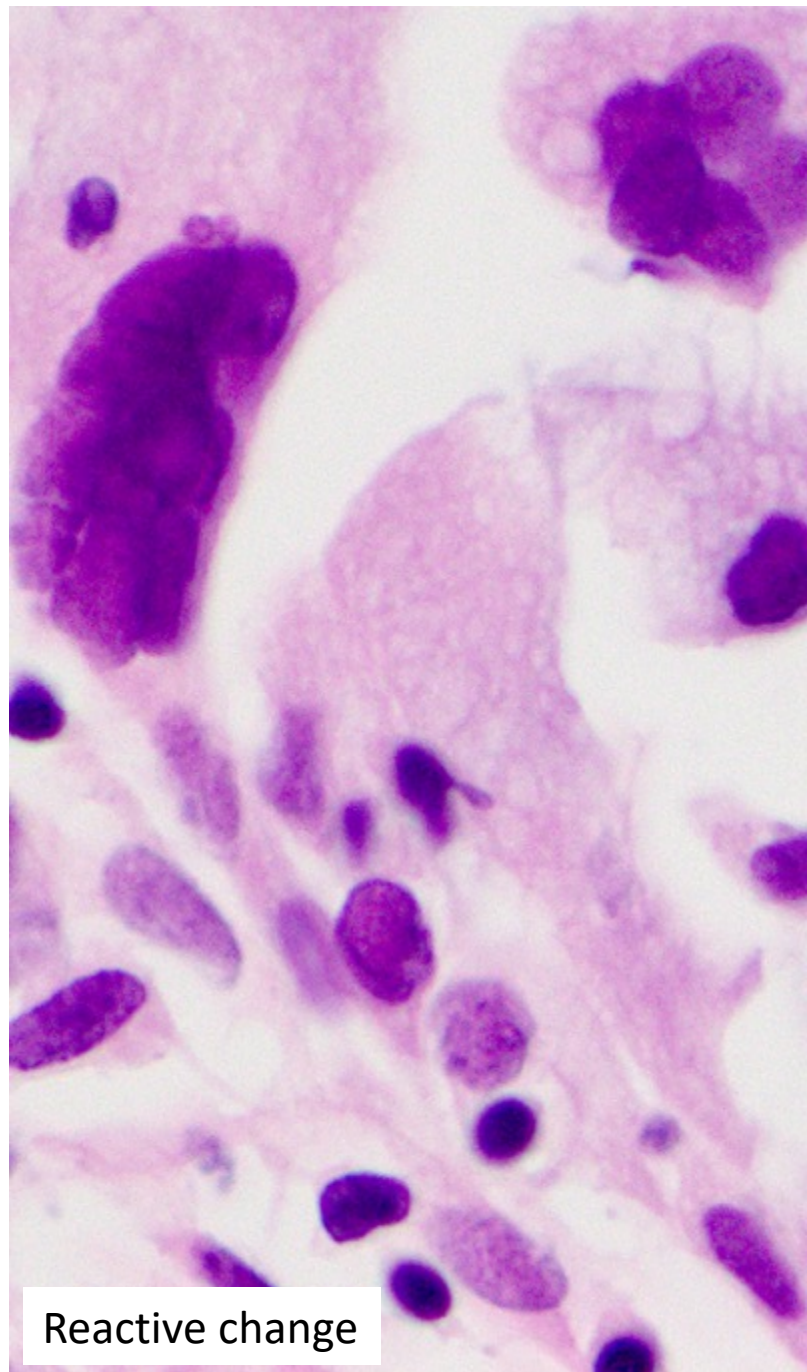
*J Clin Pathol* 2004;**57**:691–694. doi: 10.1136/jcp.2004.016162

- Probably more common than we appreciate
- Clues: Dense inflammation, lymphoid follicles, fibrin thrombi in small vessels
- Unclear if represents current vs. latent infection, genital tract vs. systemic

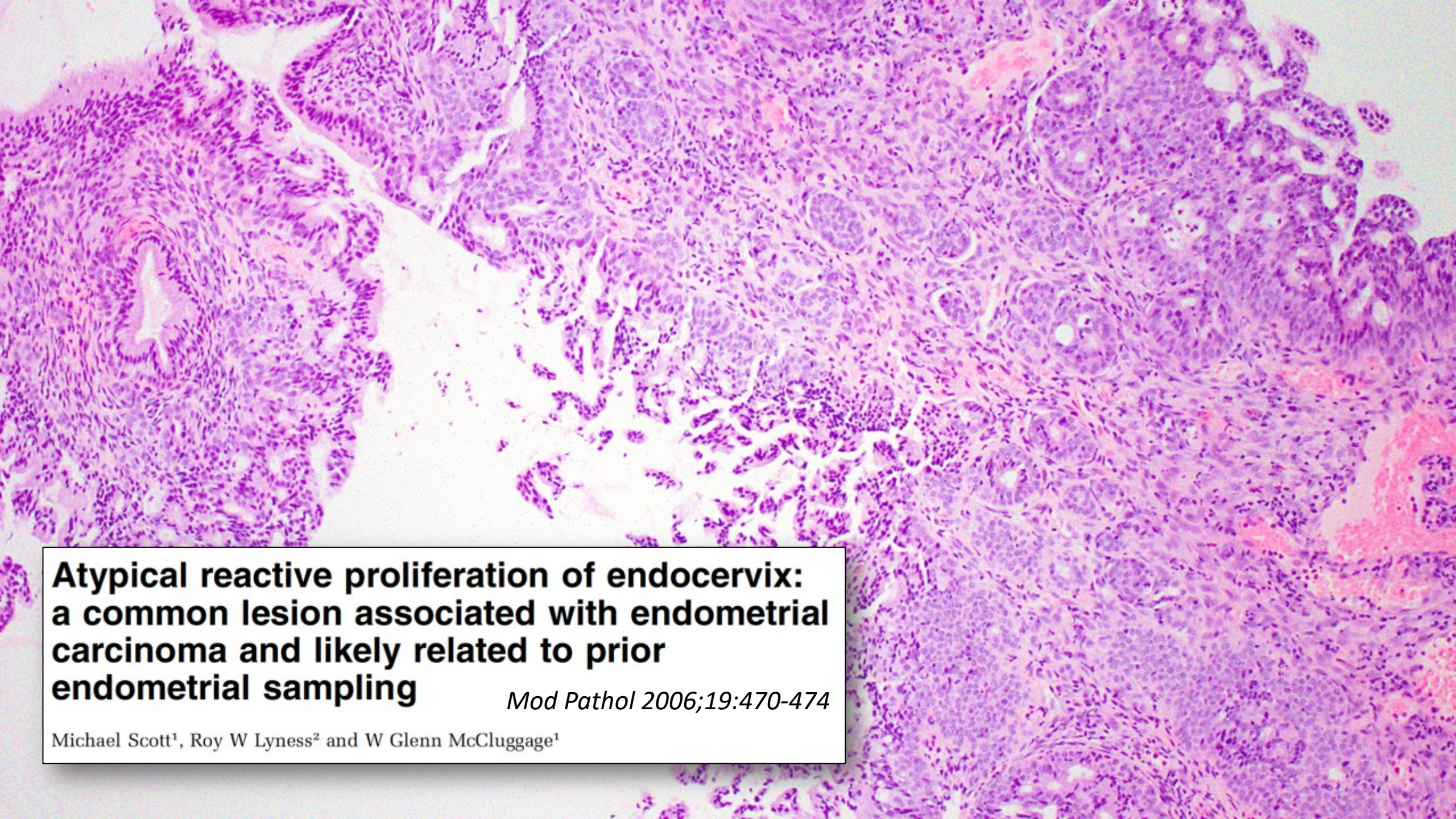
### Significance:

- May be associated with immunocompromise – HIV
- May be of relevance if active infection in pregnancy







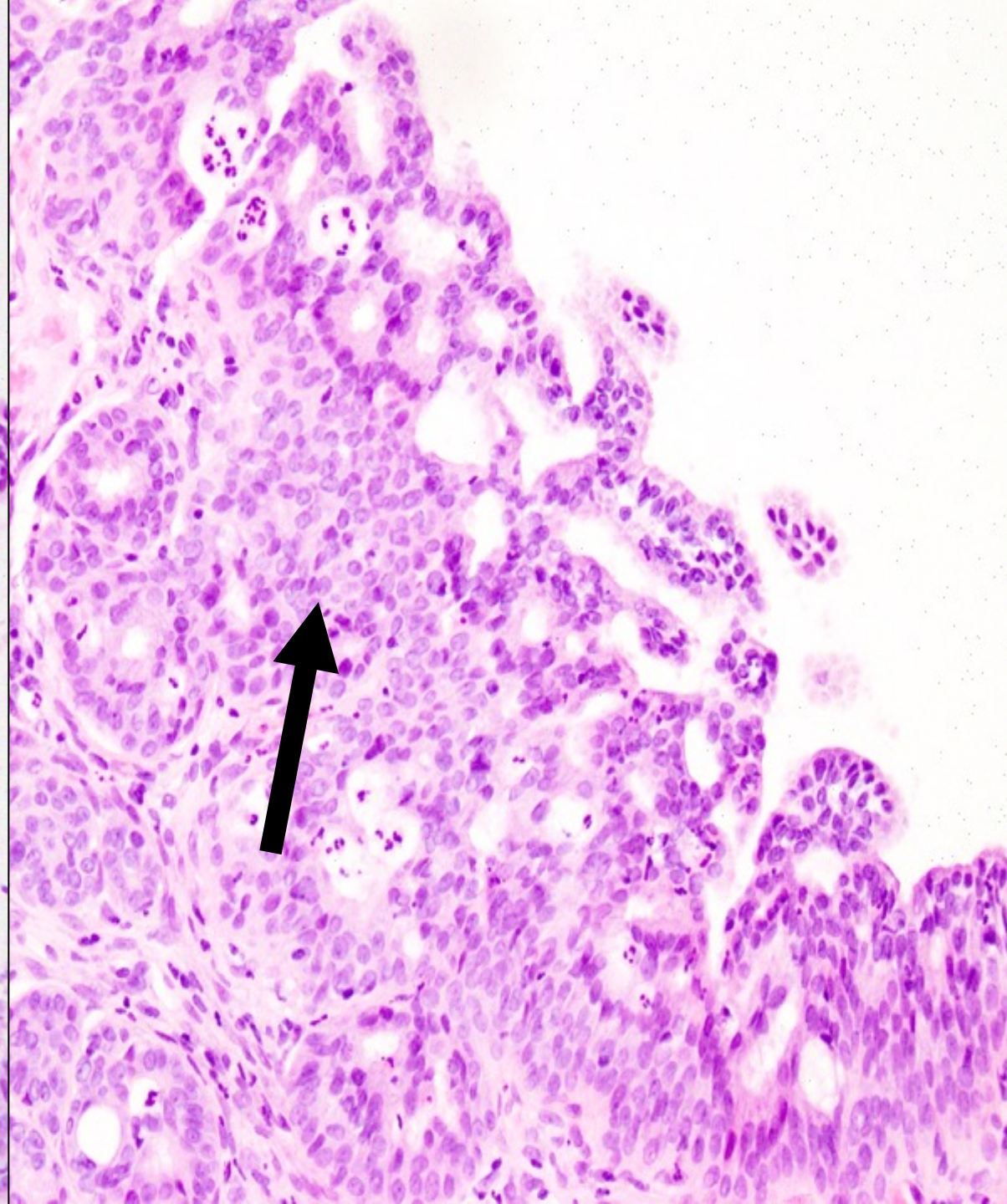
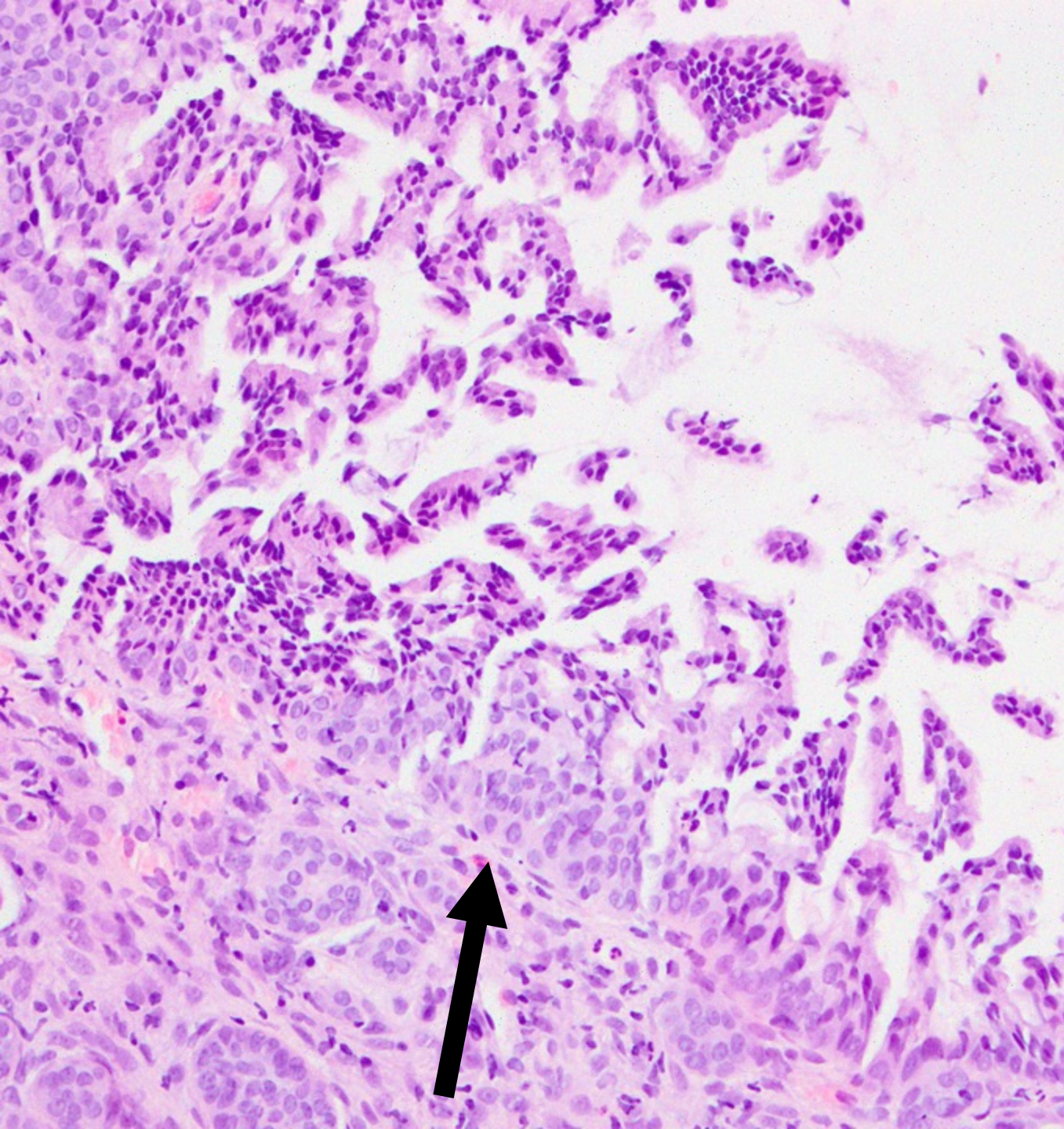


**Atypical reactive proliferation of endocervix:  
a common lesion associated with endometrial  
carcinoma and likely related to prior  
endometrial sampling**

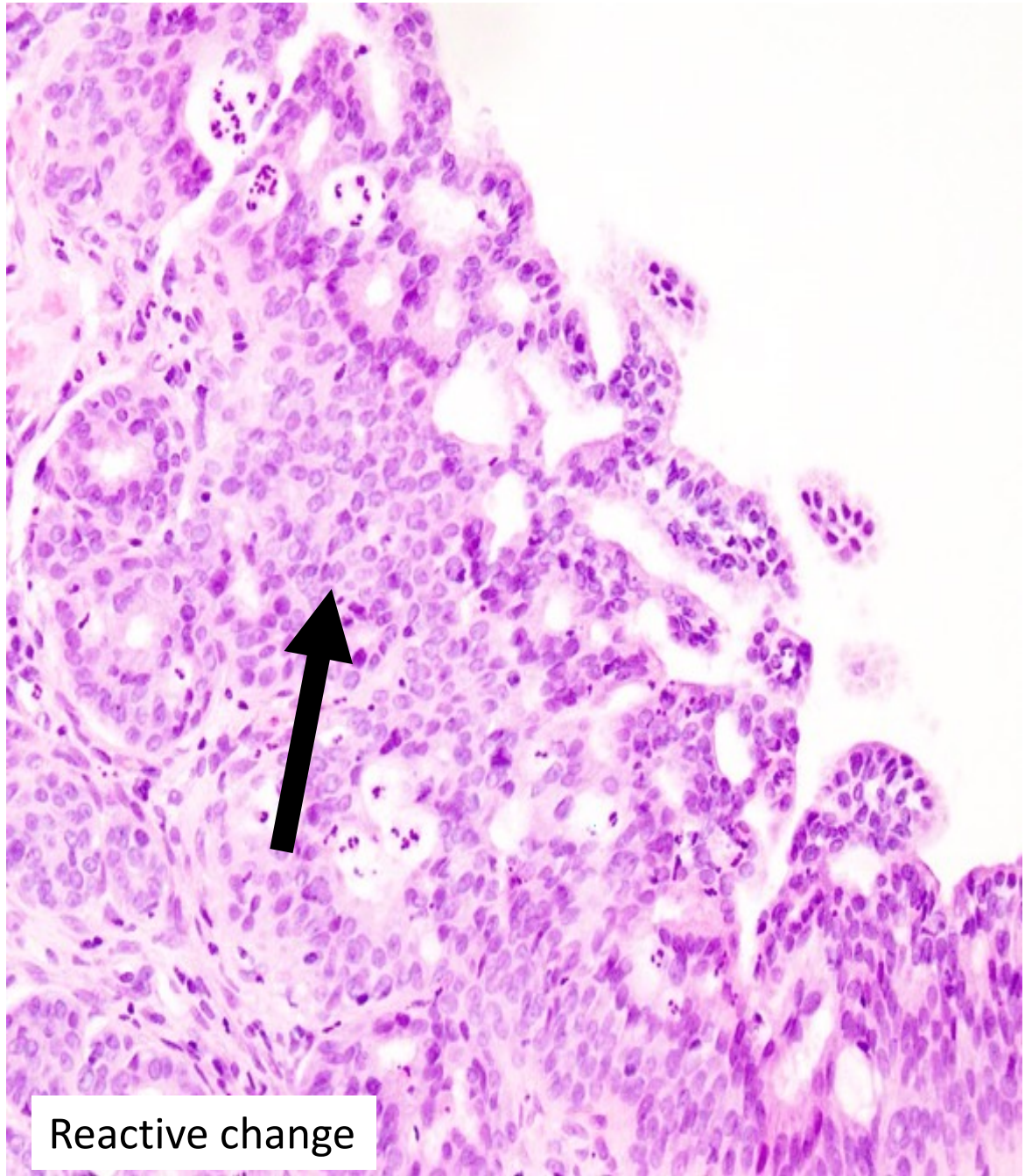
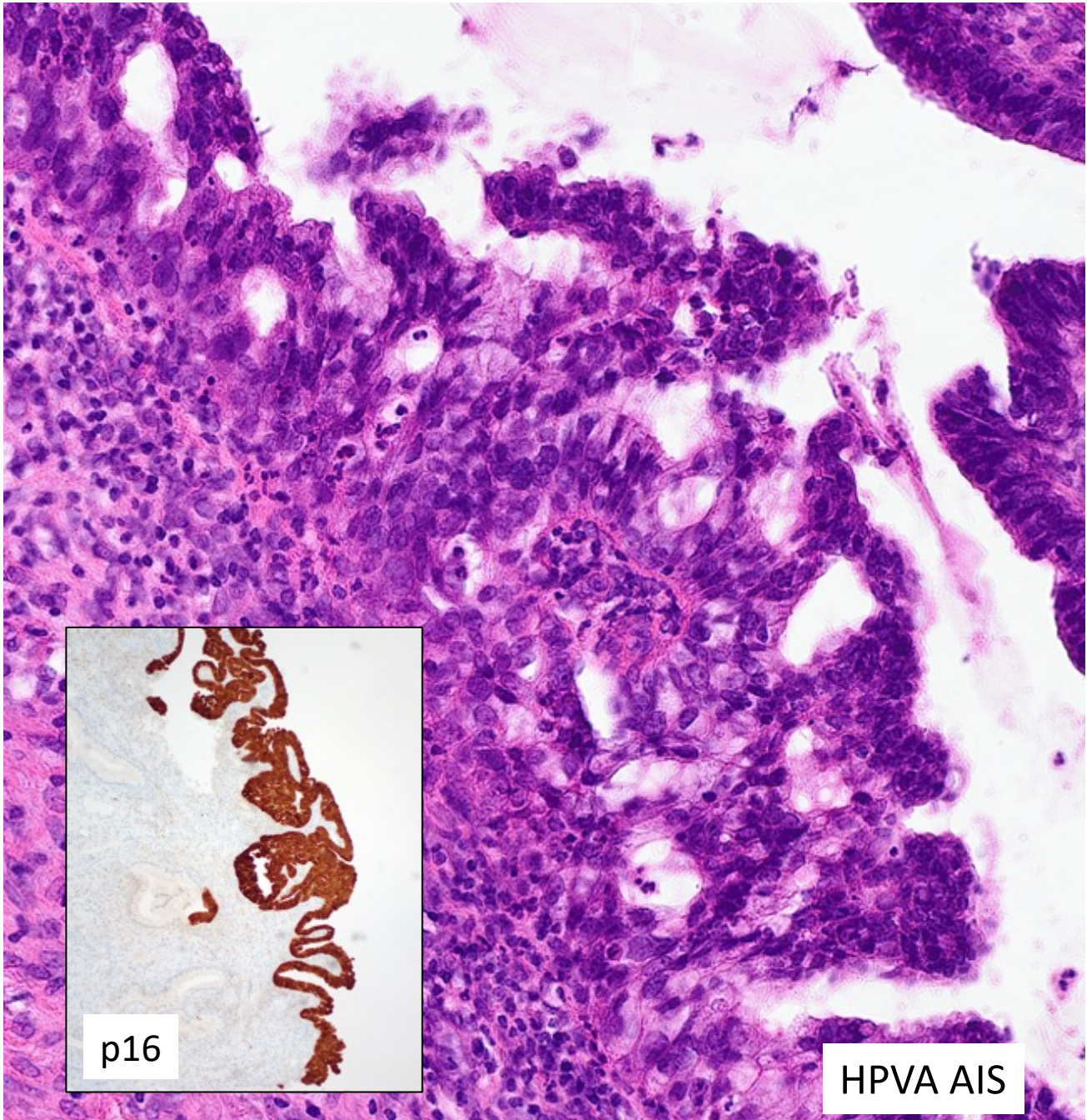
*Mod Pathol 2006;19:470-474*

Michael Scott<sup>1</sup>, Roy W Lyness<sup>2</sup> and W Glenn McCluggage<sup>1</sup>

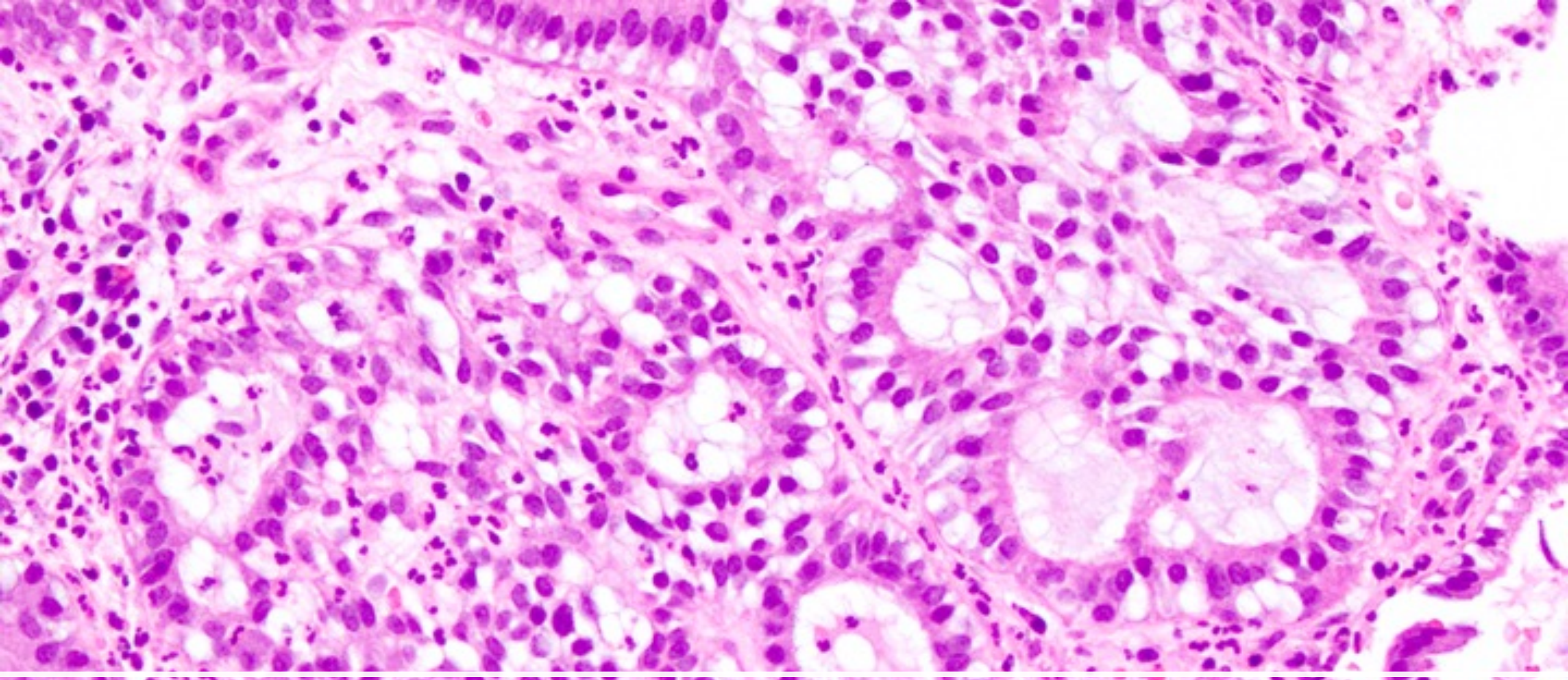








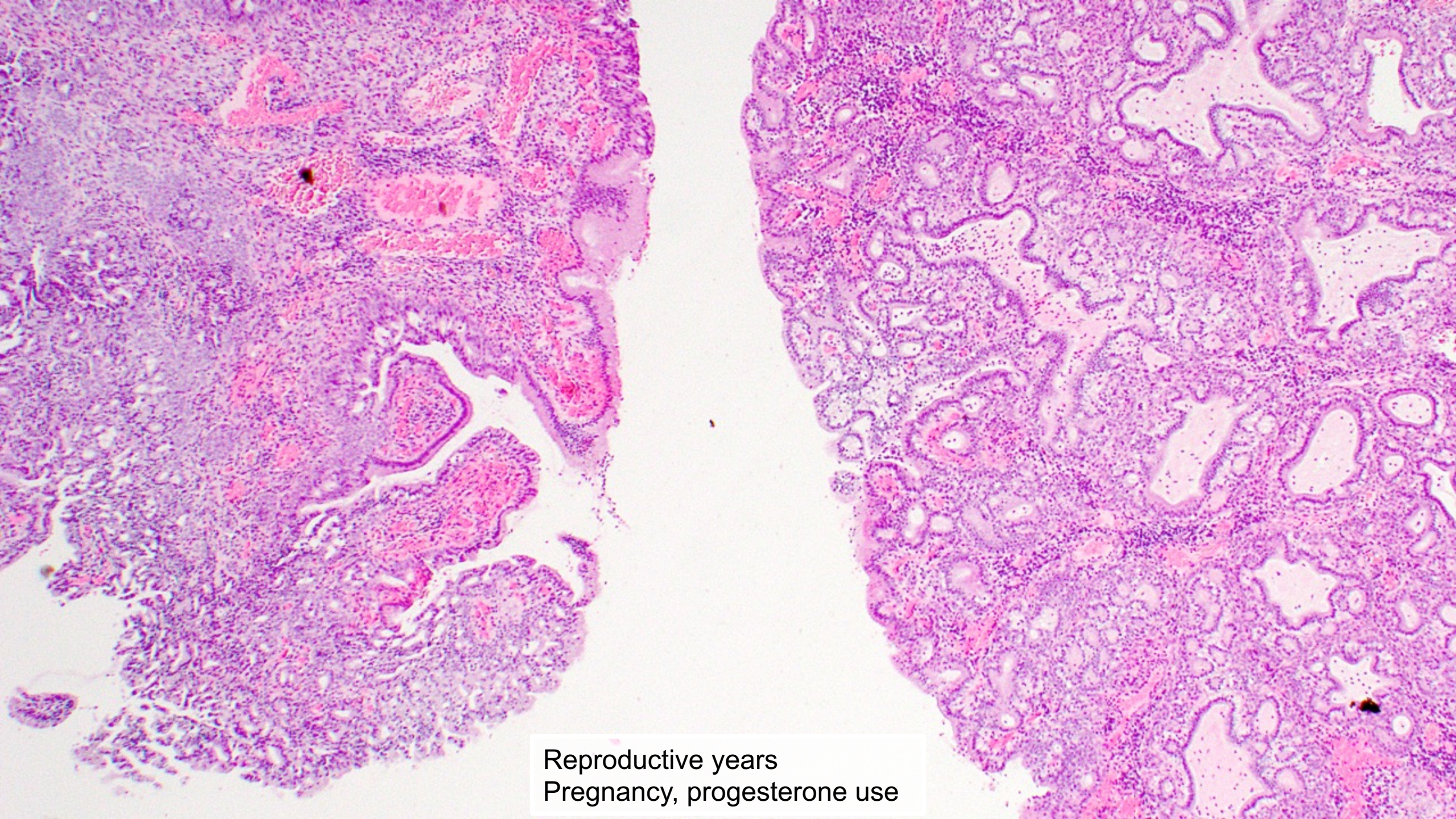



**Microglandular hyperplasia**

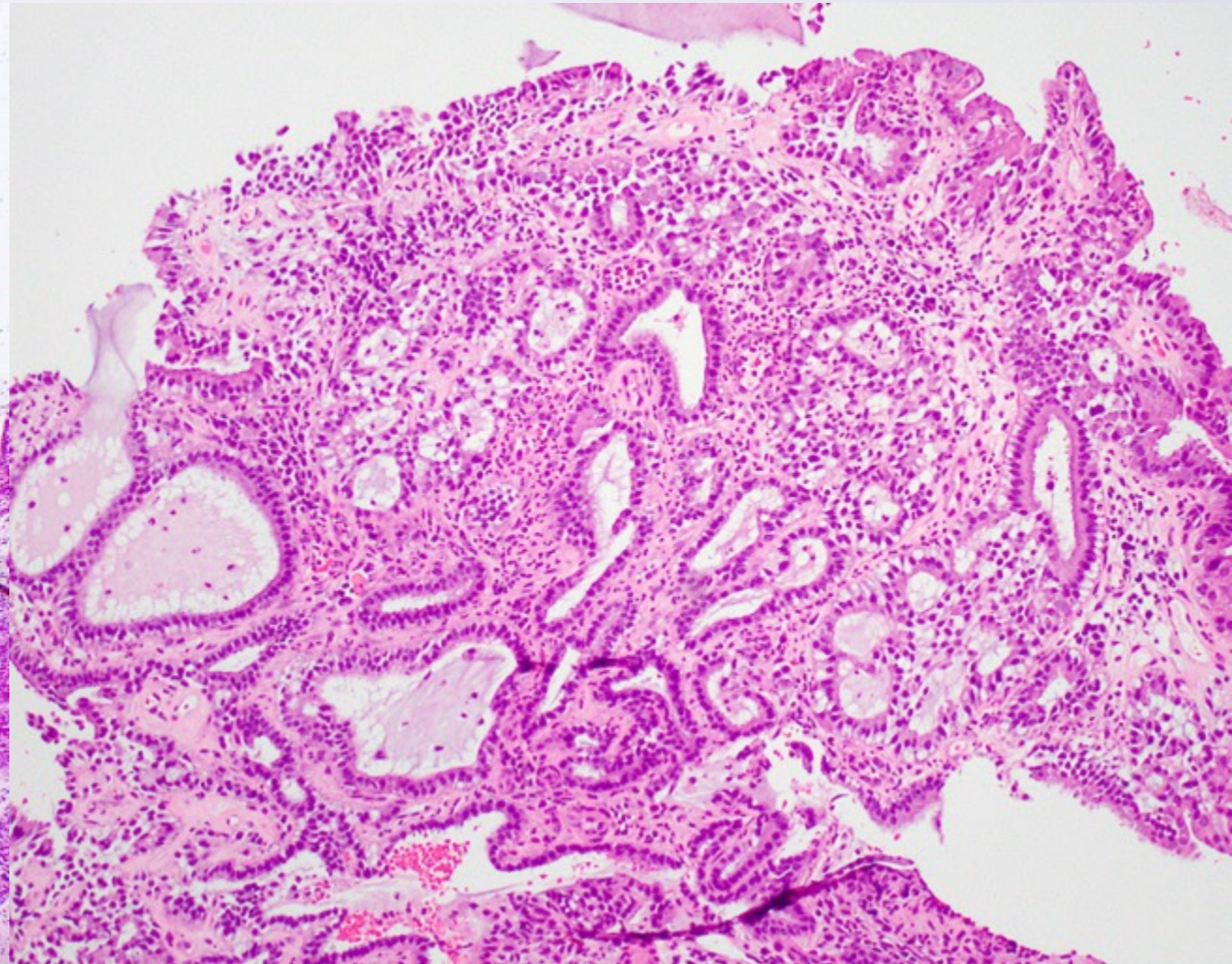
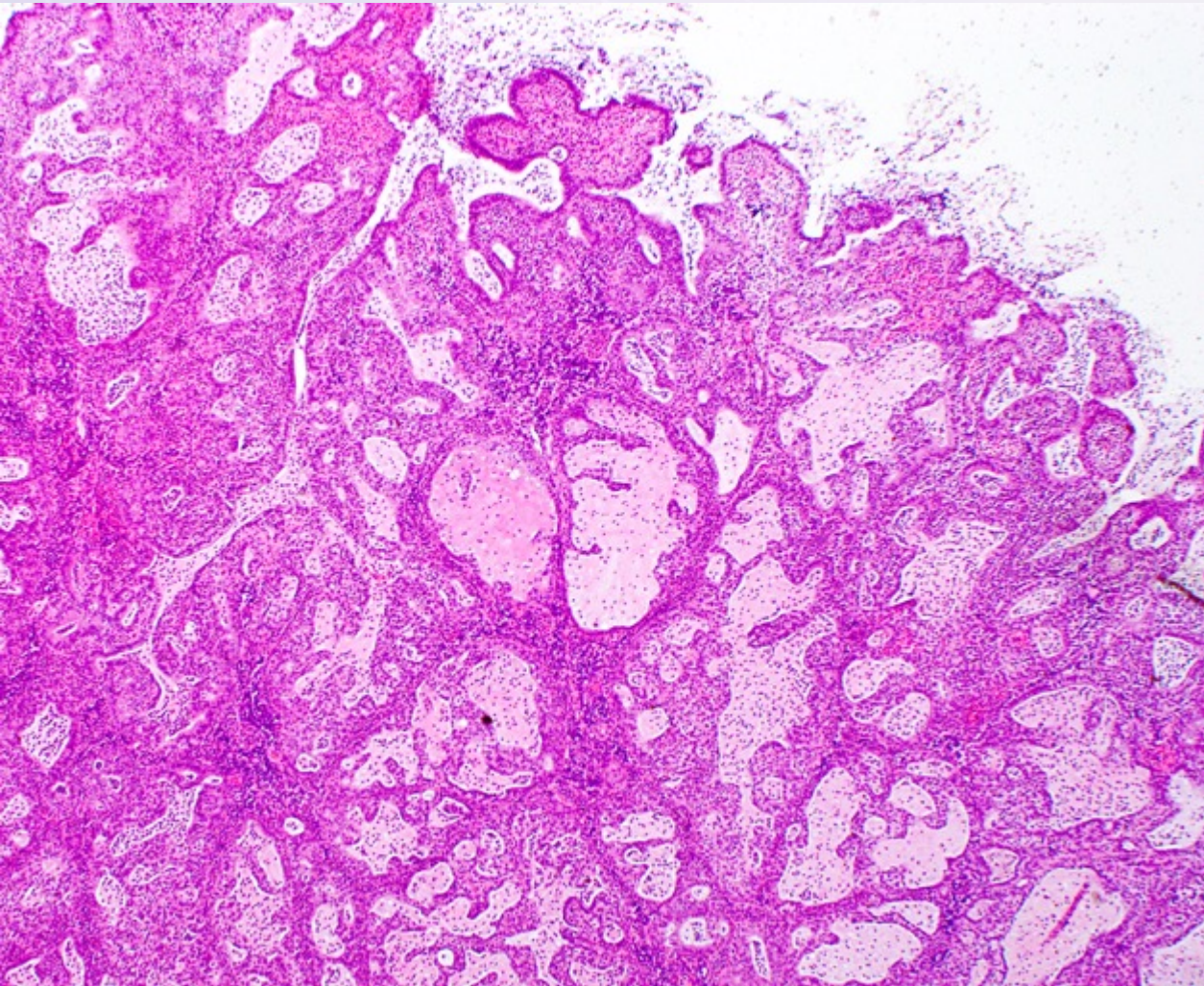




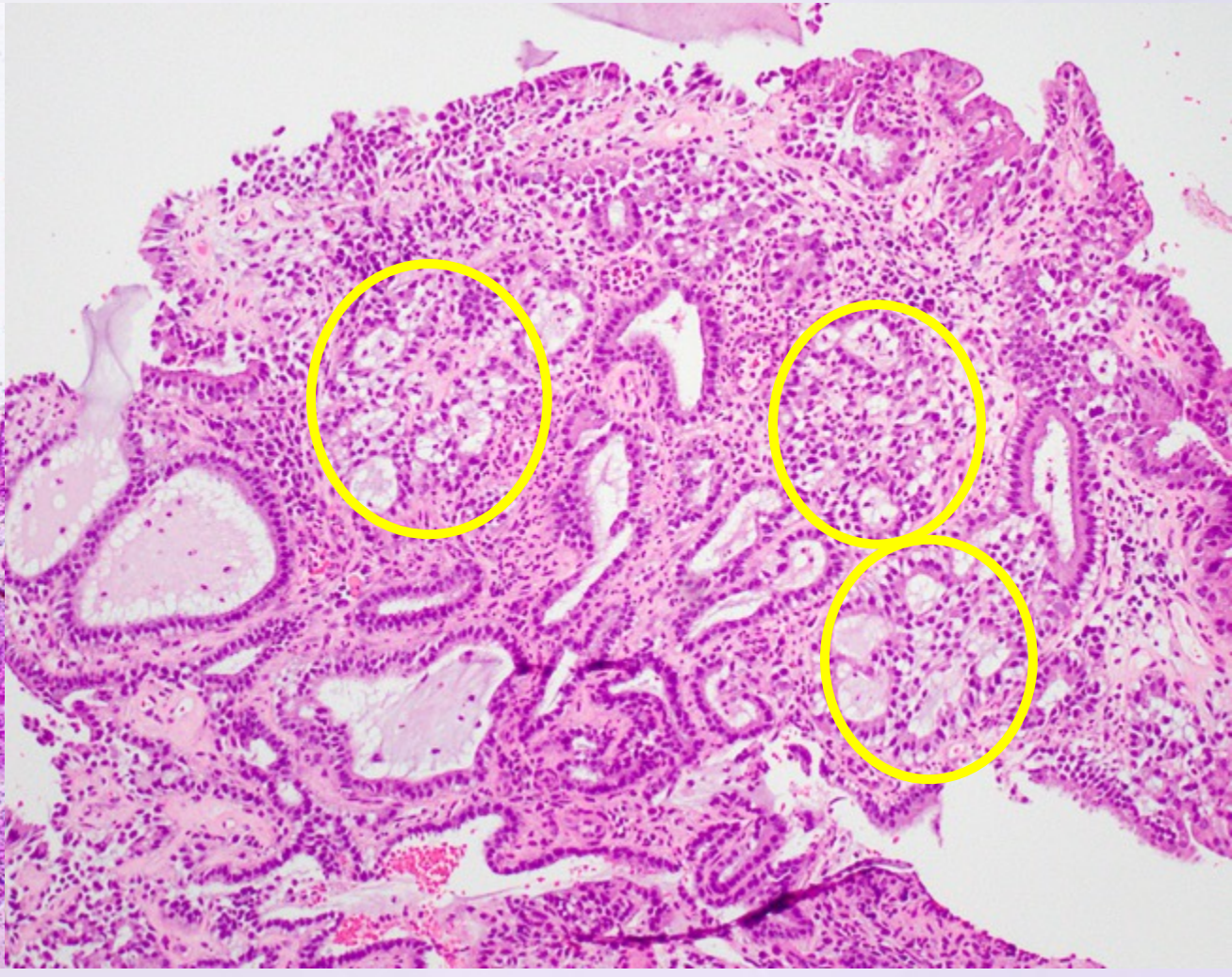
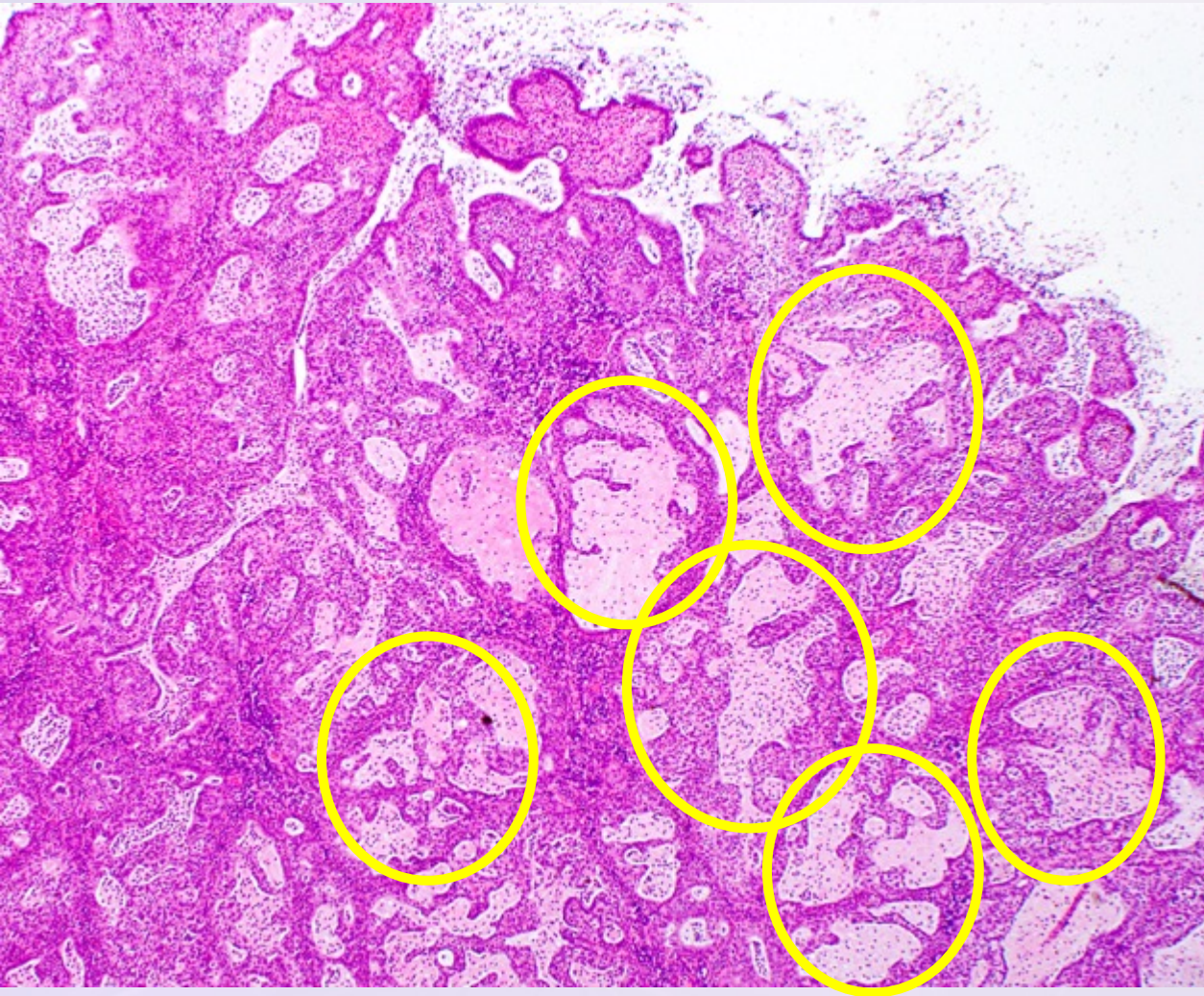


Reproductive years  
Pregnancy, progesterone use

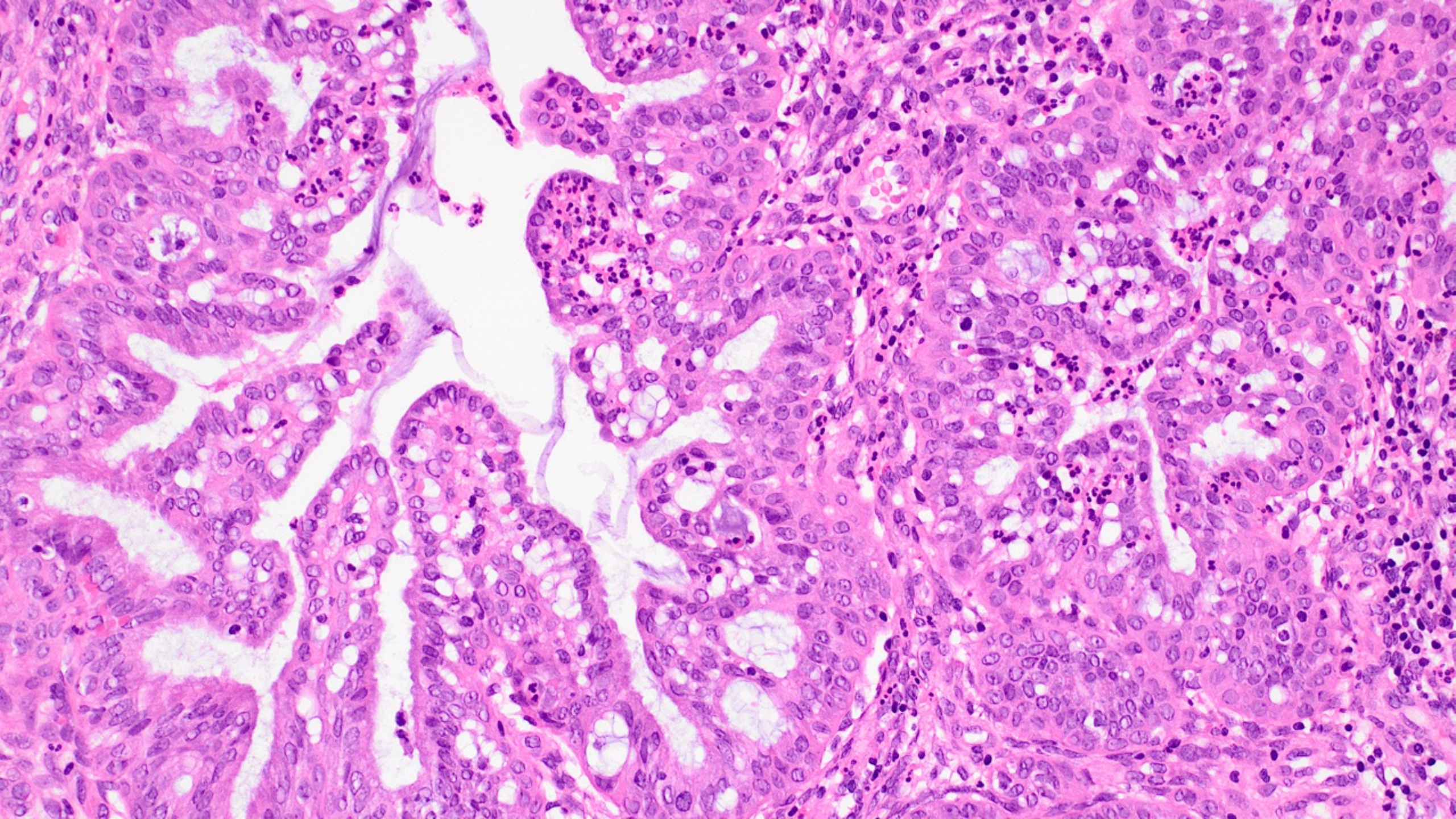




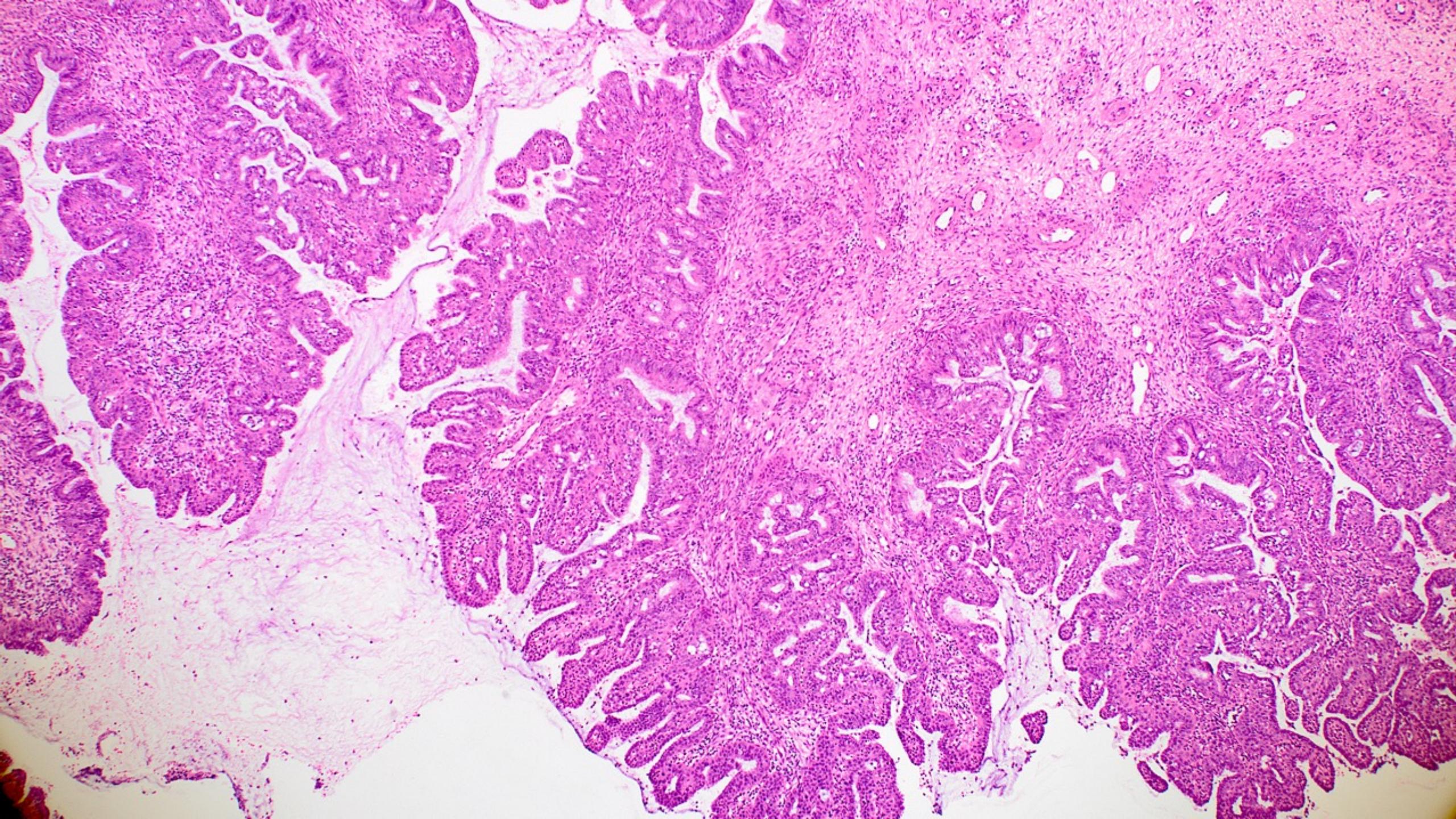




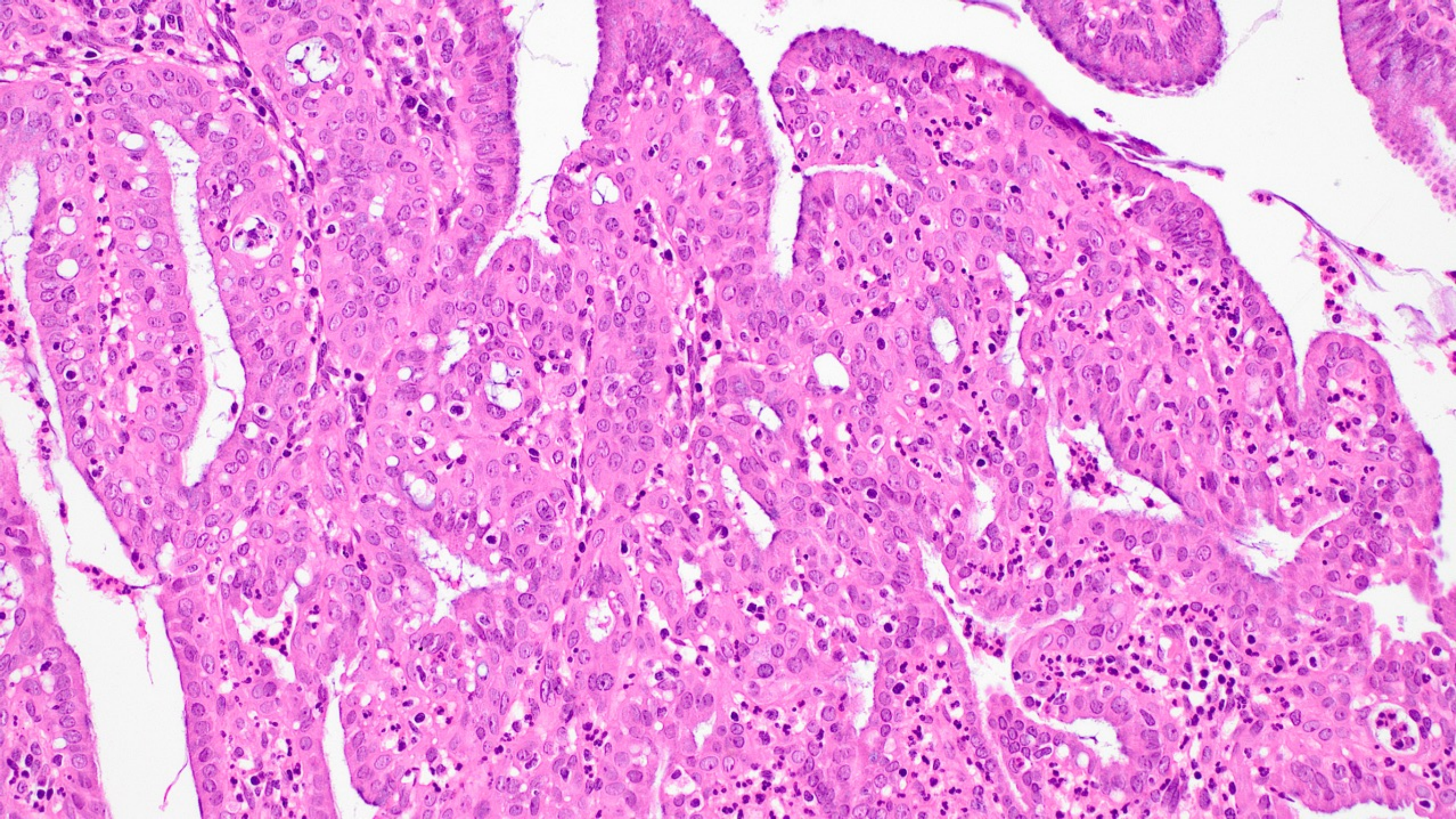




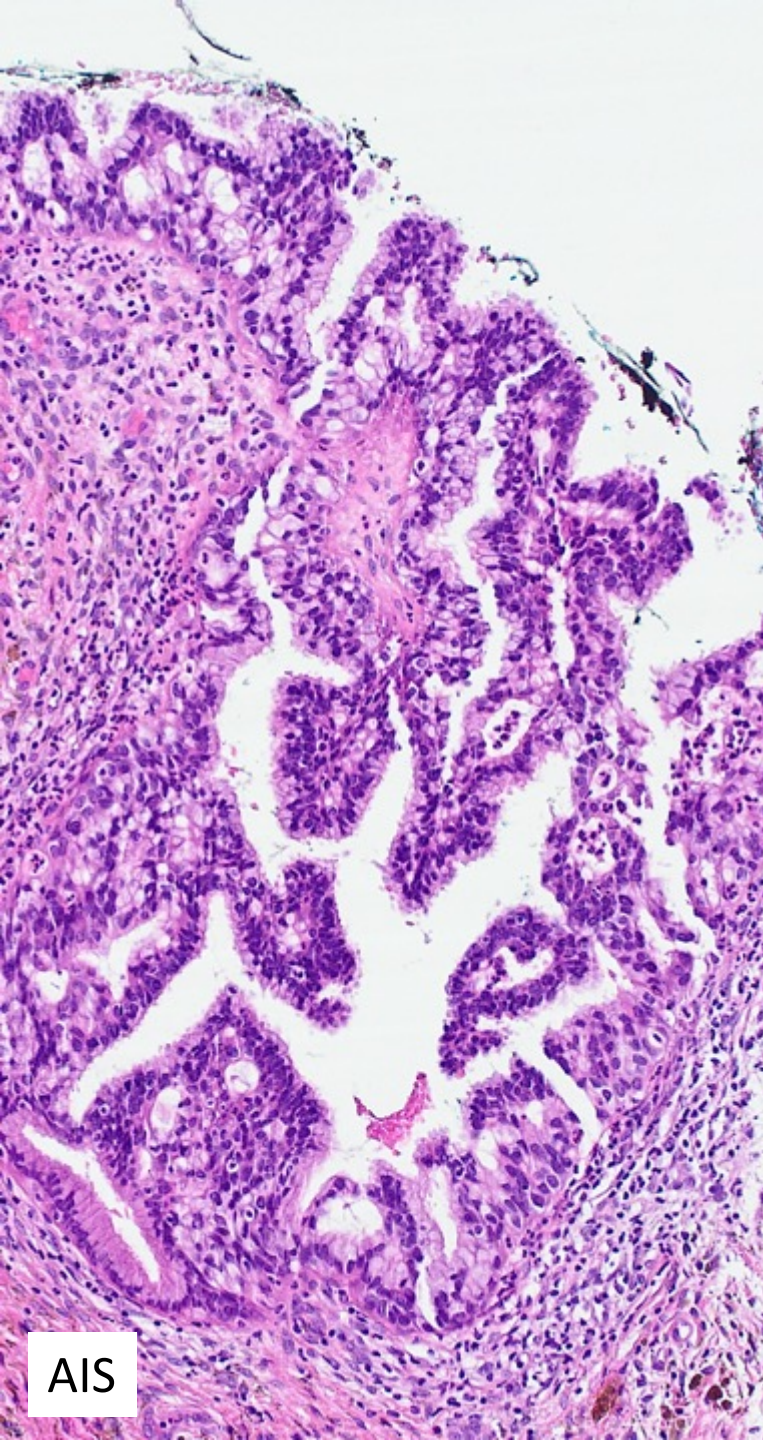




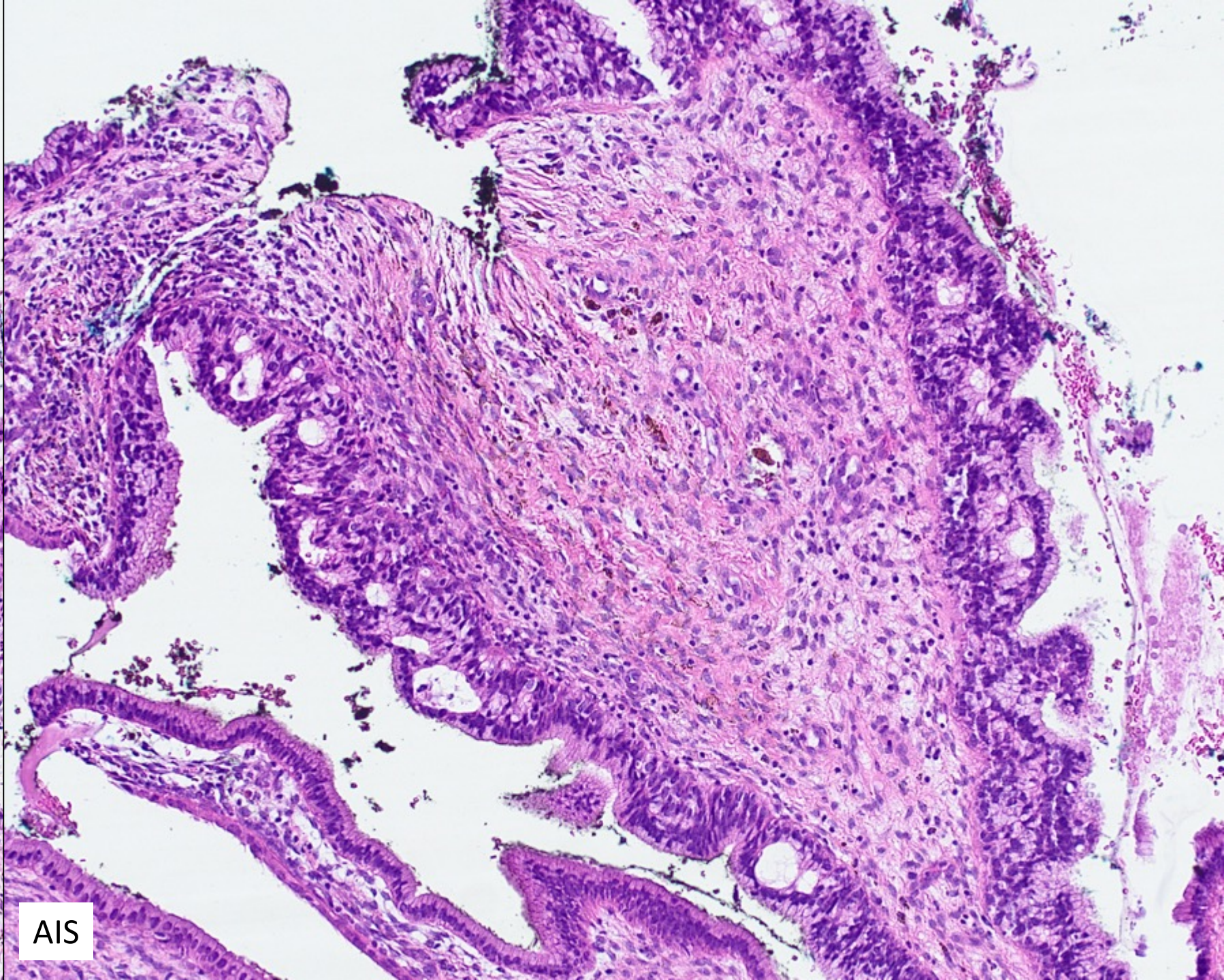






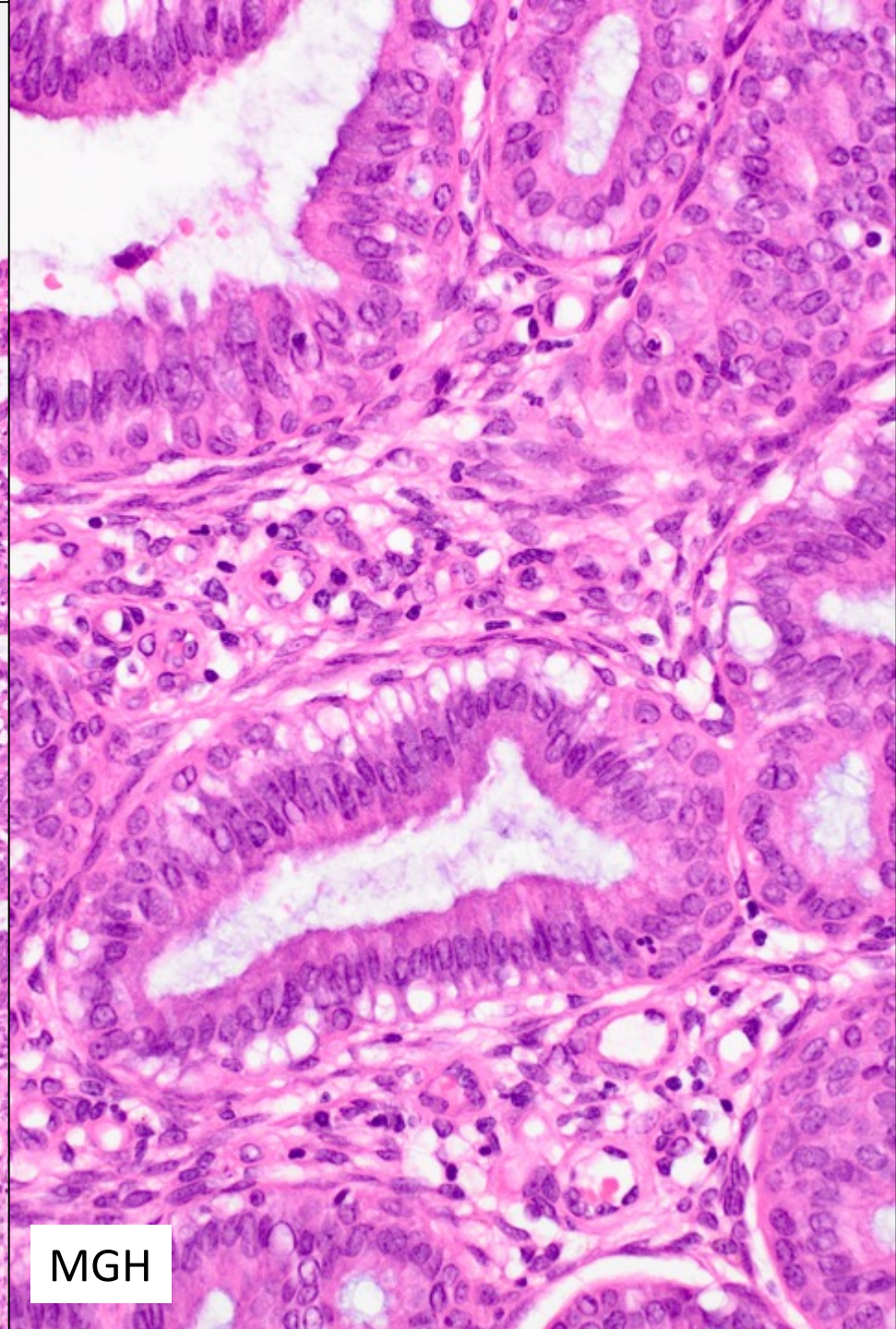
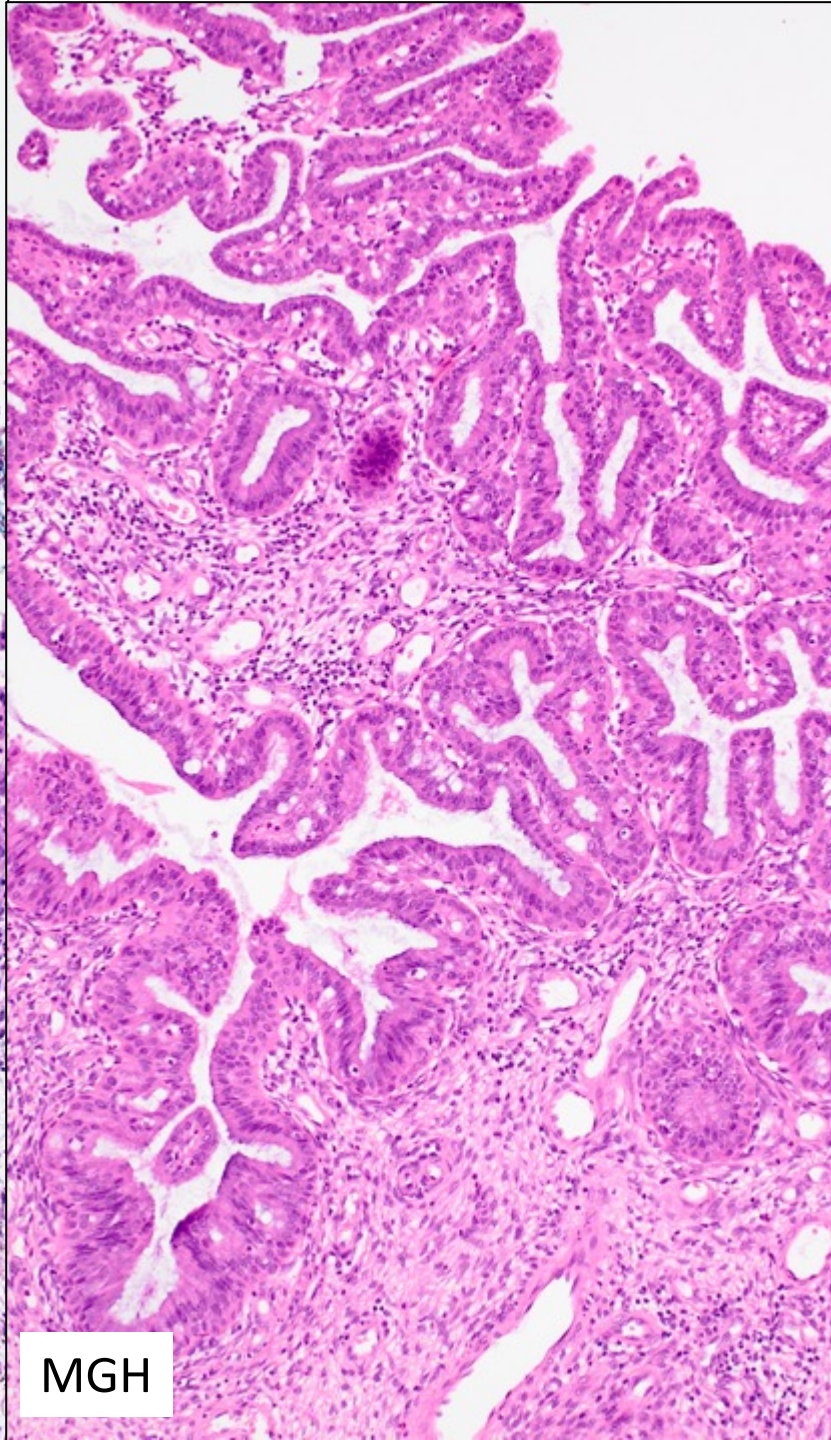
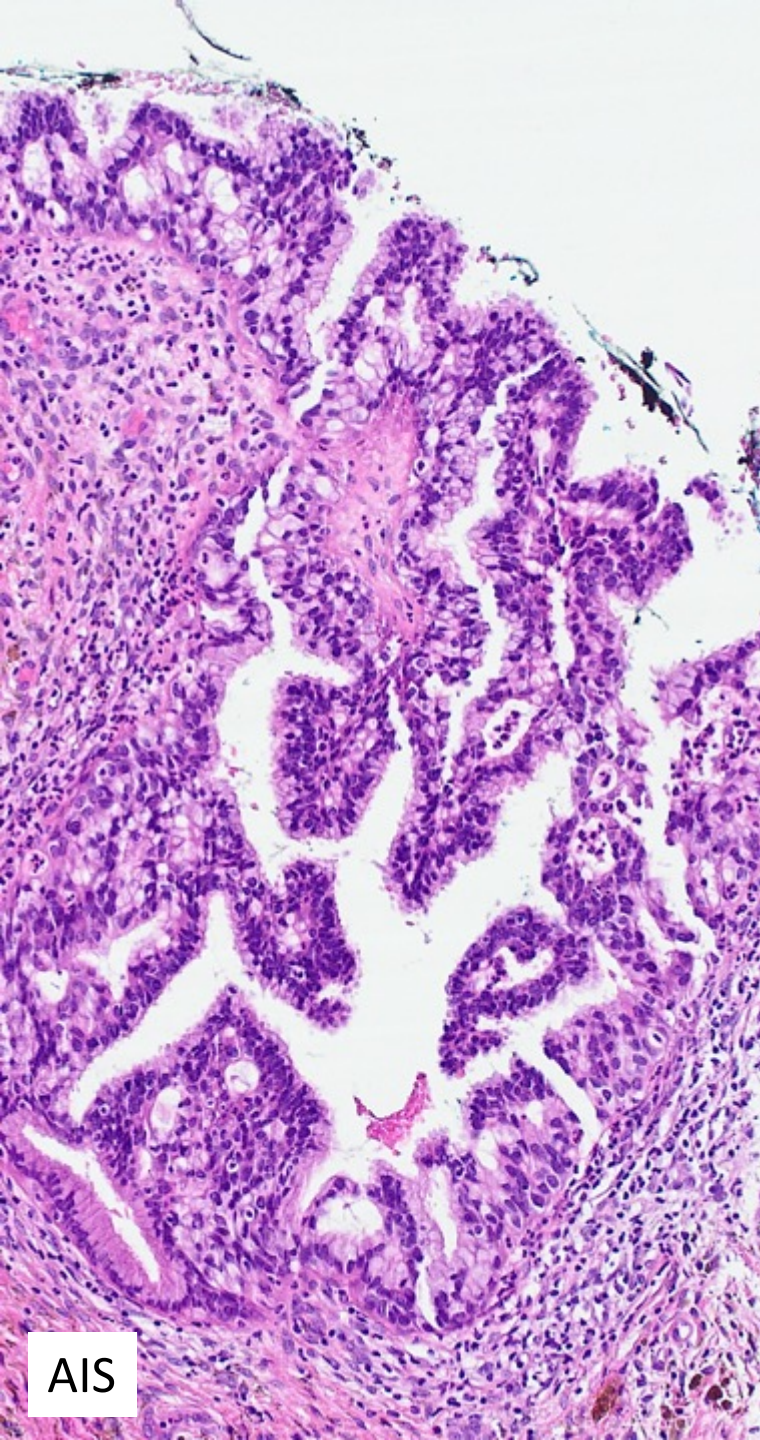


AIS

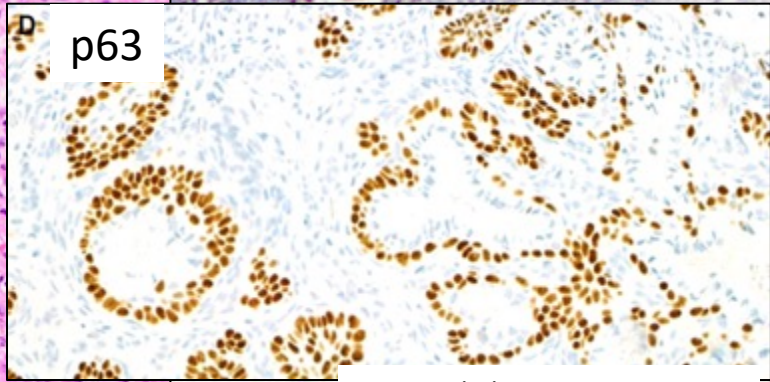
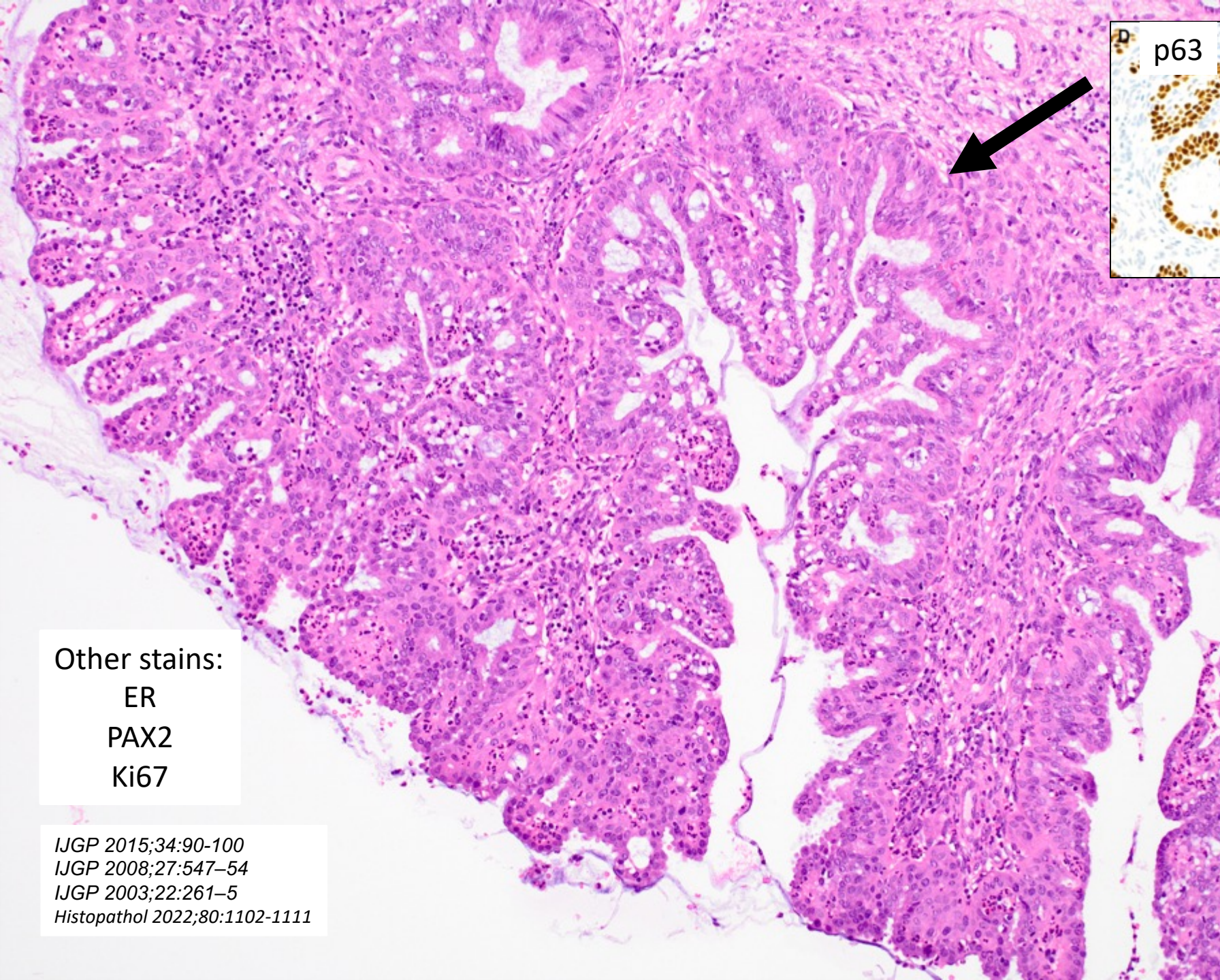


AIS





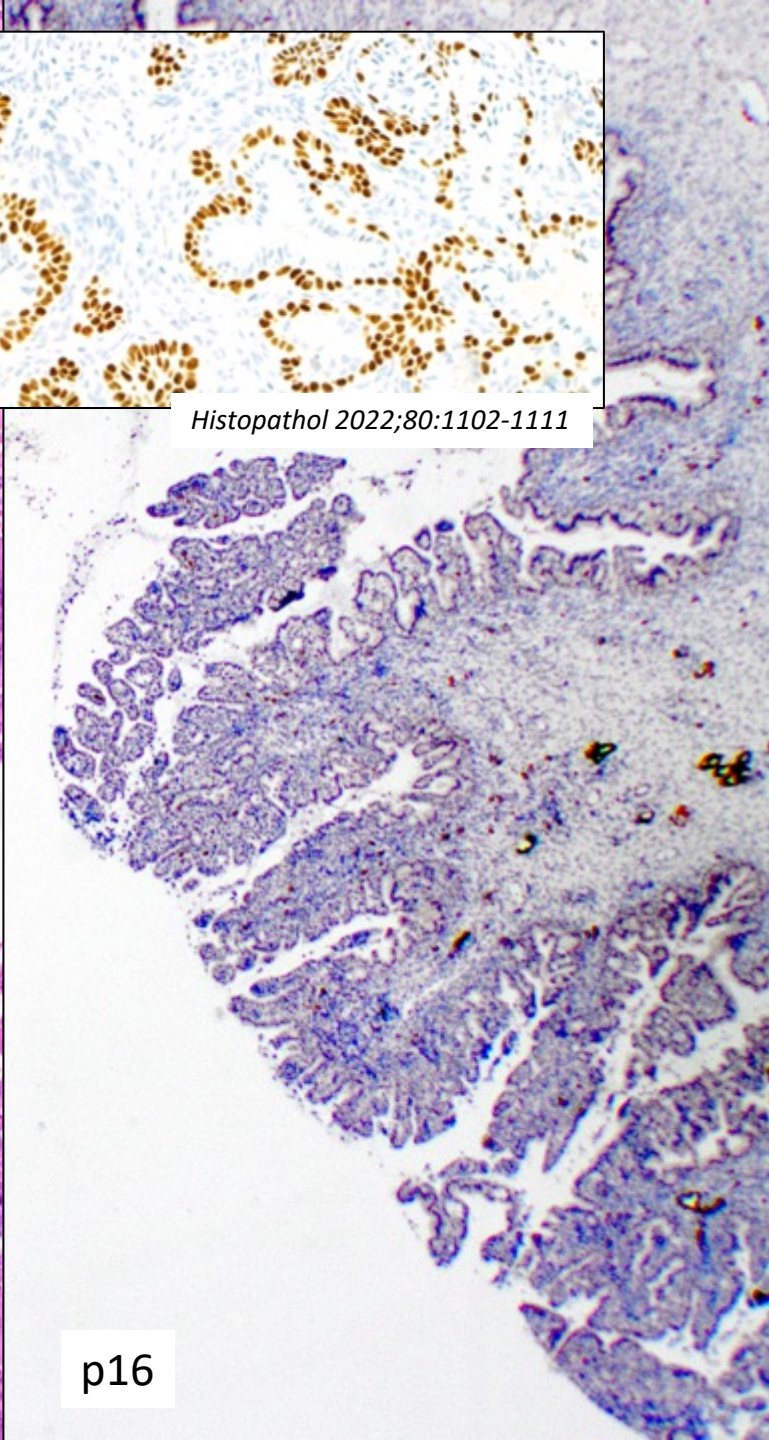




*Histopathol 2022;80:1102-1111*

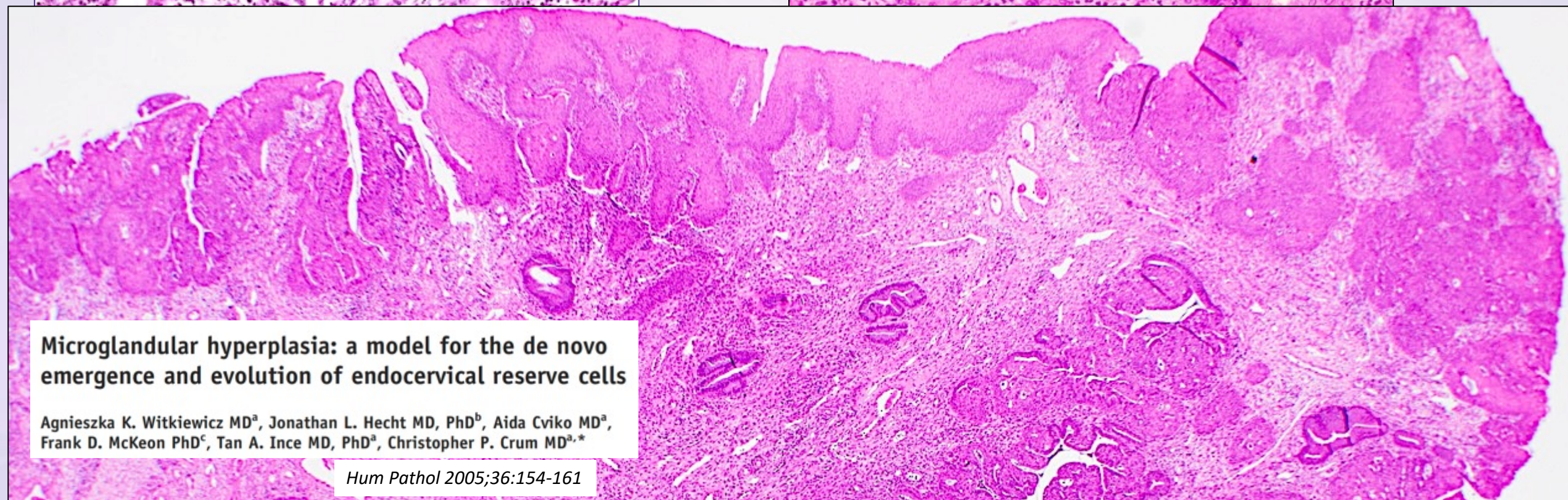
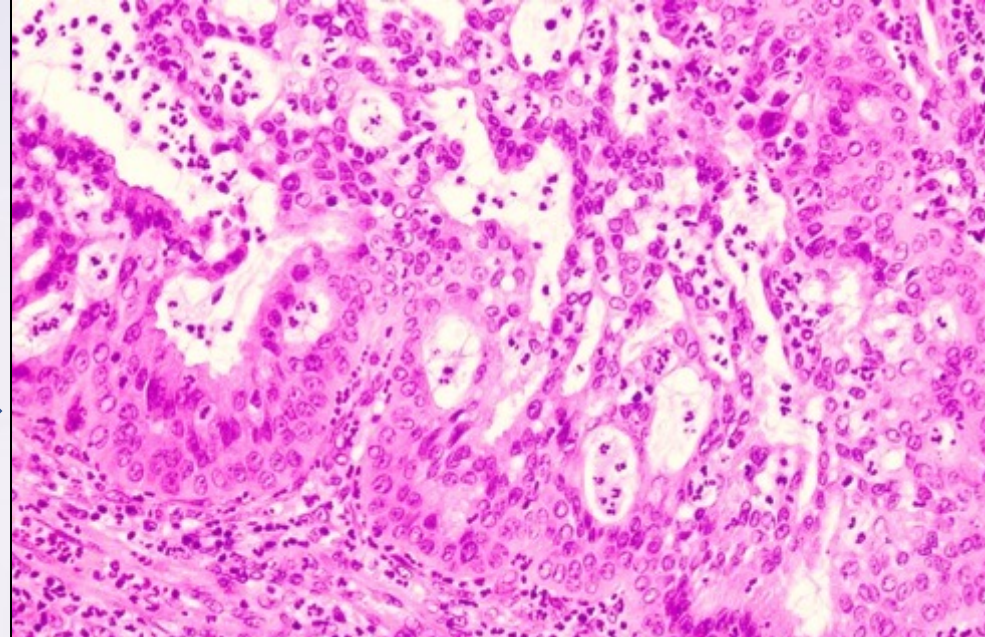

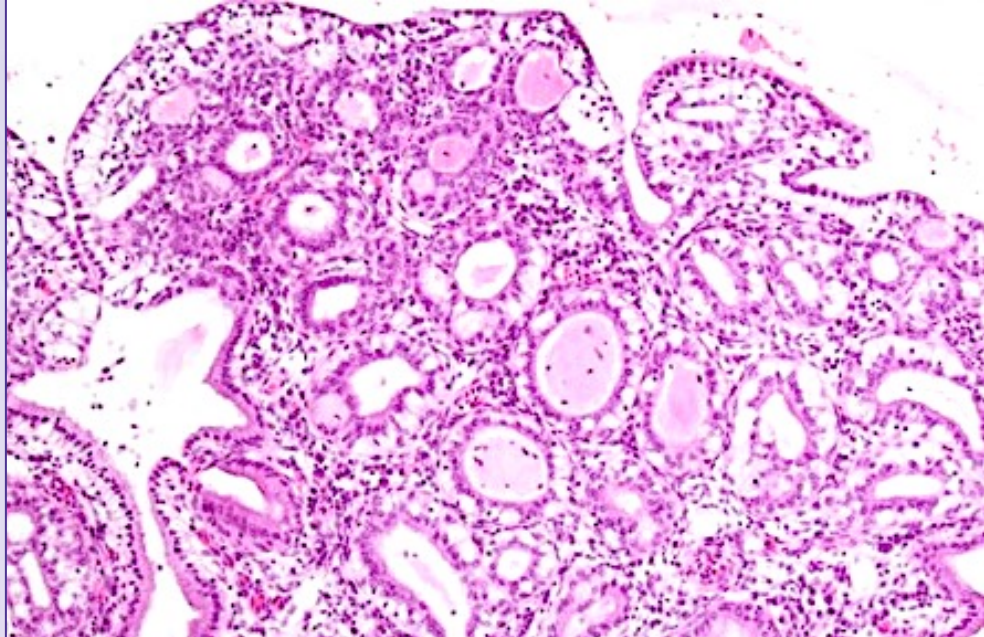
Other stains:  
ER  
PAX2  
Ki67

*IJGP 2015;34:90-100*  
*IJGP 2008;27:547-54*  
*IJGP 2003;22:261-5*  
*Histopathol 2022;80:1102-1111*



p16



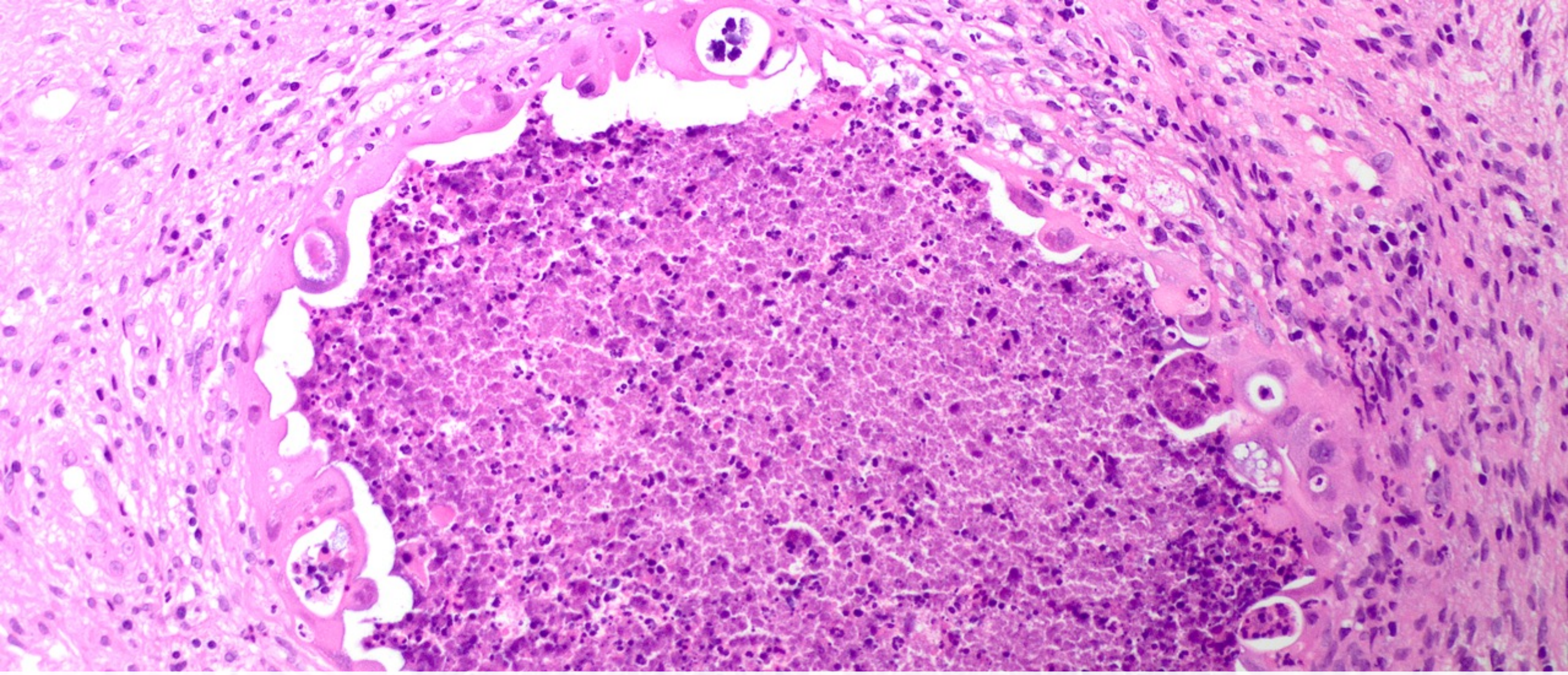


**Microglandular hyperplasia: a model for the de novo emergence and evolution of endocervical reserve cells**

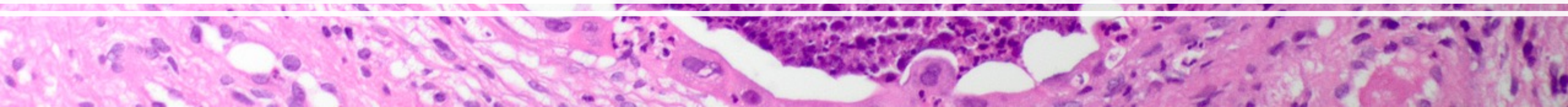
Agnieszka K. Witkiewicz MD<sup>a</sup>, Jonathan L. Hecht MD, PhD<sup>b</sup>, Aida Cviko MD<sup>a</sup>, Frank D. McKeon PhD<sup>c</sup>, Tan A. Ince MD, PhD<sup>a</sup>, Christopher P. Crum MD<sup>a,\*</sup>

*Hum Pathol* 2005;36:154-161





**Radiation atypia – potential pitfall**

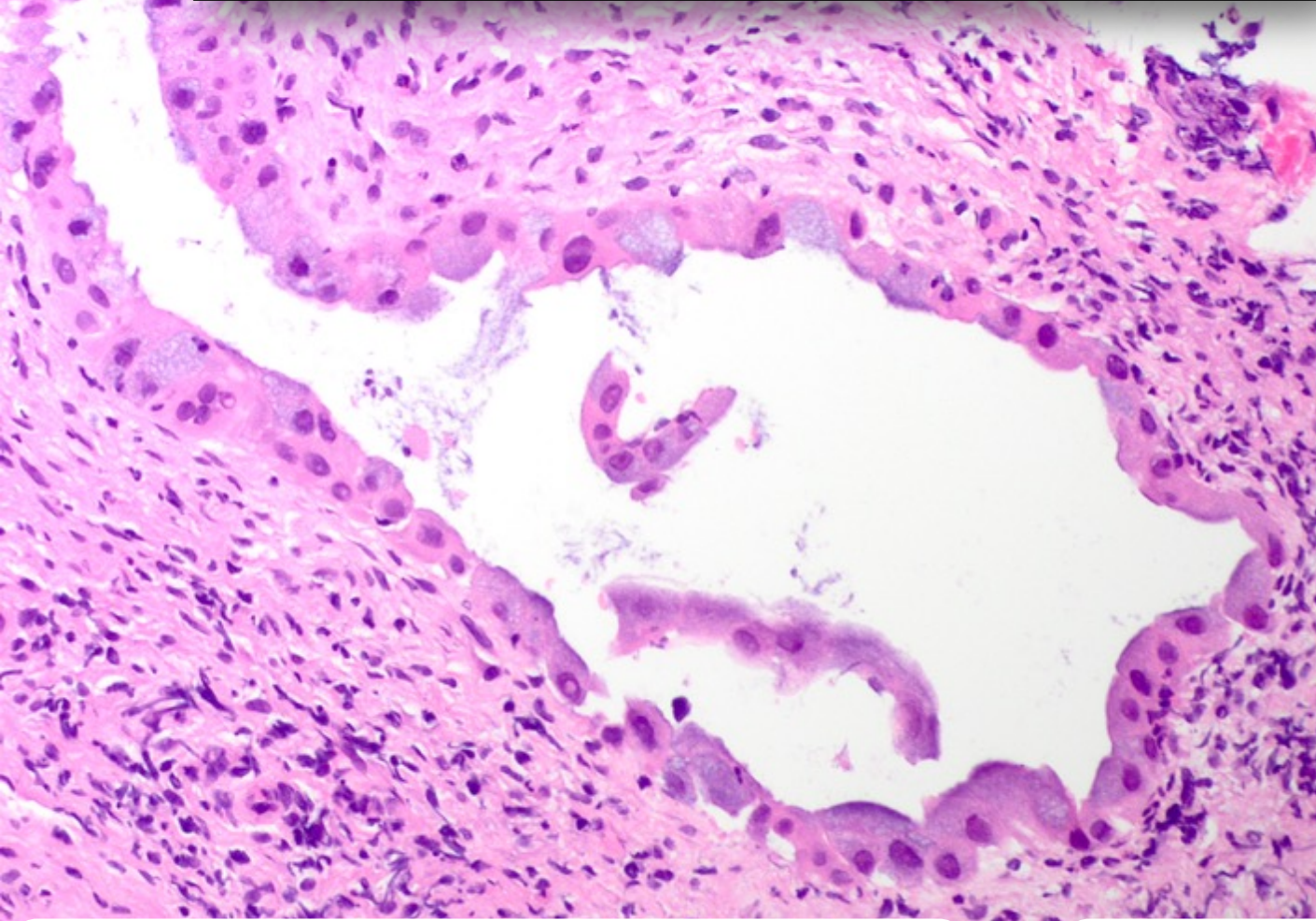




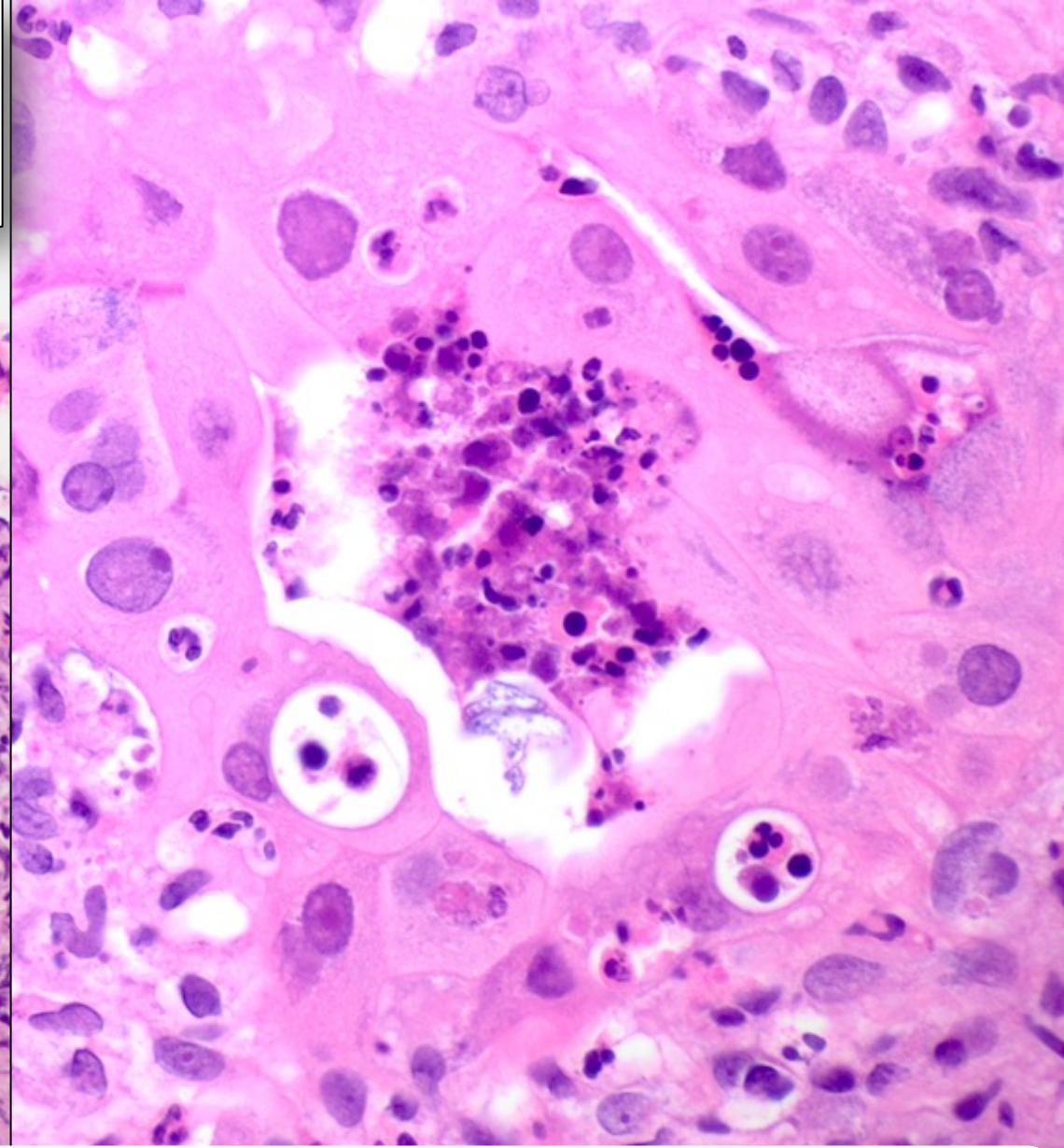
**Radiation-Induced Atypia of Endocervical Epithelium: A  
Histological, Immunohistochemical and Cytometric Study**

*IJGP 1996;15:242-247*

David Lesack, M.D., Ibrahim Wahab, Ph.D., and C. Blake Gilks, M.D.

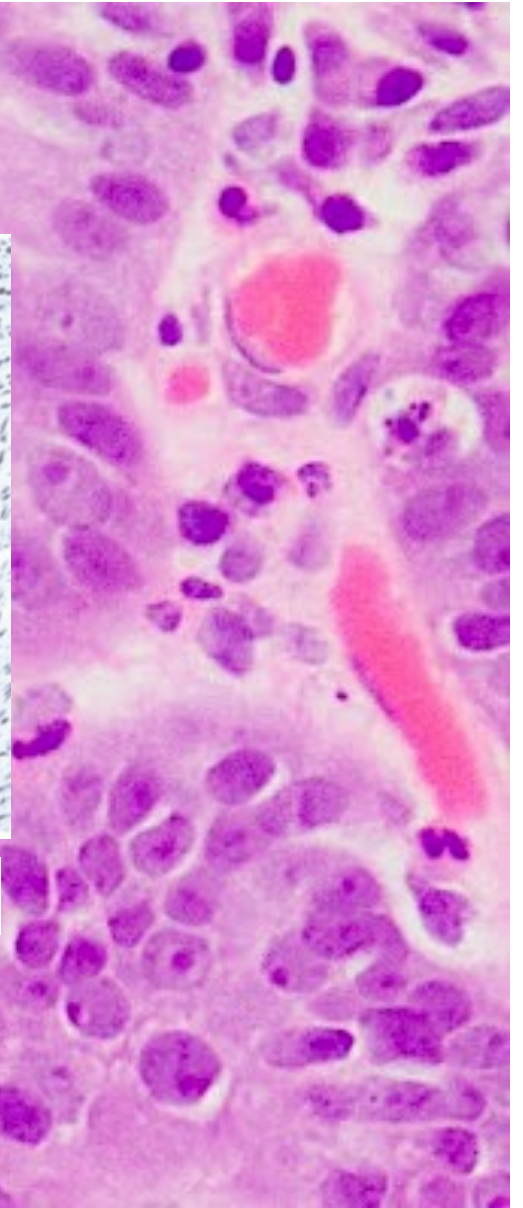
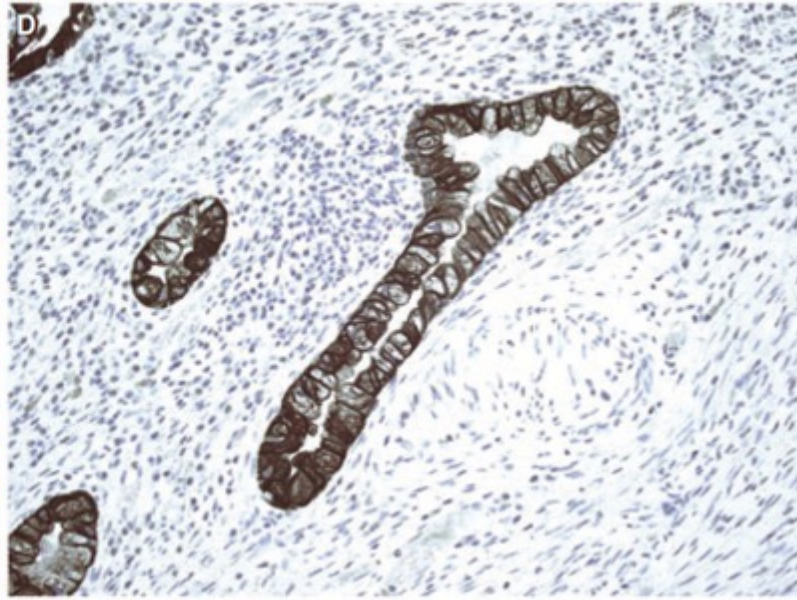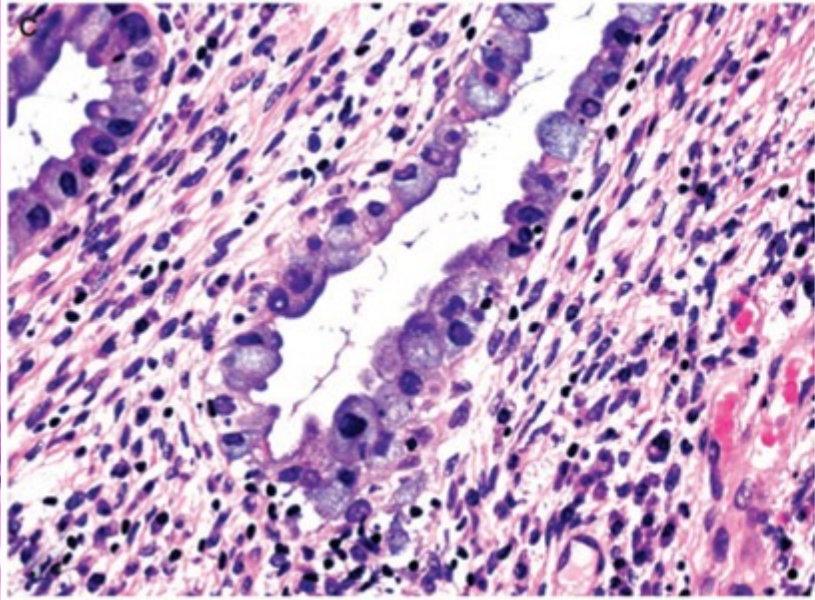
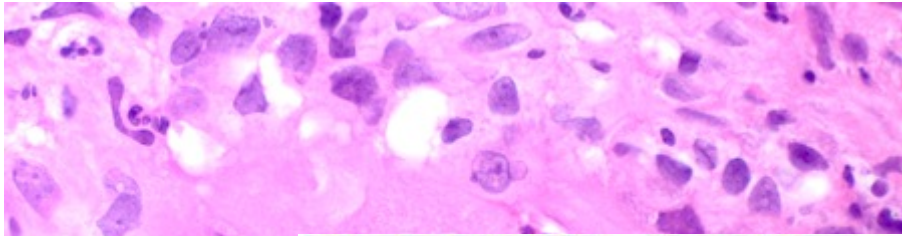


Fewer glands, simplified architecture  
Epithelium cuboidal/flattened

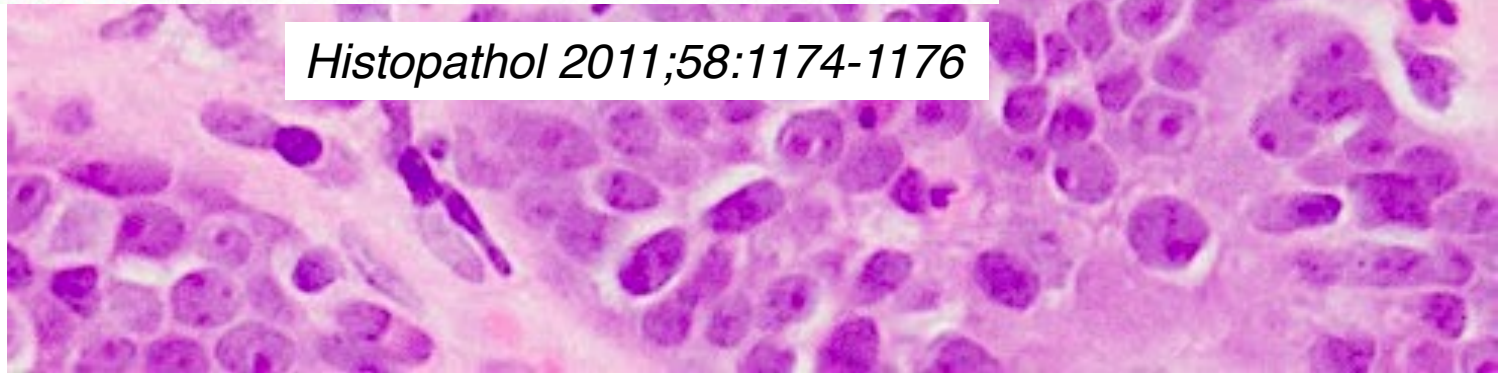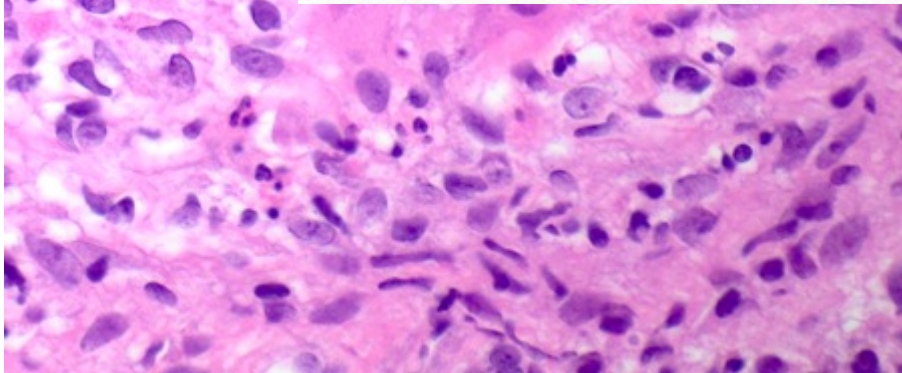


Large cells, low NCR, dense pink cytoplasm  
Central nuclei, smudged chromatin, nucleoli. No mitoses





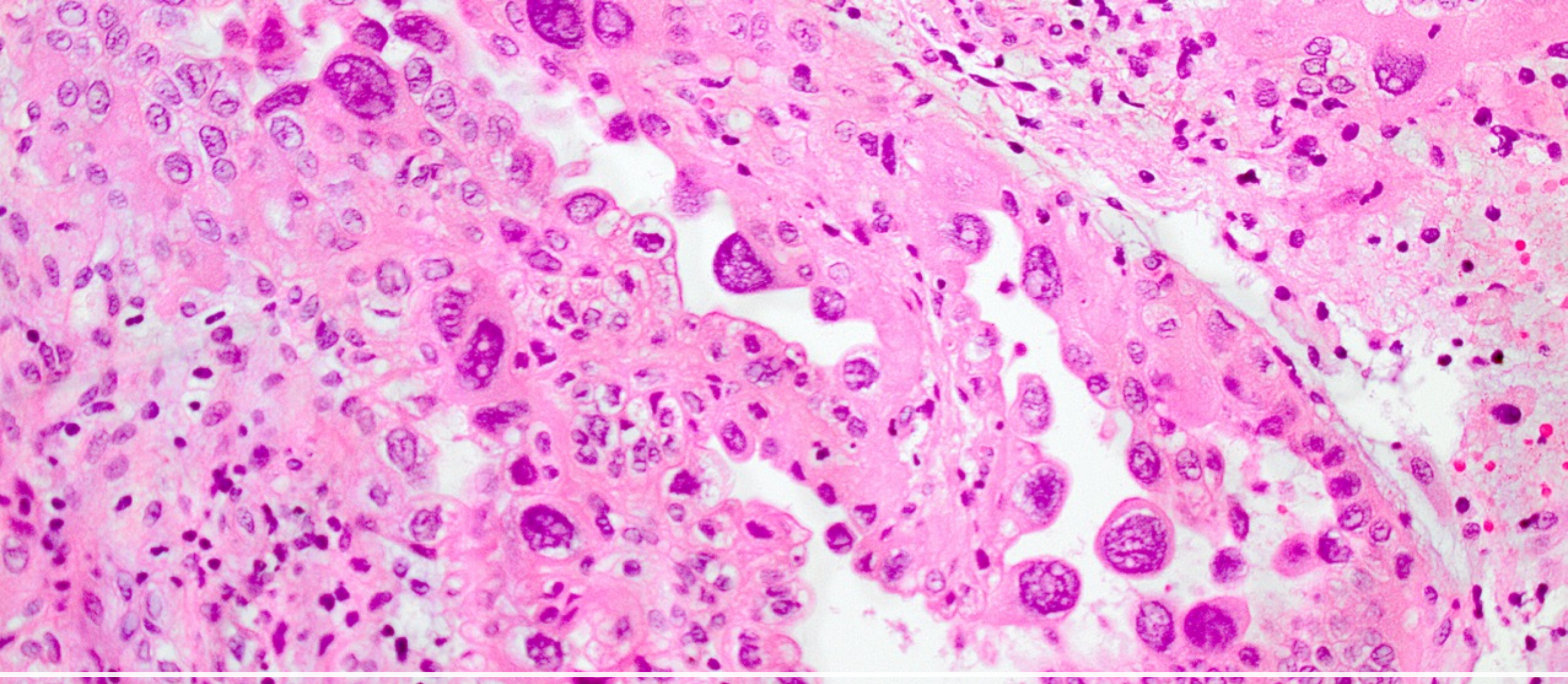
*Histopathol 2011;58:1174-1176*



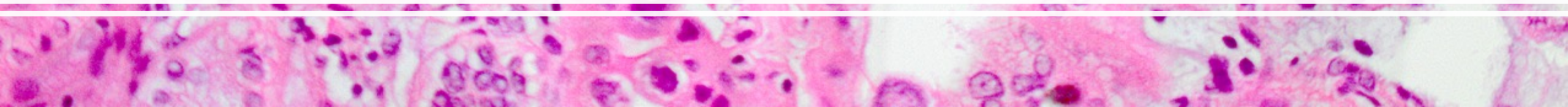Radiation atypia

HPVA AIS





**Arias-Stella effect**





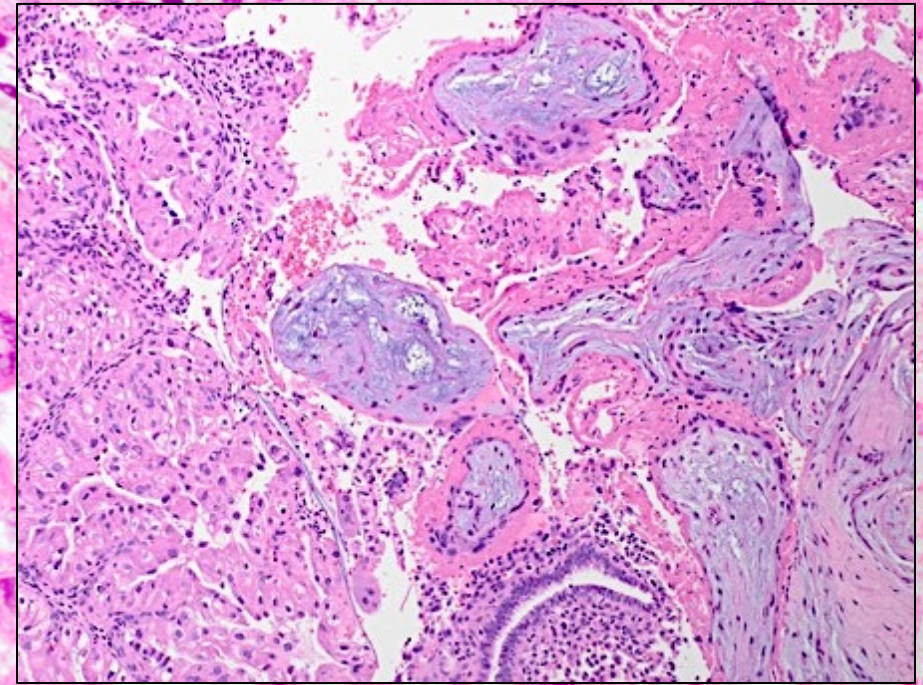
## CONTEXT is key

Pregnancy / high dose P2 / GTD  
10% of gravid cervixes

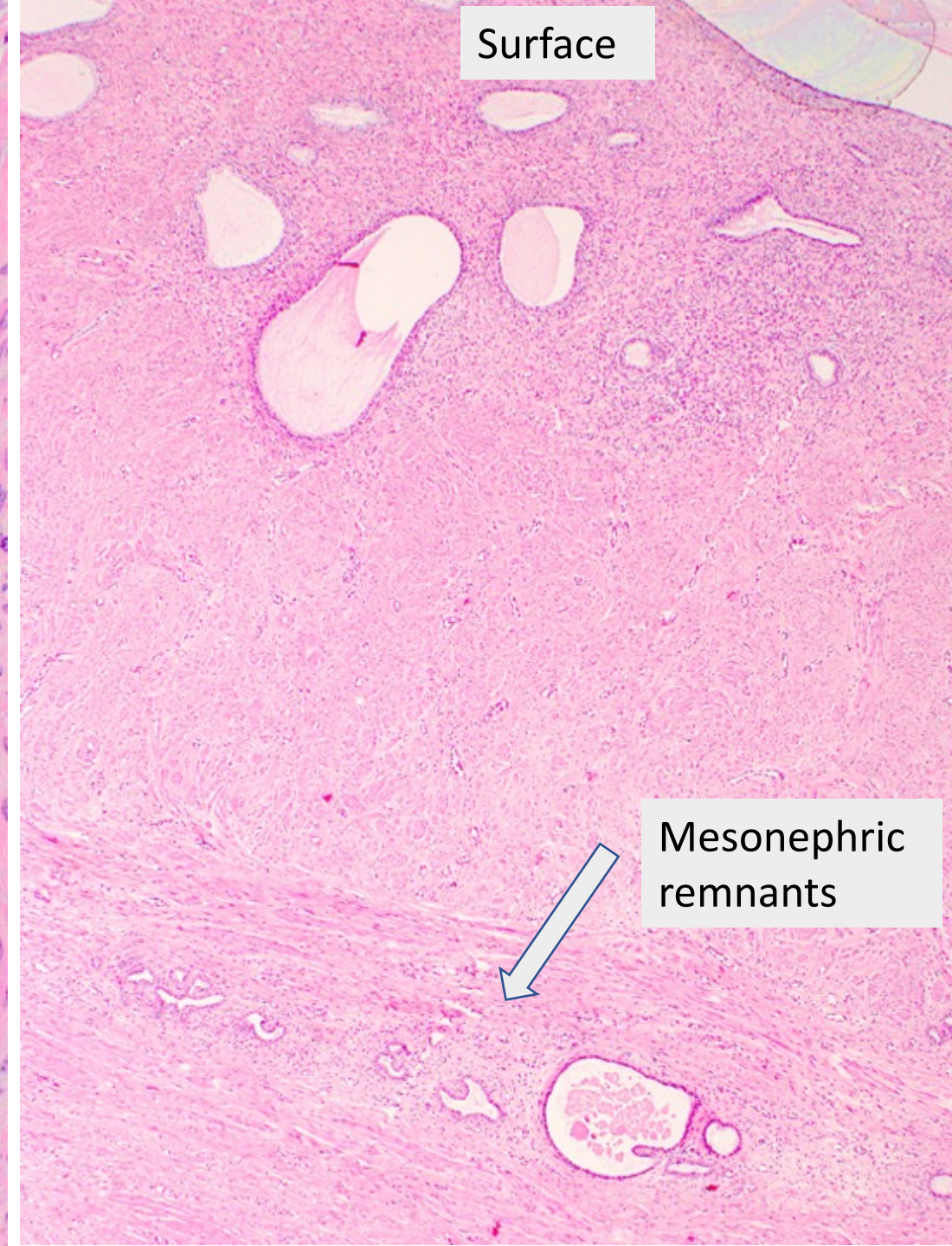
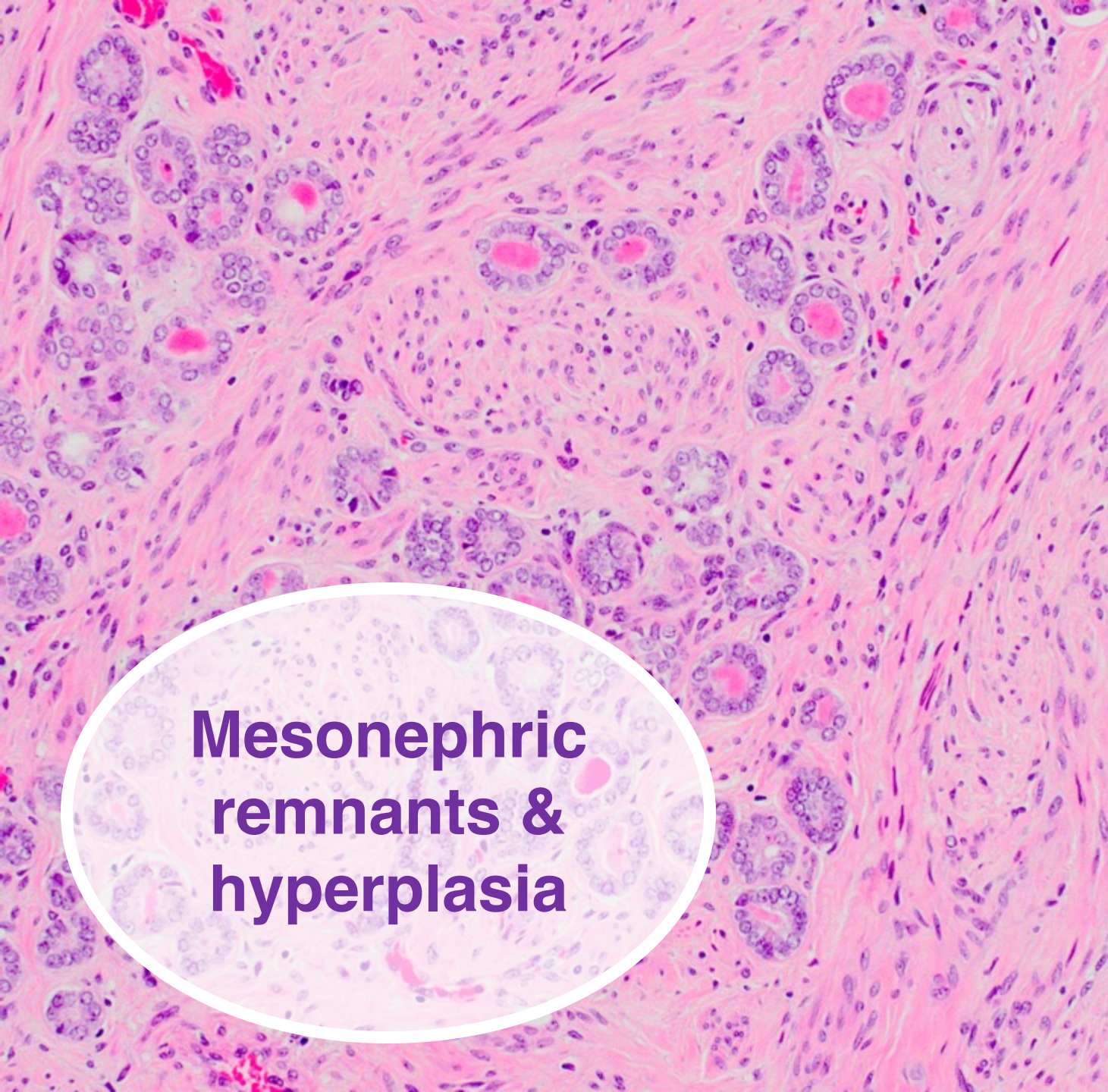
- Marked atypia
- Smudged chromatin
- Nuclear inclusions
- Hobnail appearance
- Vacuolated cytoplasm

*Preserved N:C ratio*  
*Rare mitoses, apoptoses*

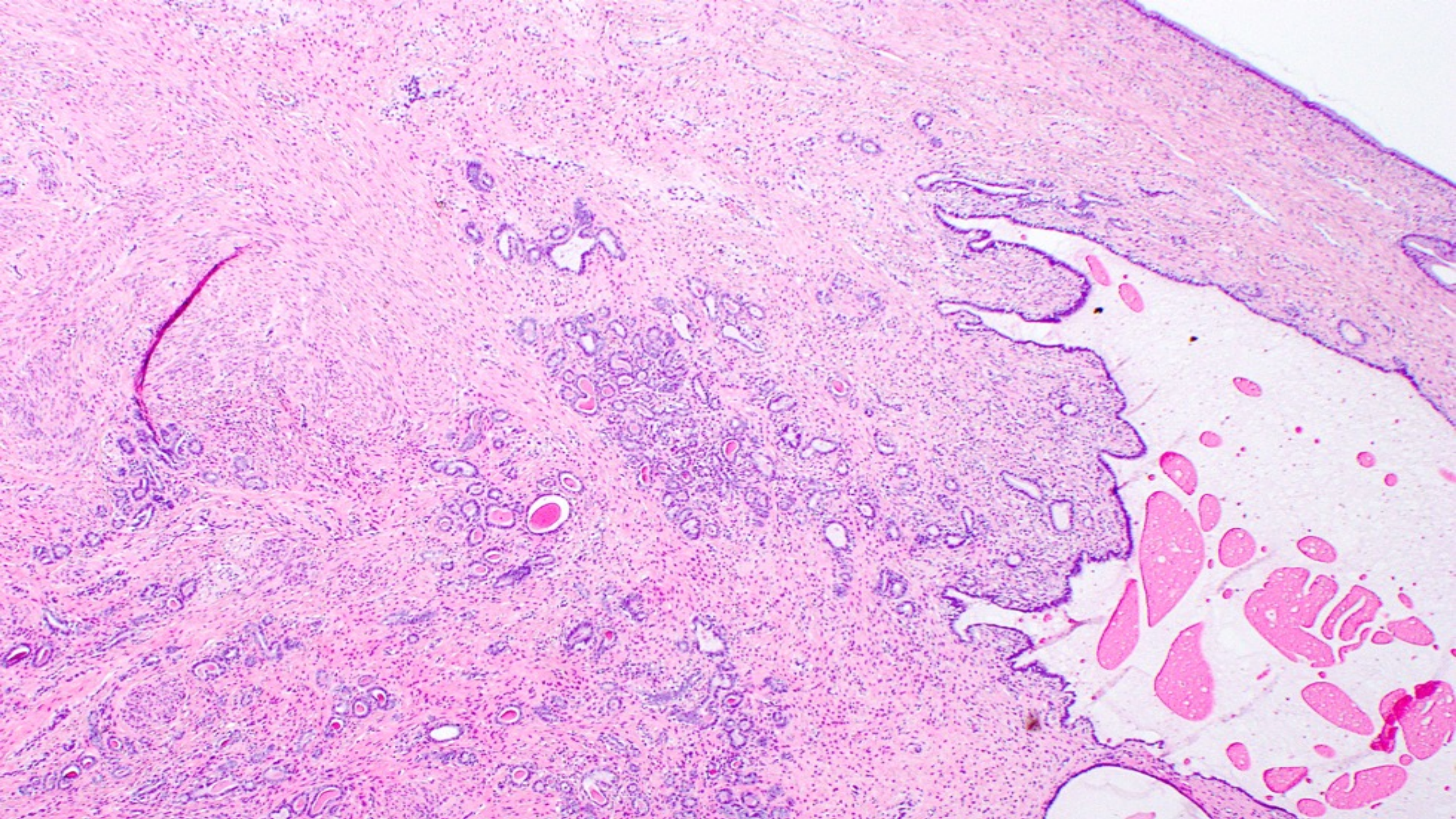
*Histopathol 2002;41:185-207*



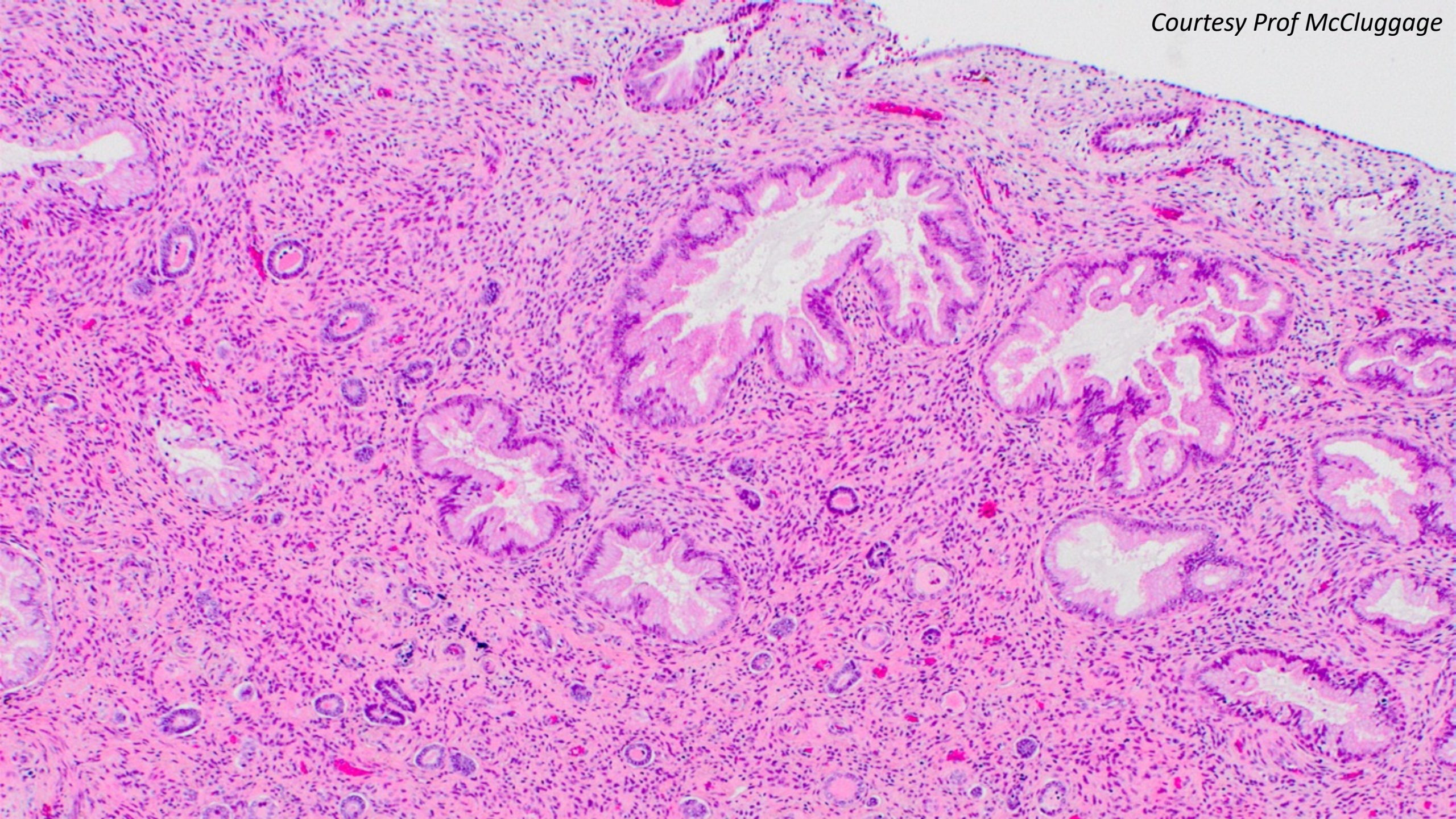




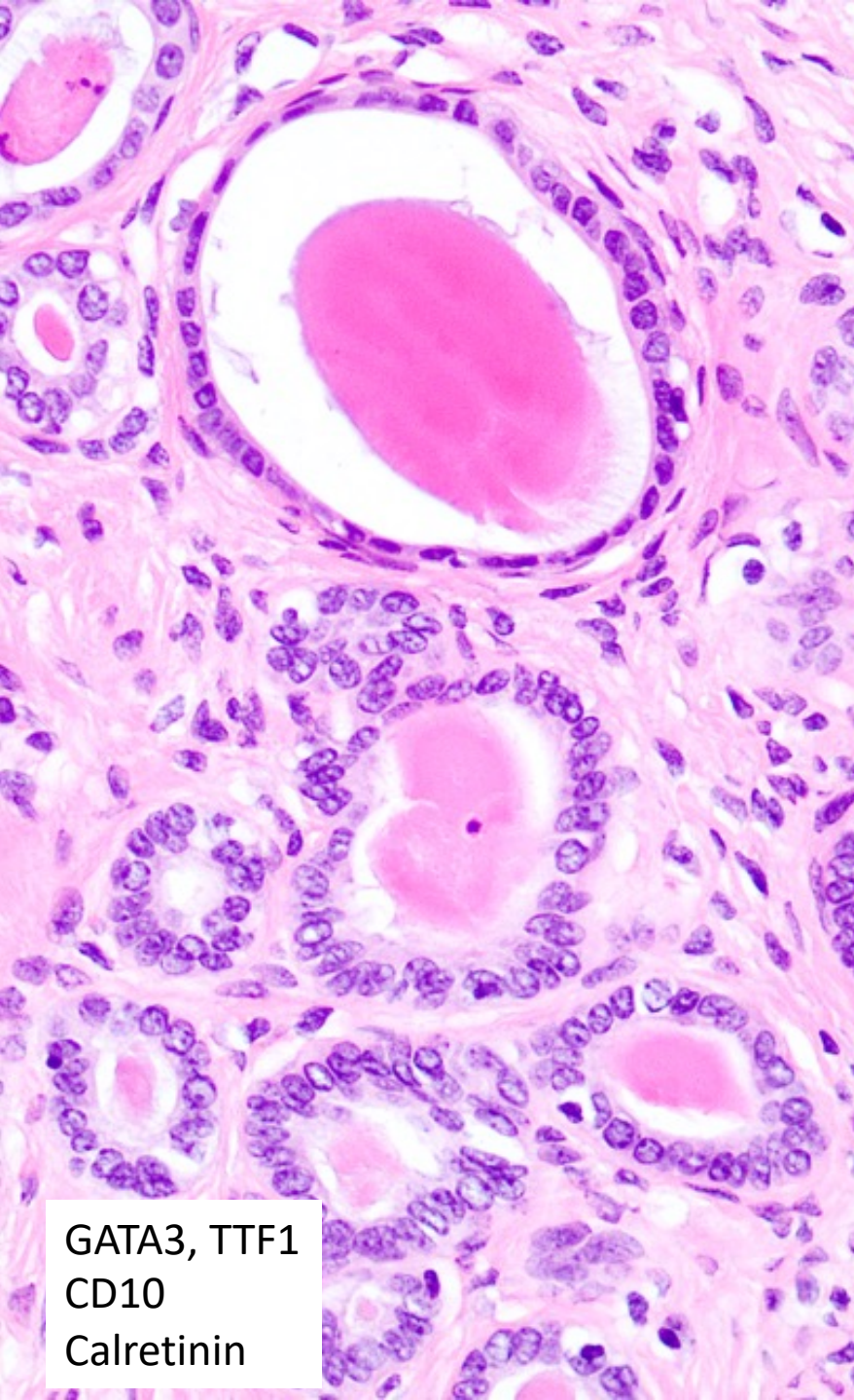




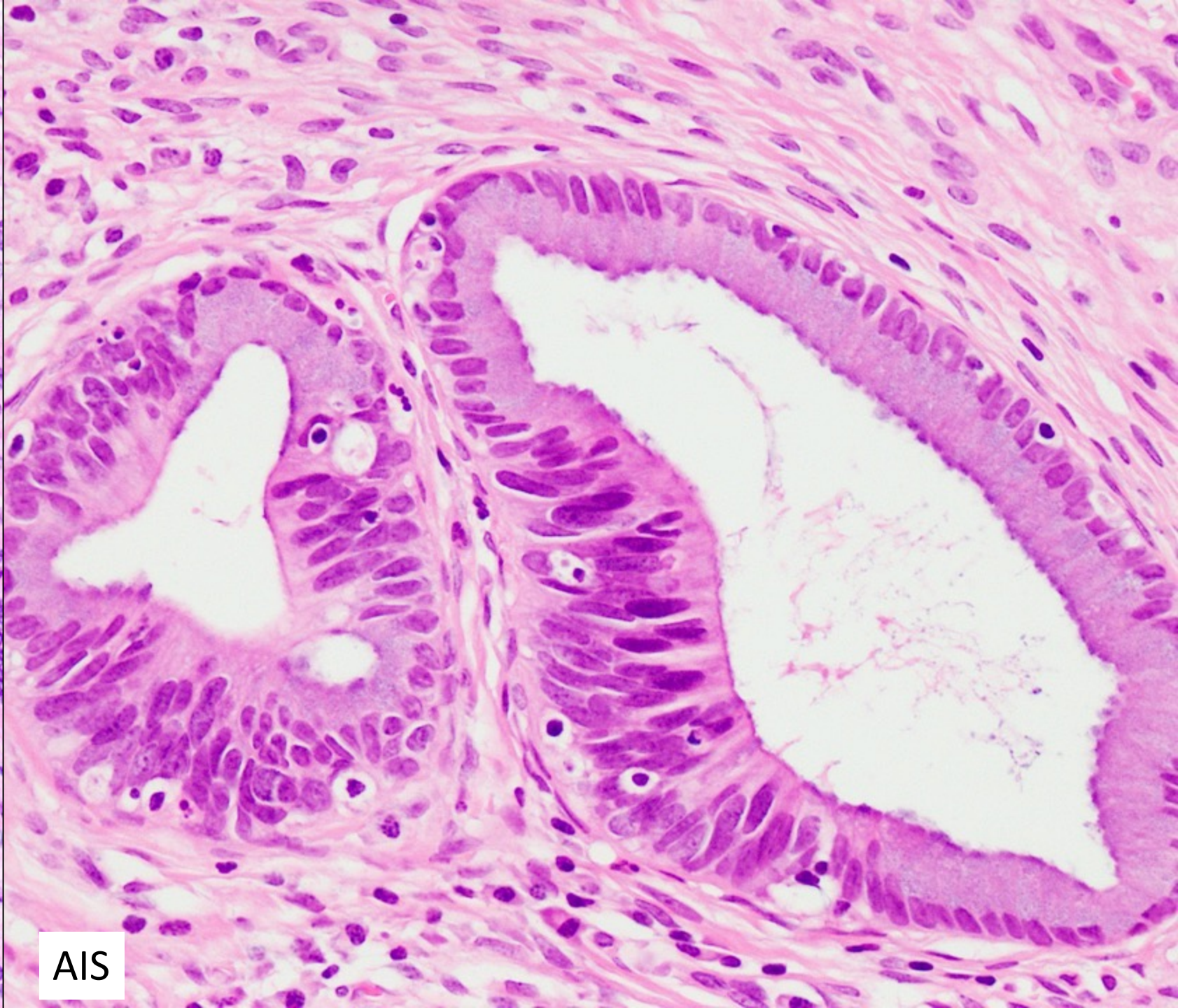






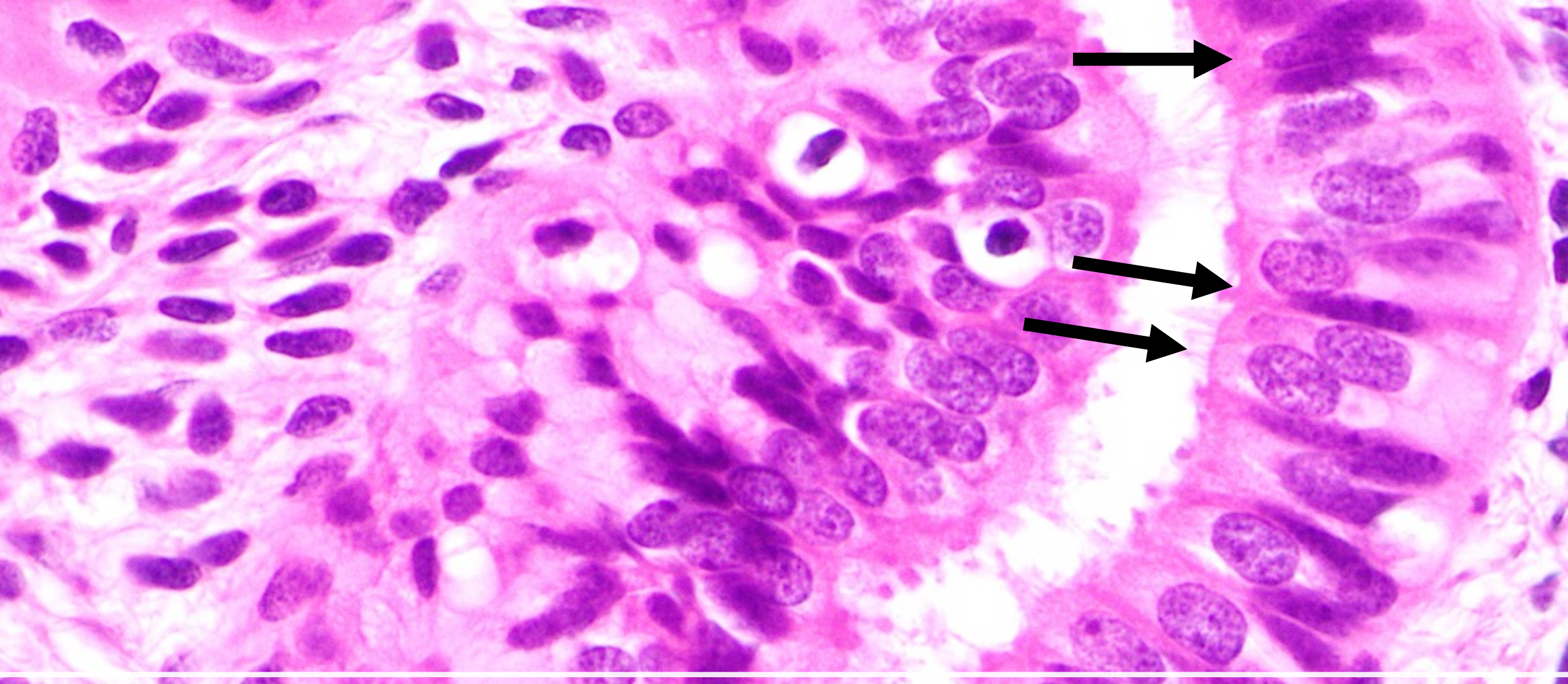


GATA3, TTF1  
CD10  
Calretinin



AIS

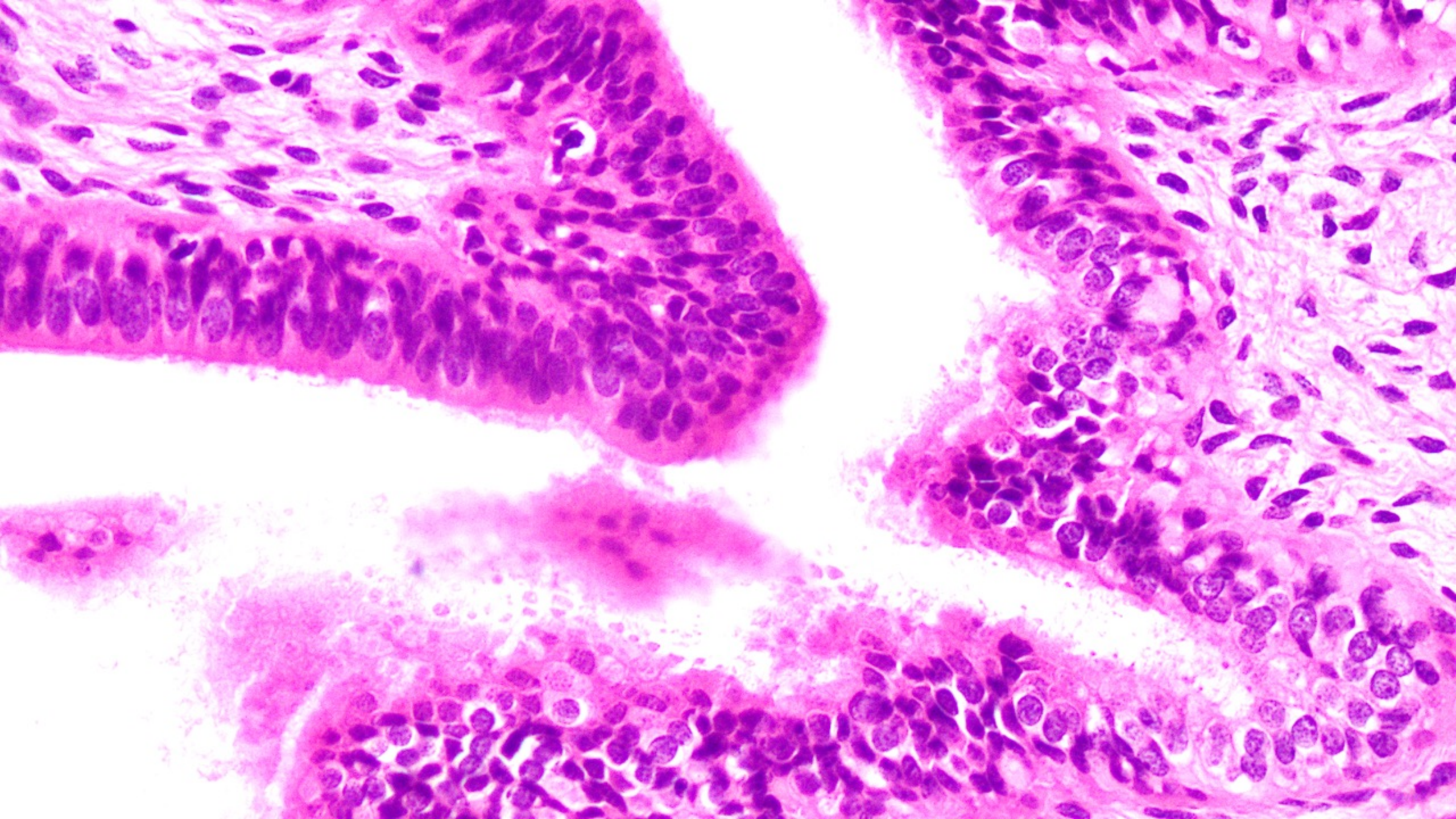




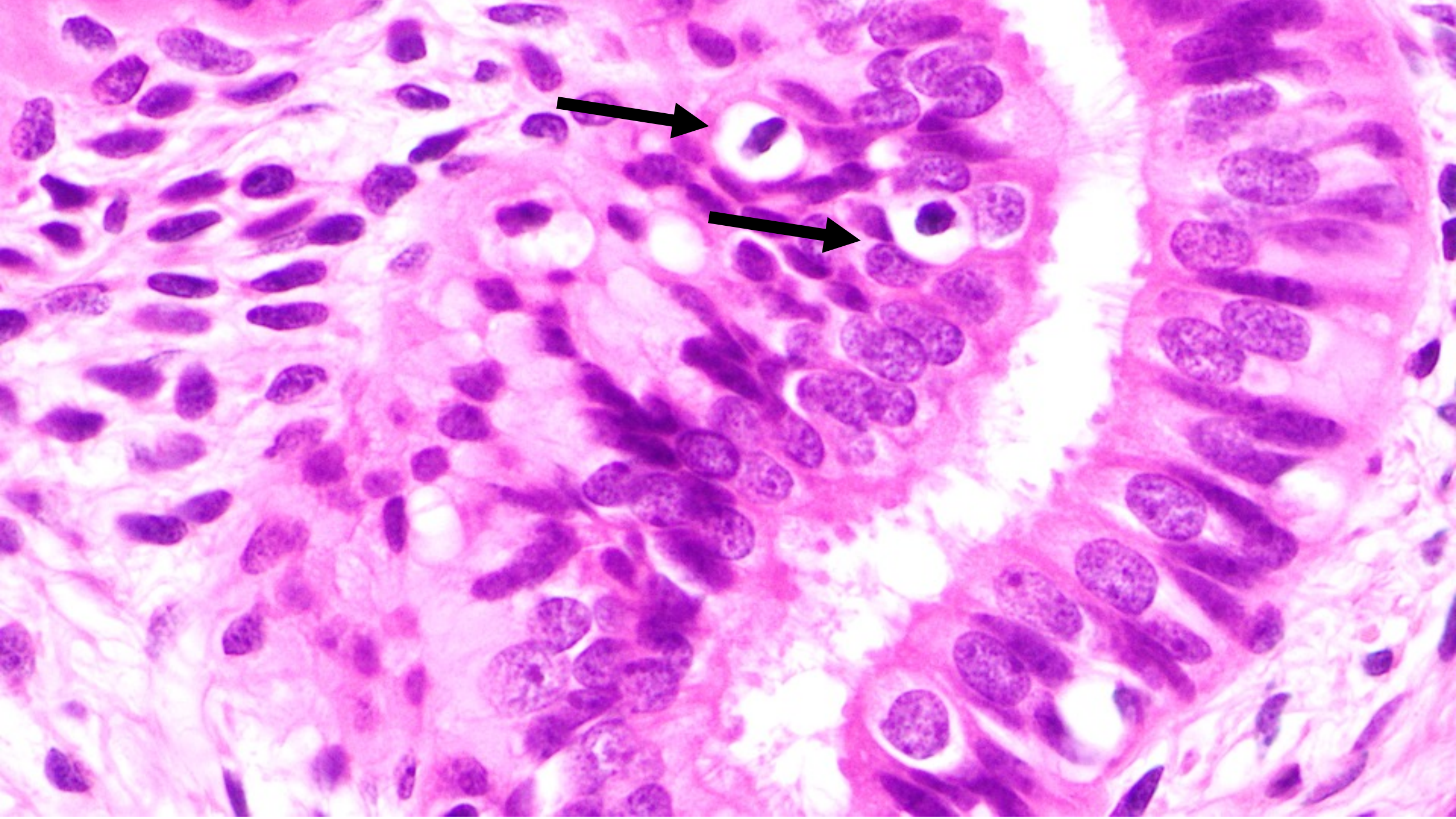
**Tubo-endometrioid metaplasia – genuinely deceptive mimic**



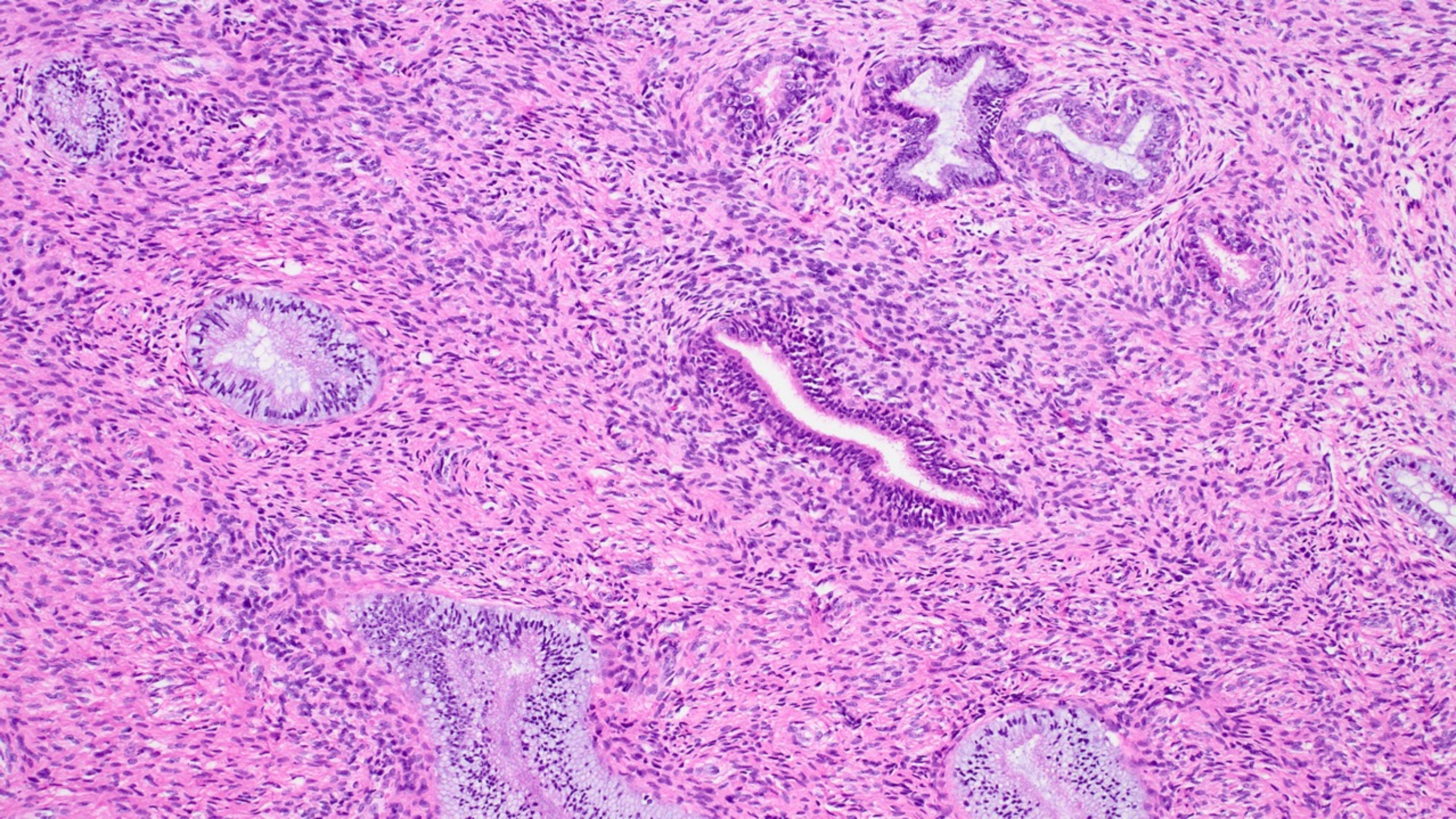




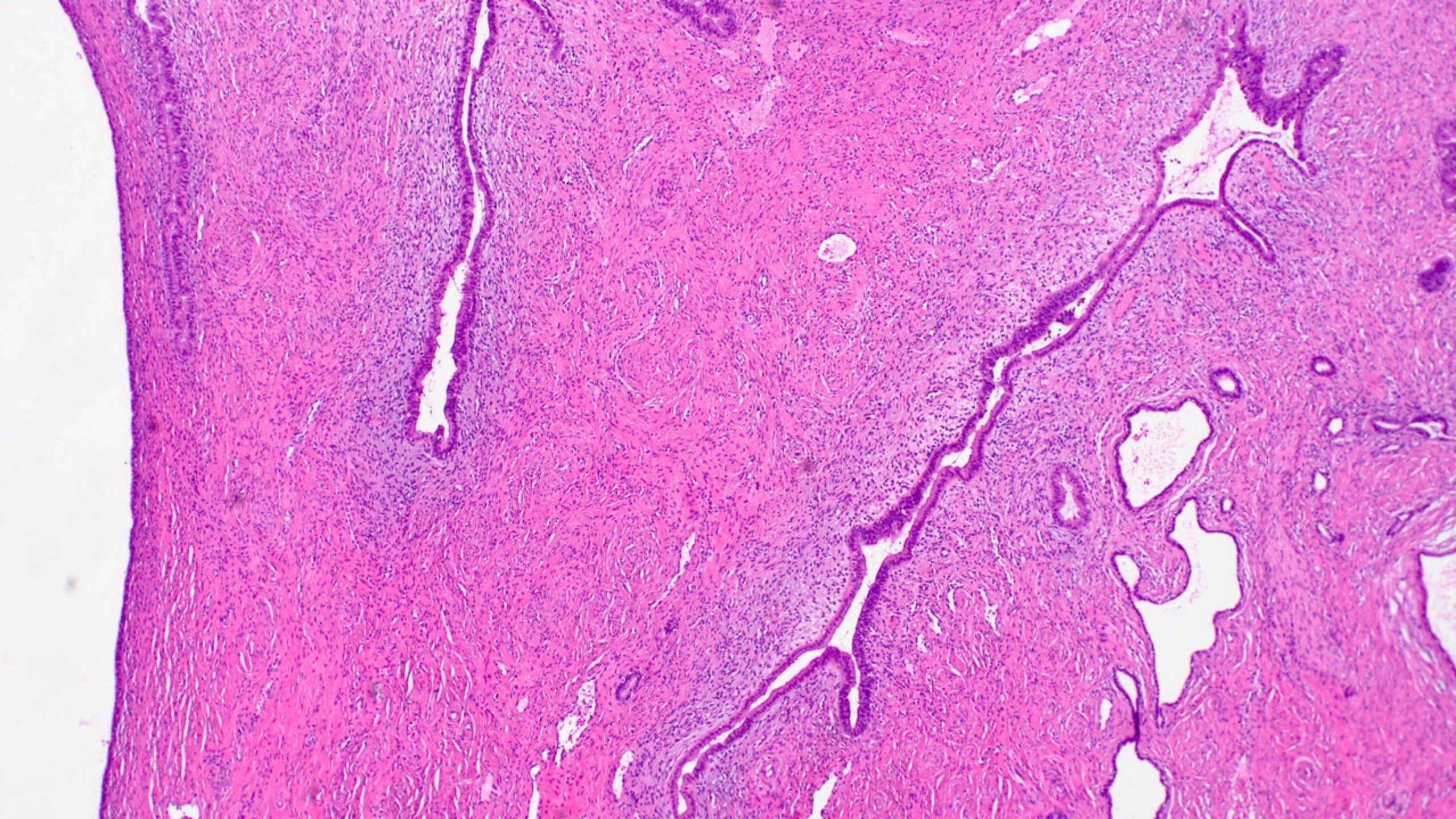




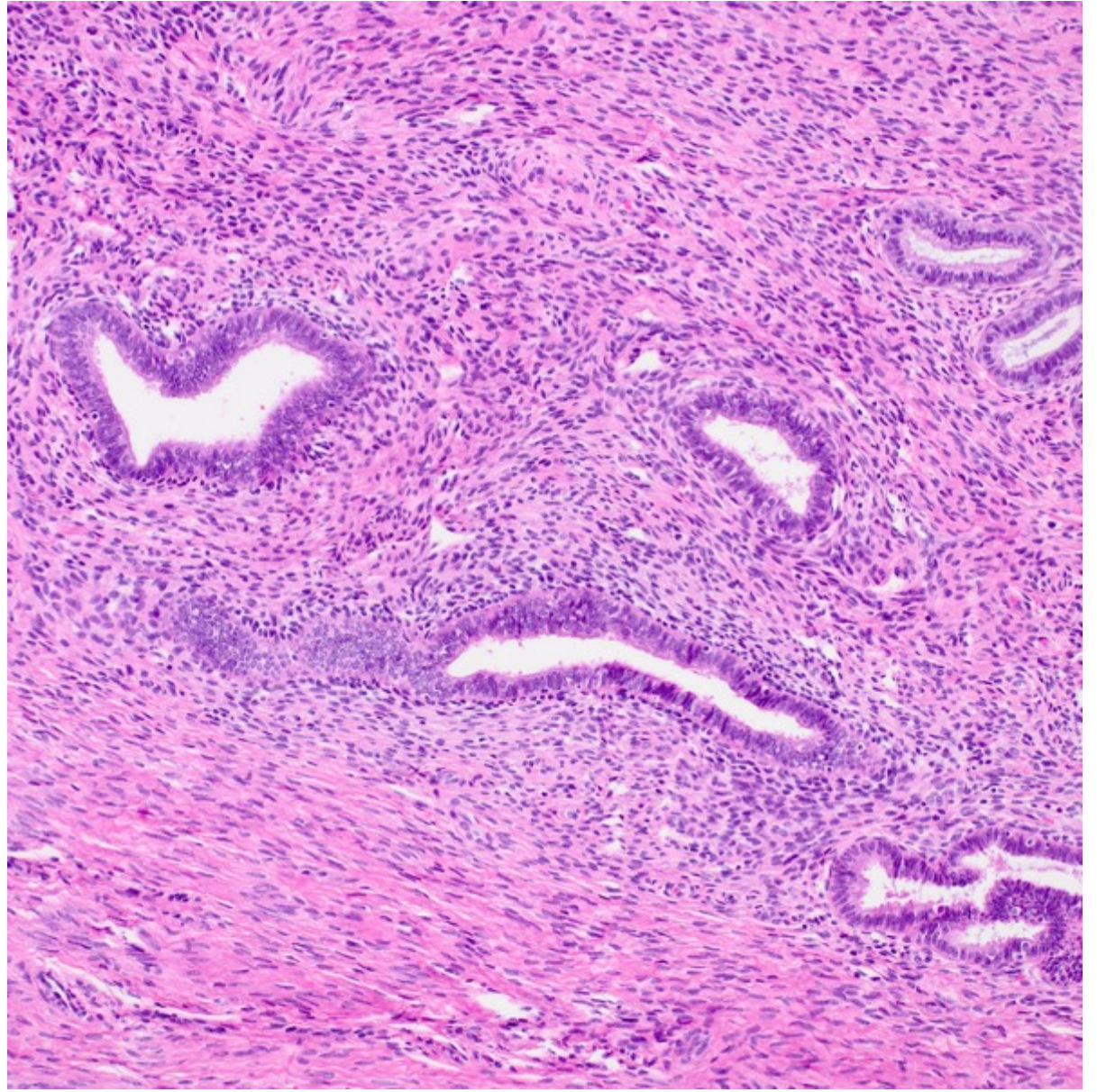
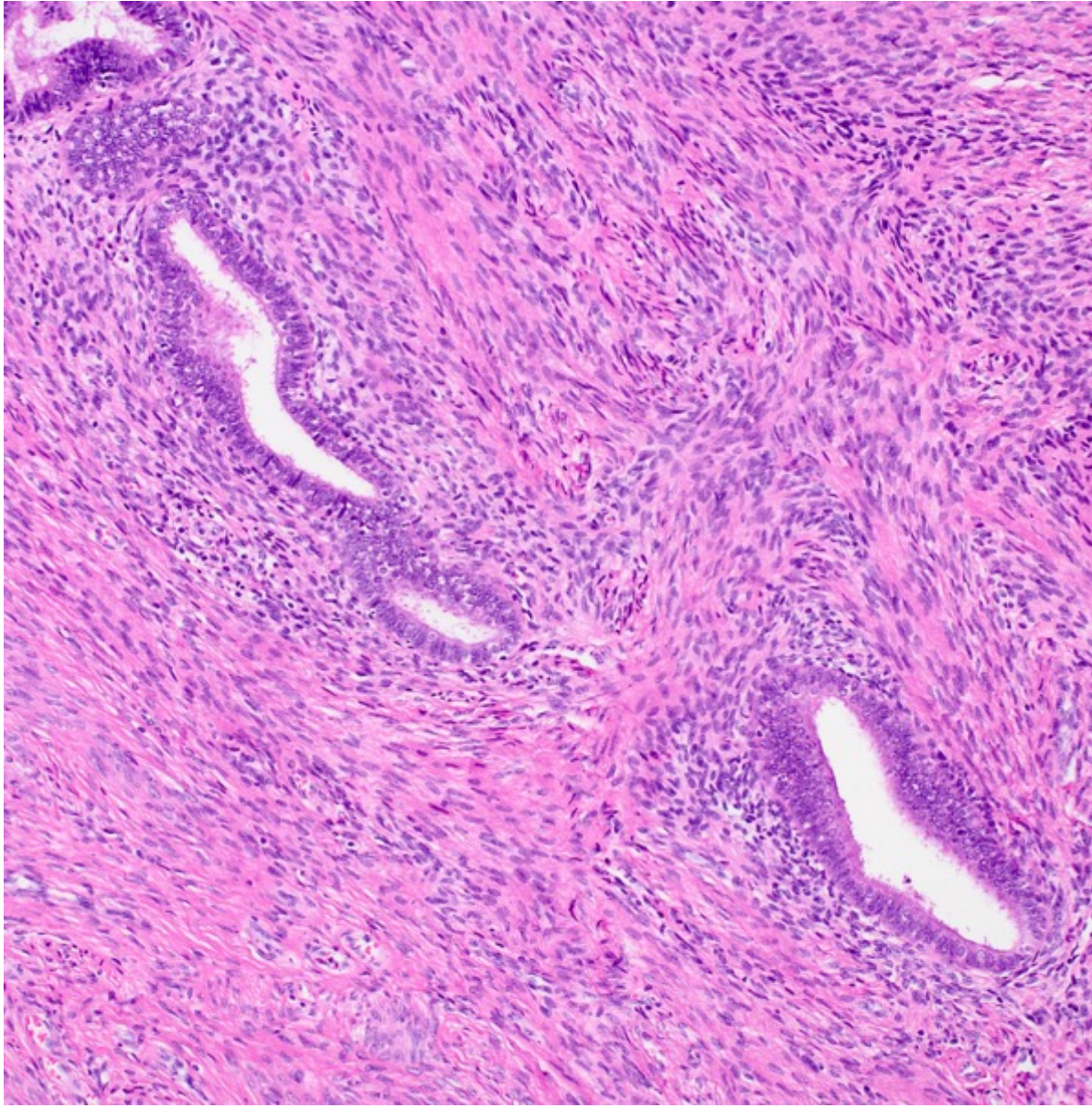














# Tubal and Tubo-Endometrioid Metaplasia of the Uterine Cervix

*Unemphasized Features That May Cause Problems in  
Differential Diagnosis: A Report of 25 Cases*

ESTHER OLIVA, MD,<sup>1</sup> PHILIP B. CLEMENT, MD,<sup>2</sup> AND ROBERT H. YOUNG, MD<sup>1</sup>

*Am J Clin Pathol 1995;103:618-23*

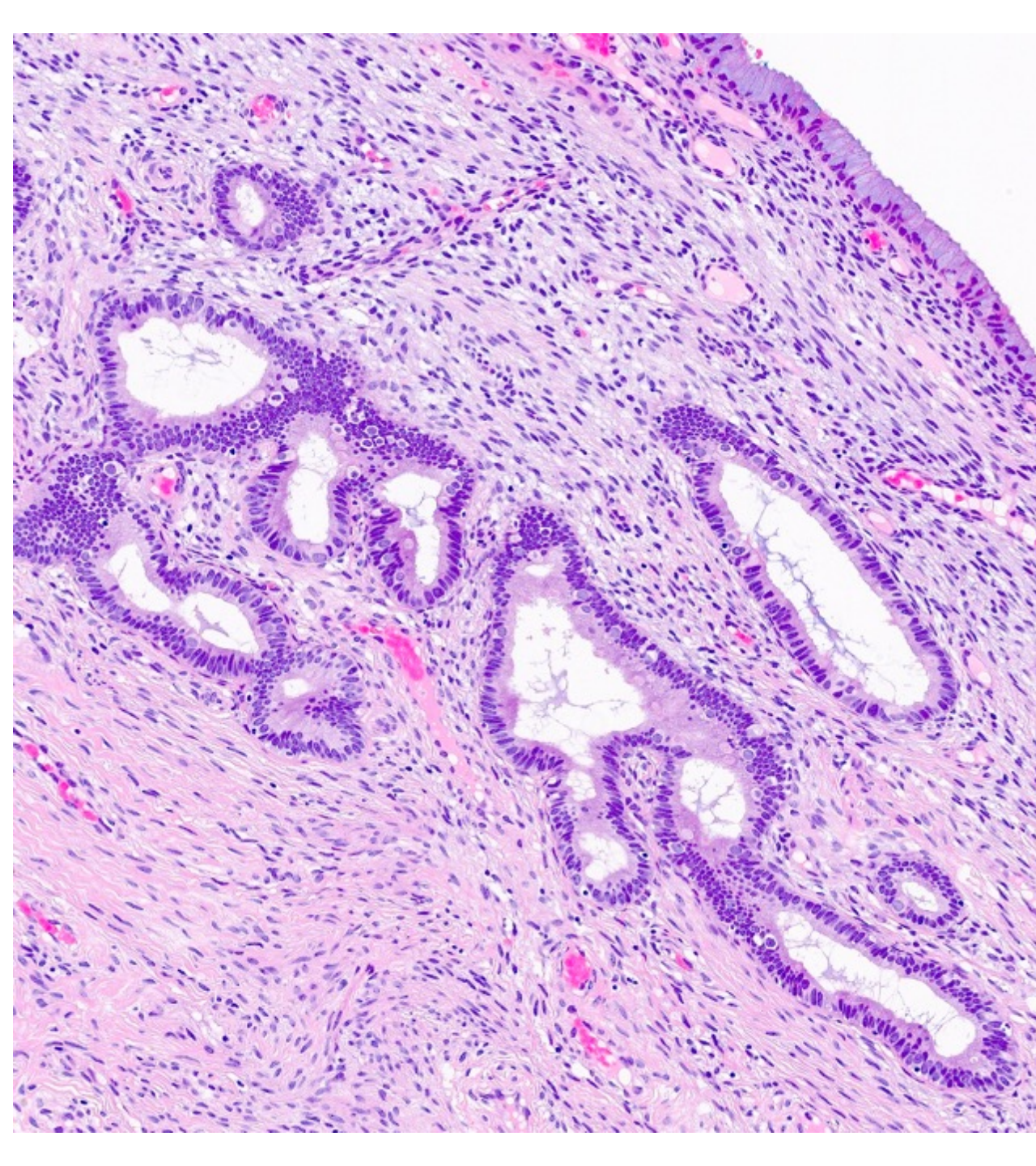
22 cases: Altered periglandular stroma

10 cases: Glands beyond inner 1/3<sup>rd</sup>,  
some outer 1/3<sup>rd</sup>

21 cases: Branching or cystic dilatation

## Helpful features:

- *Prominent cilia*
- *Bland cytology*
- *Lack of mitoses*
- *No unequivocal desmoplasia*





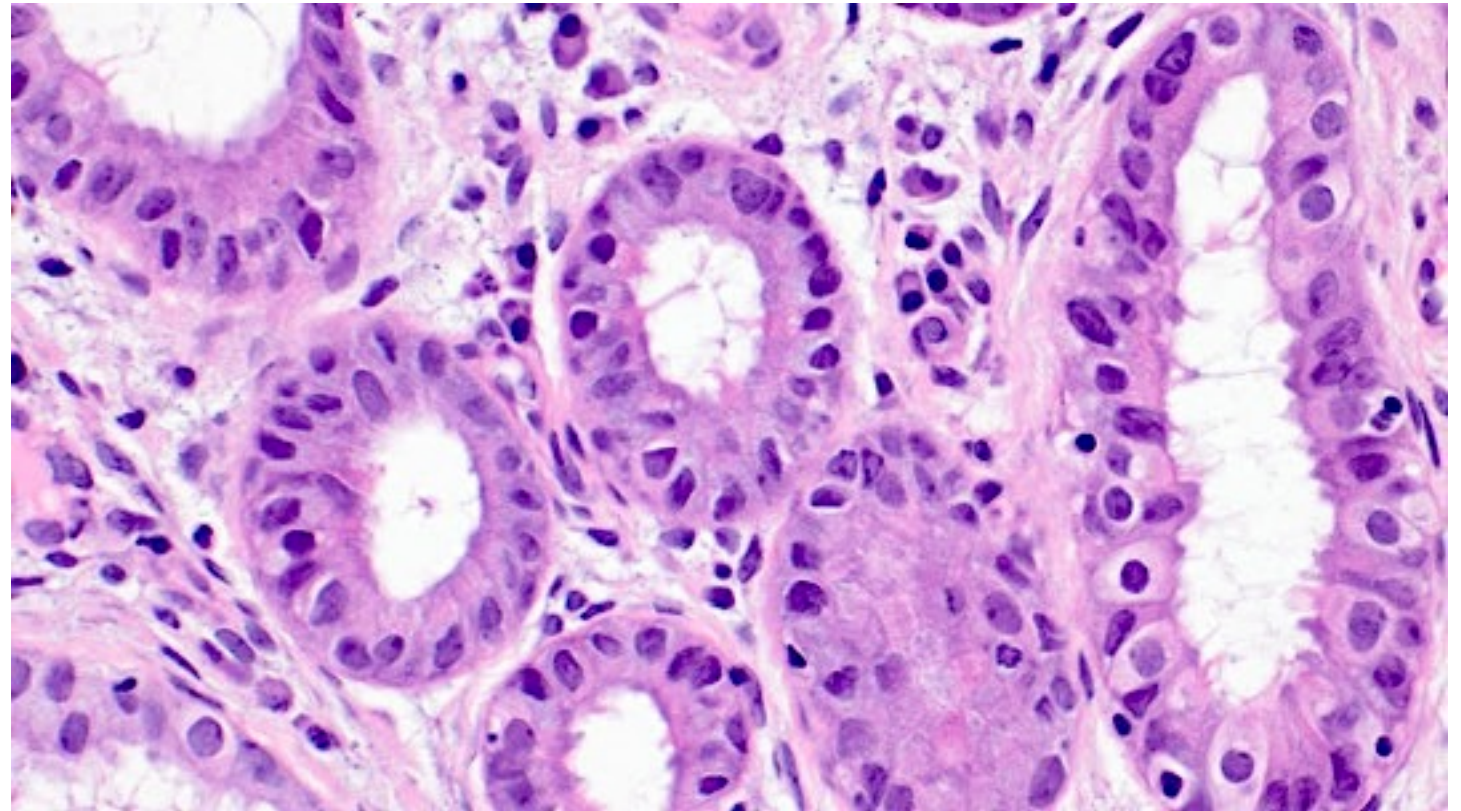
# Endocervical Adenocarcinoma *In Situ* of Tubal Type and Its Relation to Atypical Tubal Metaplasia

Cory Schlesinger, M.D. and Steven G. Silverberg, M.D.

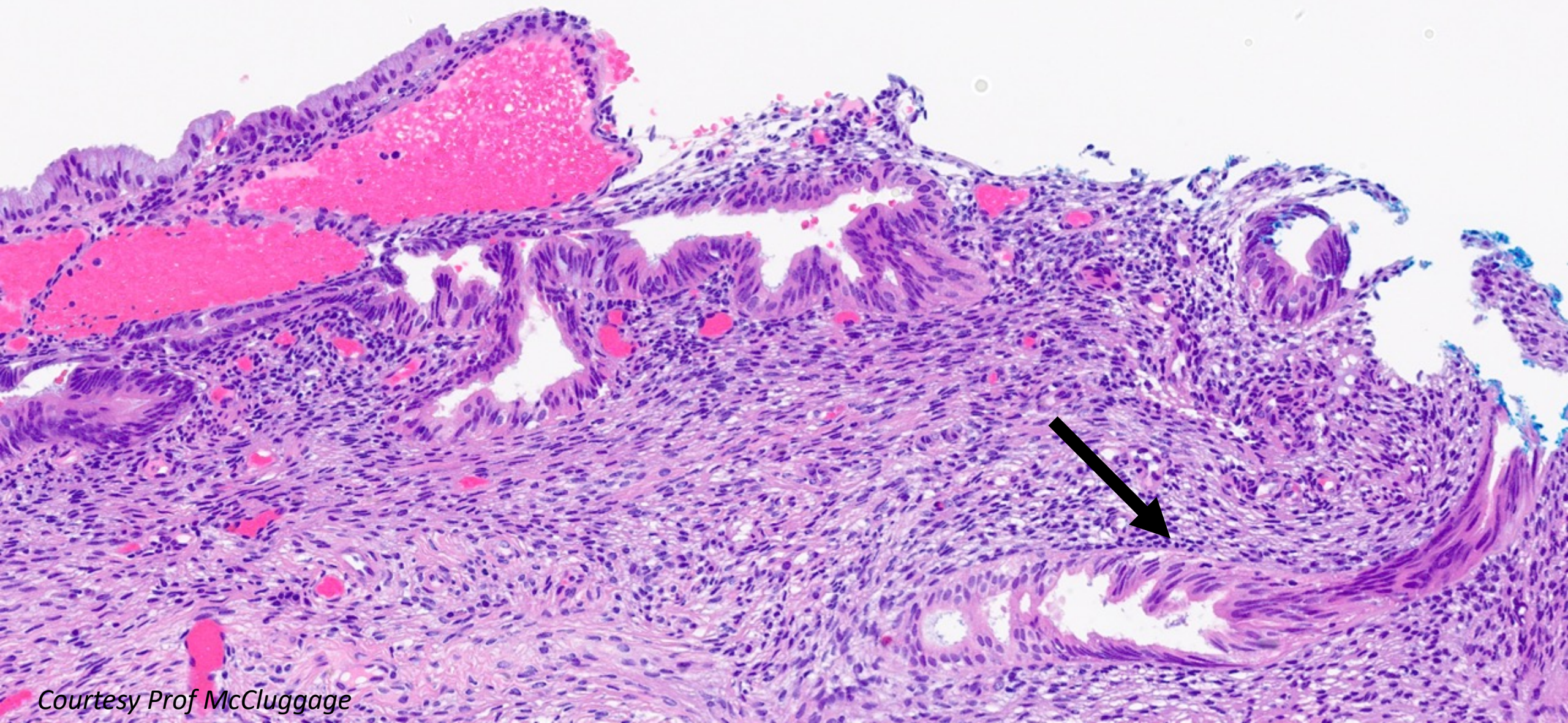
*IJGP 1999;18:1-4*

## “Atypical” TEM

- Nuclear enlargement
- Stratification
- Cellular crowding
- Occasional mitoses
- Fewer ciliated and intercalated cells







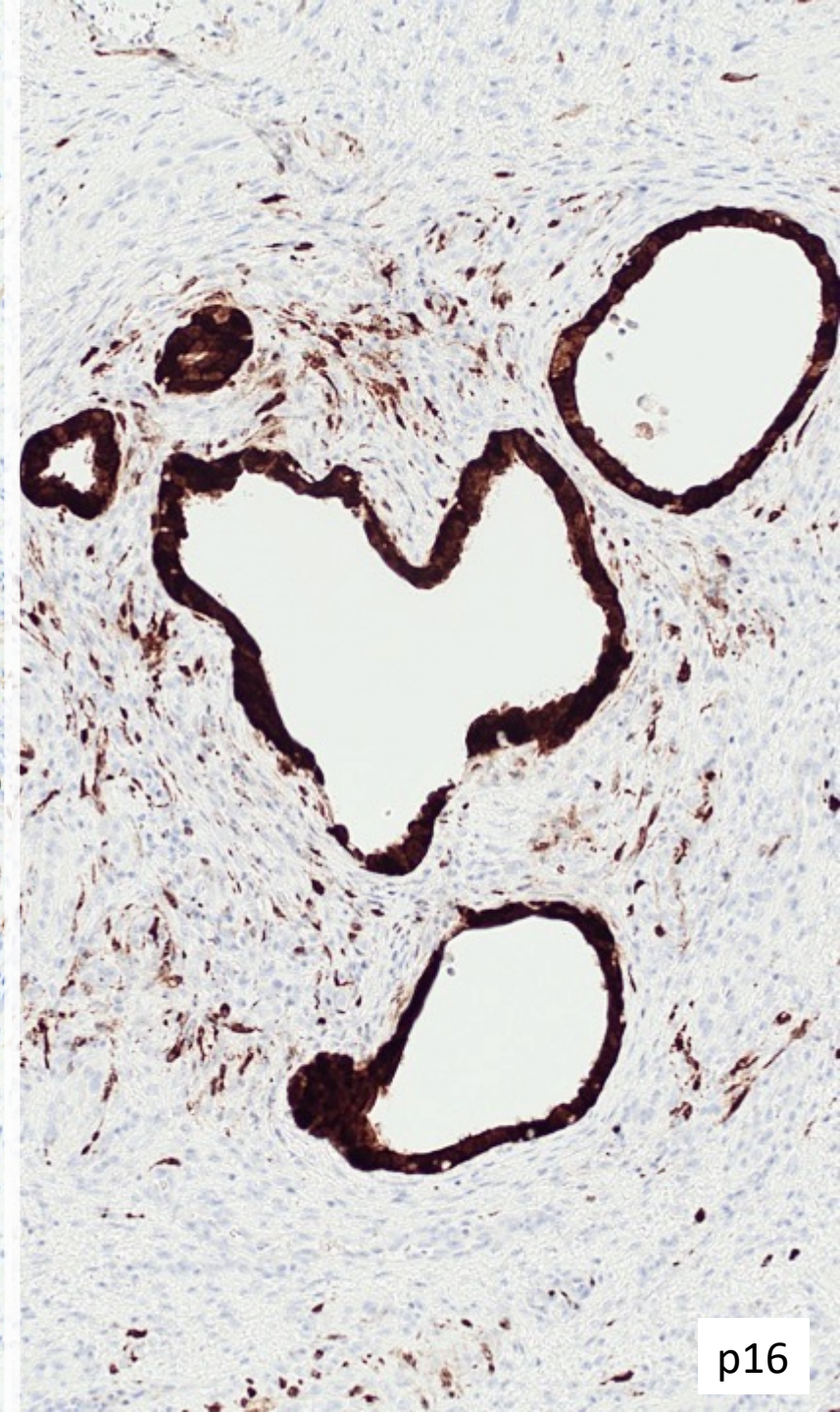
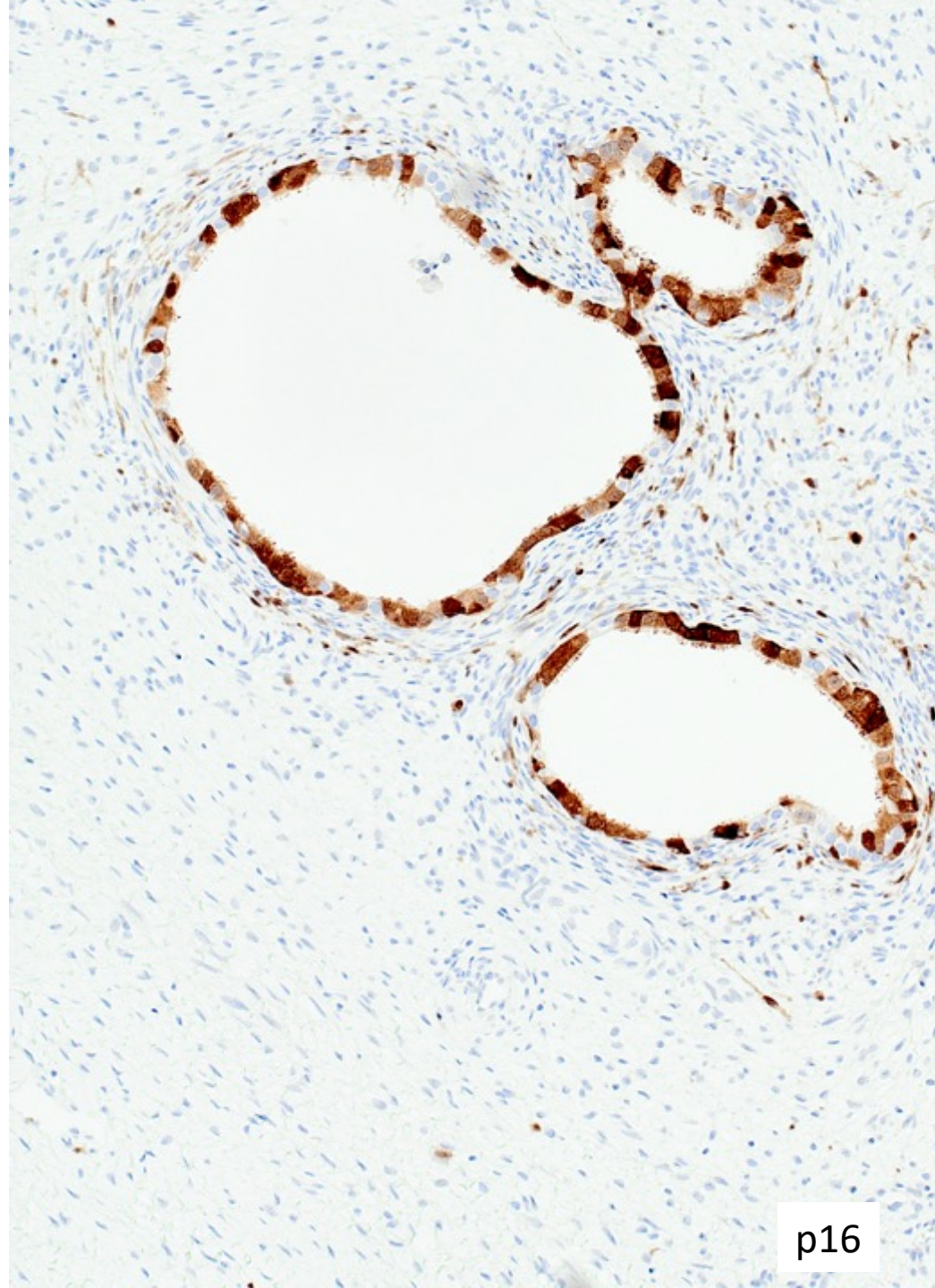
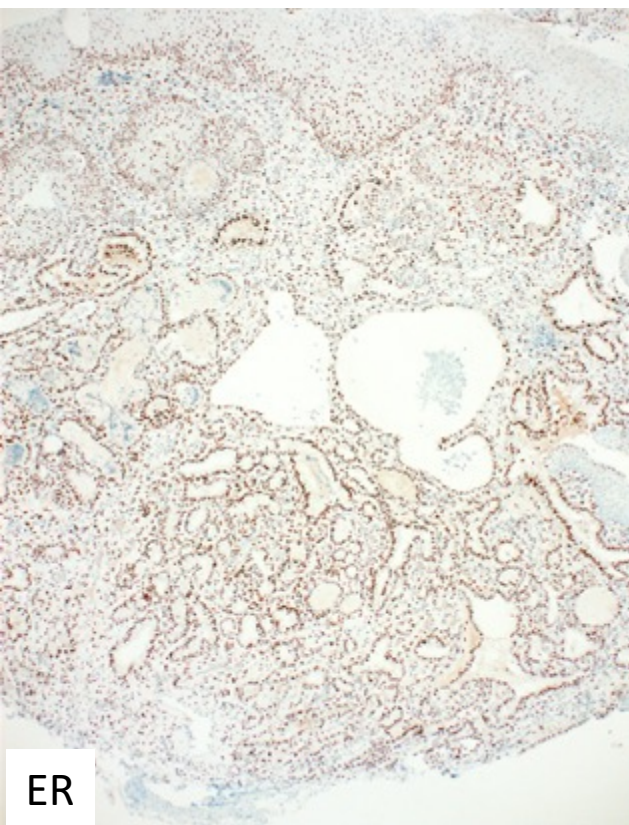
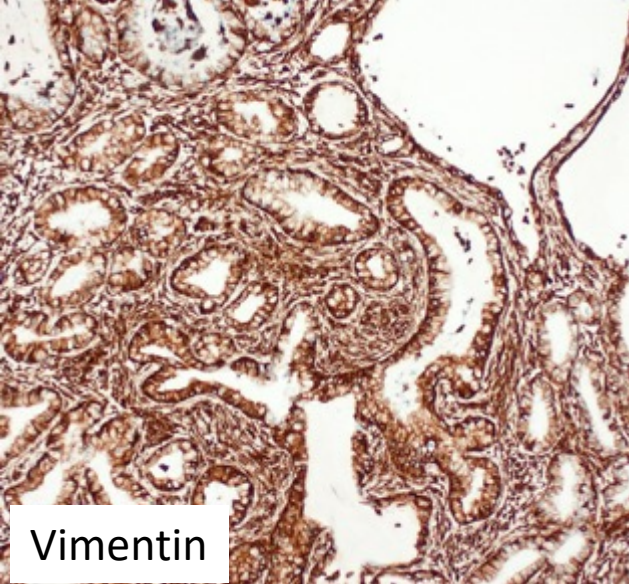
Courtesy Prof McCluggage



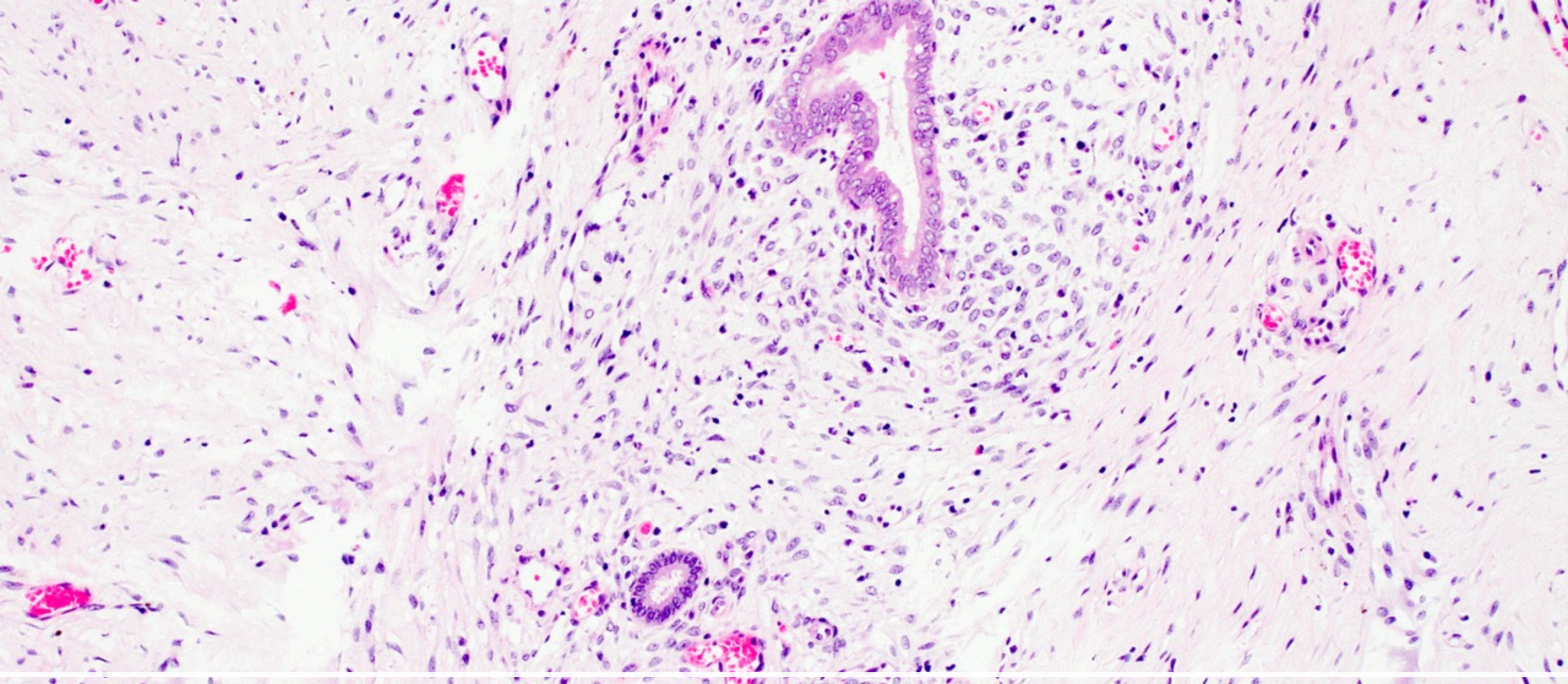
	<b>Adenocarcinoma In Situ</b>	<b>Tuboendometrial Metaplasia/Superficial Endometriosis</b>
p16	Diffuse (block-type) positive	Negative or focally (mosaic-type) positive
bcl2	Negative	Diffuse positive
MIB1	> 30%	< 30%
vimentin	Negative	Diffuse positive
ER/ PR	Negative	Diffuse positive
CEA	Diffuse positive (cytoplasmic)	Negative or luminal staining

This table lists the usual staining reactions, but aberrant staining patterns may occur in individual cases.

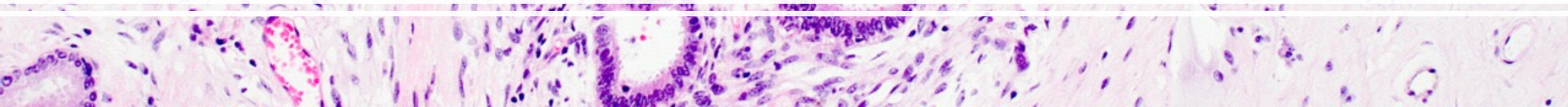




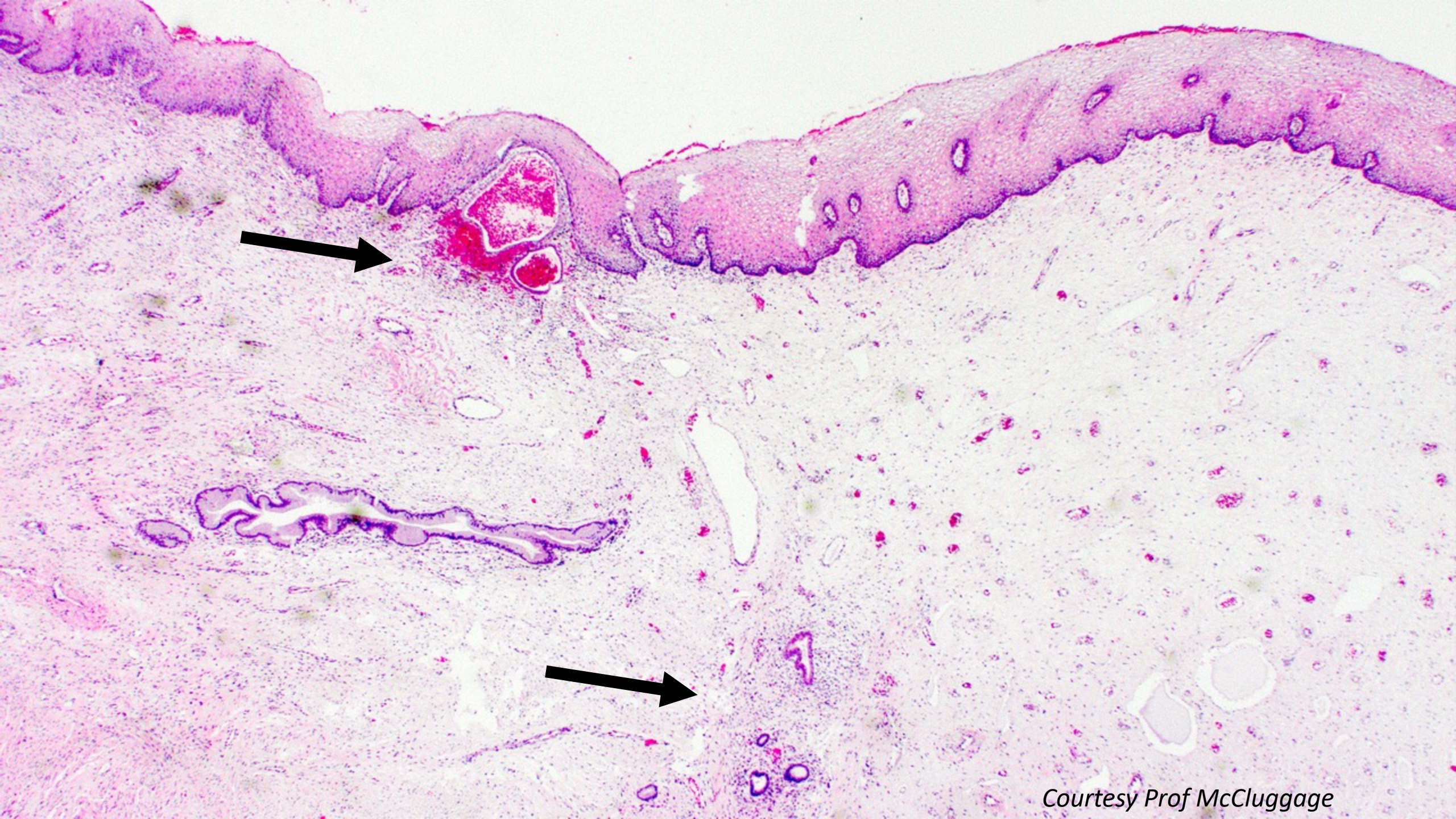




**Superficial cervical endometriosis**

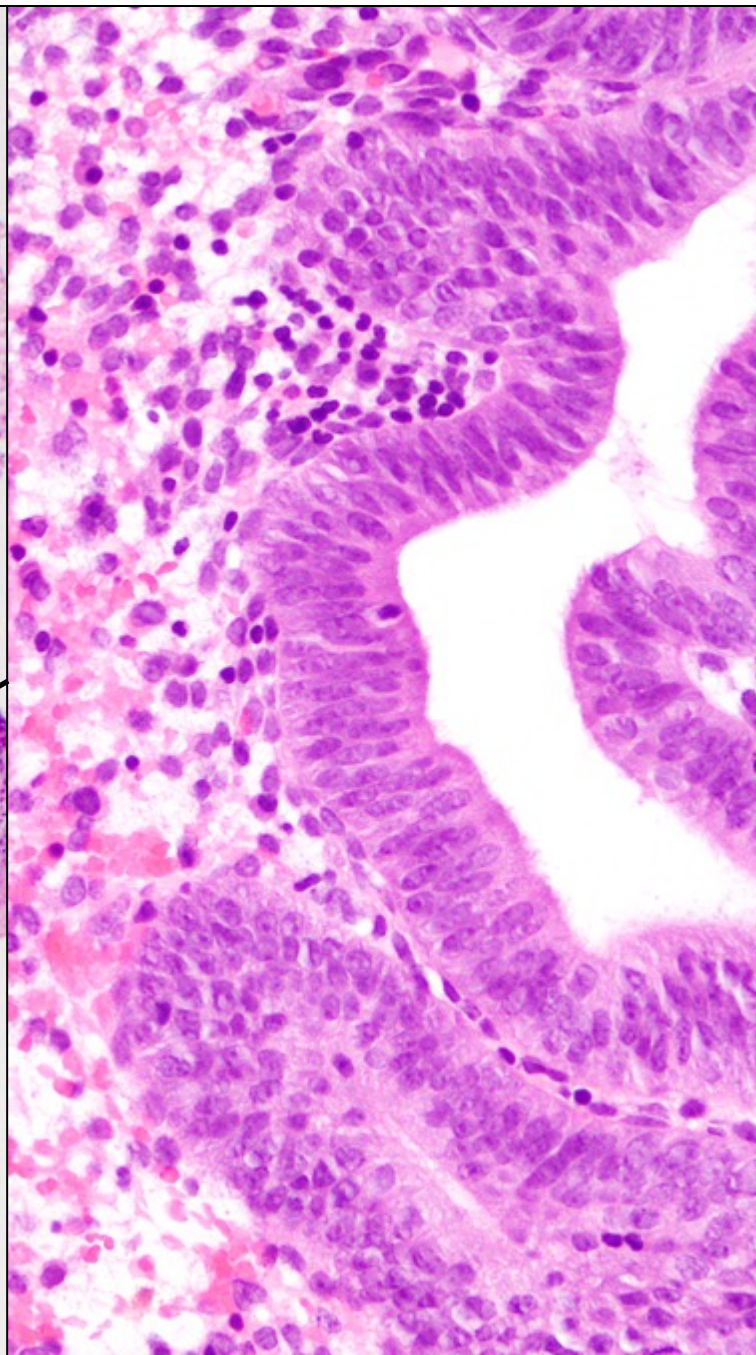
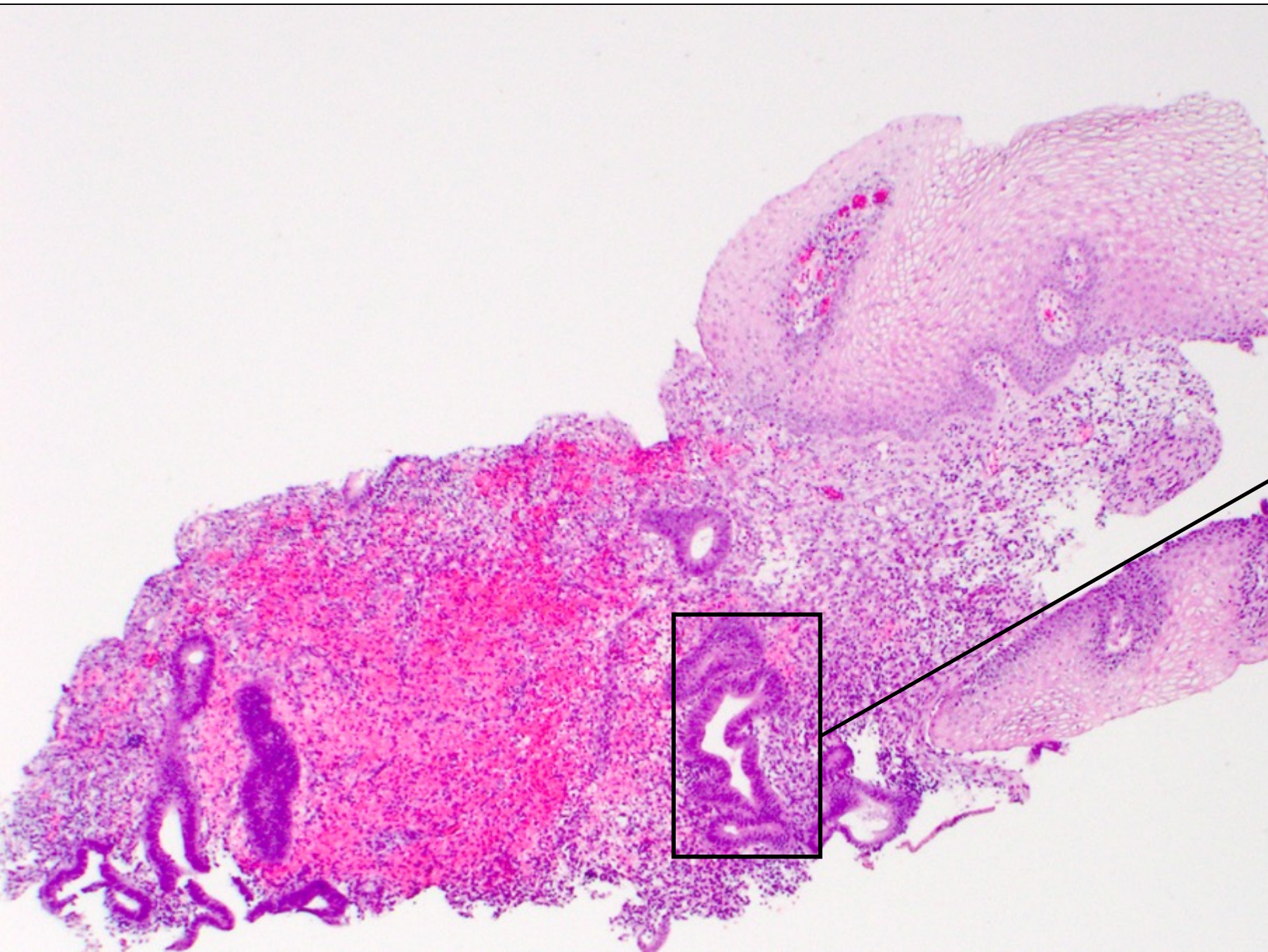




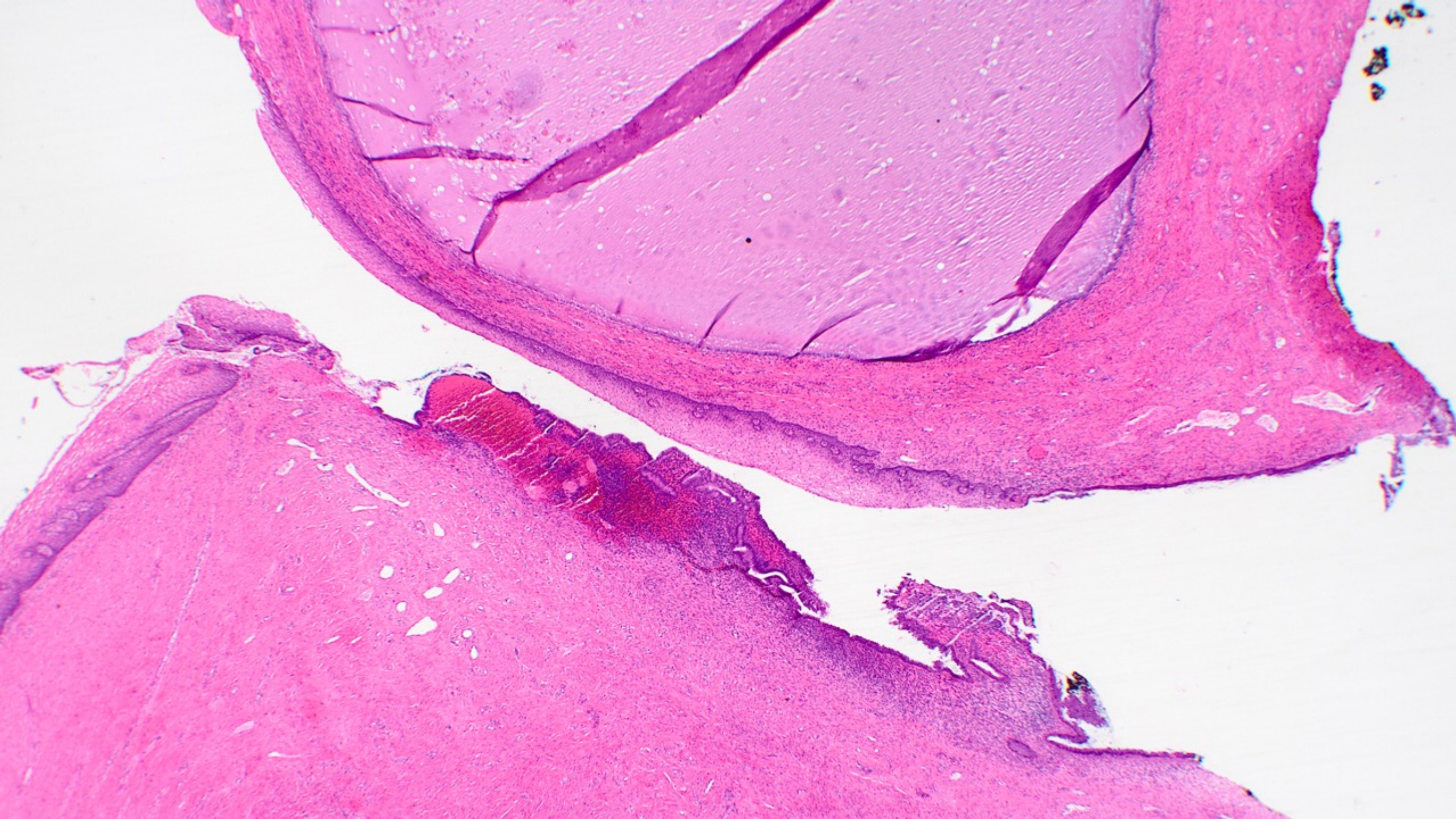


Courtesy Prof McCluggage

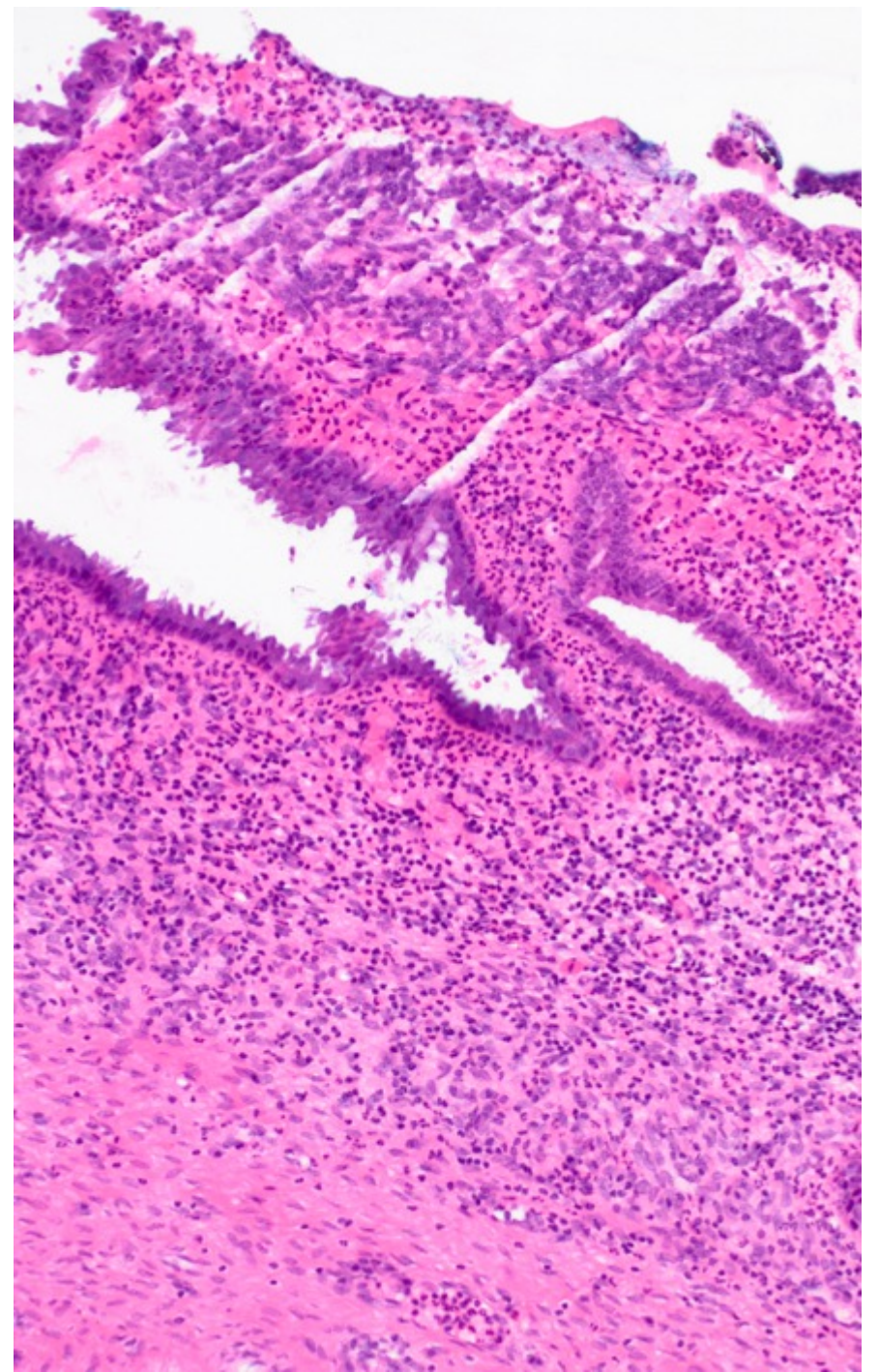
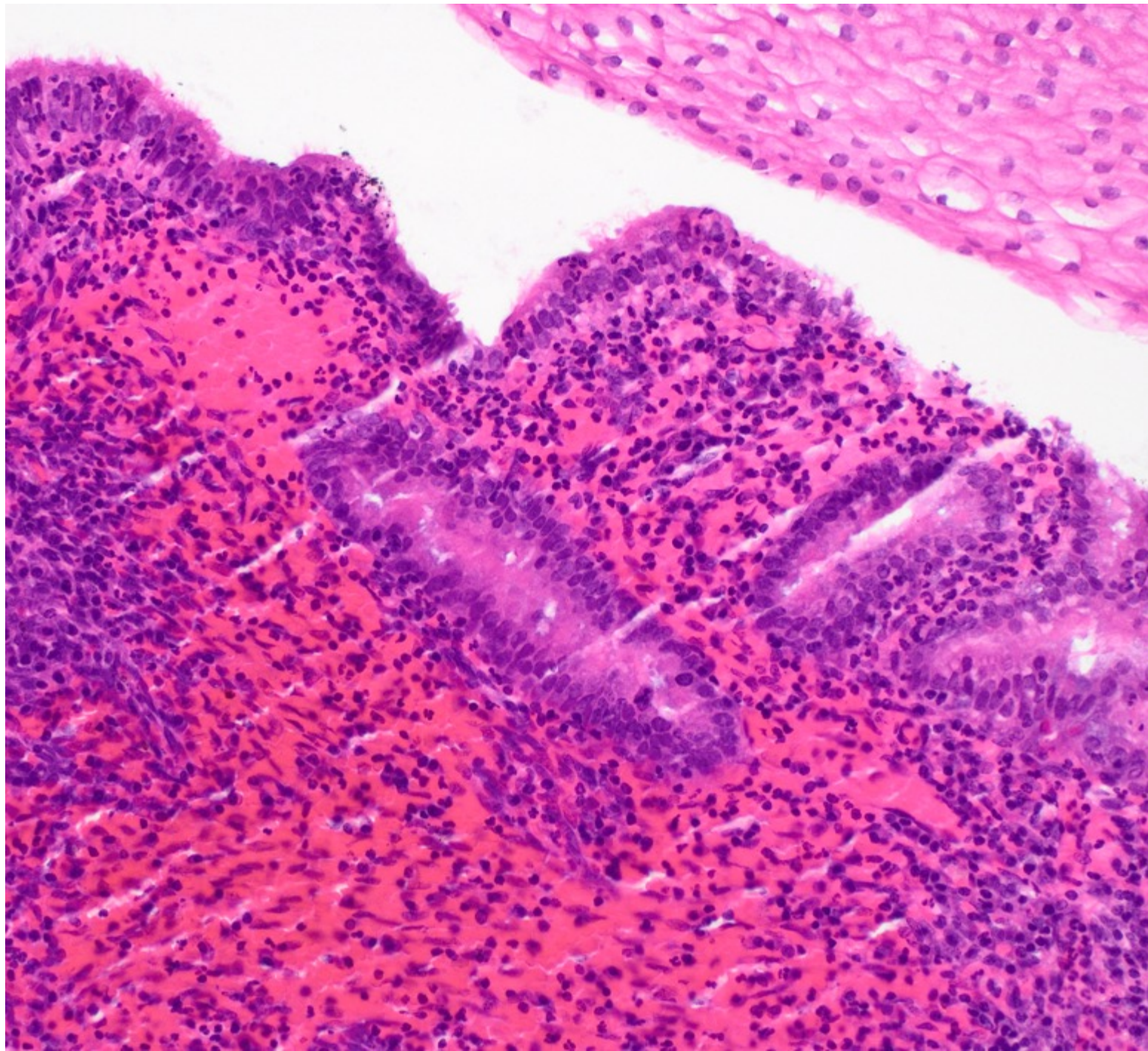




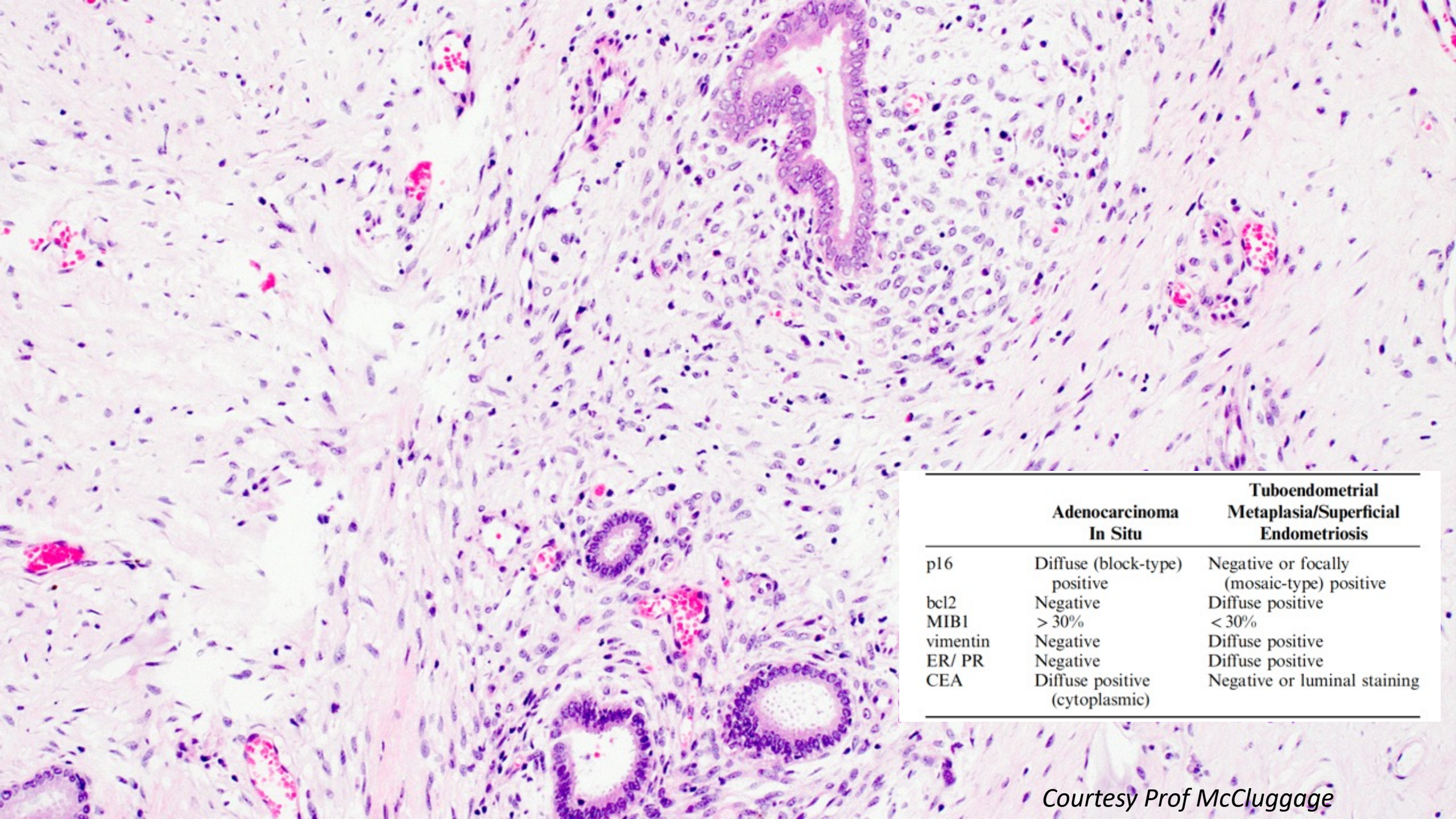








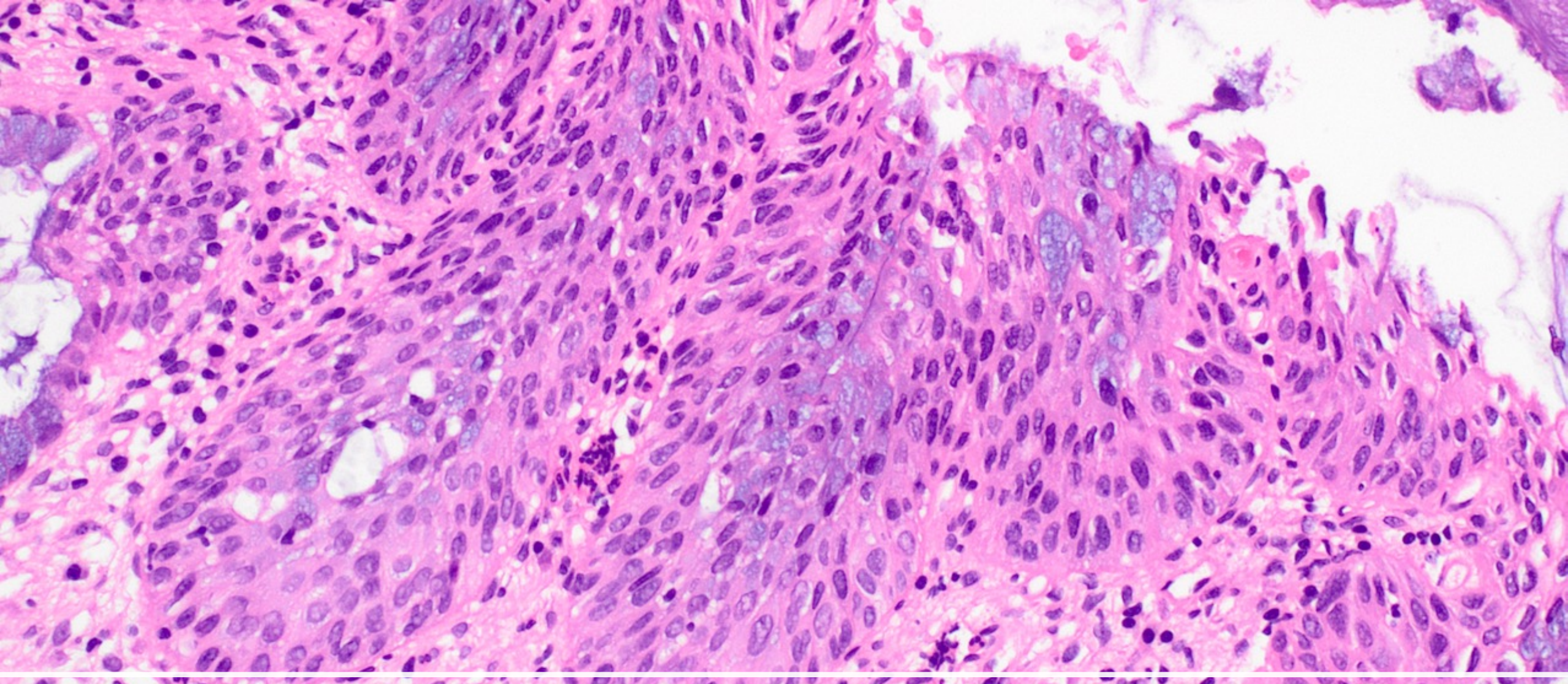




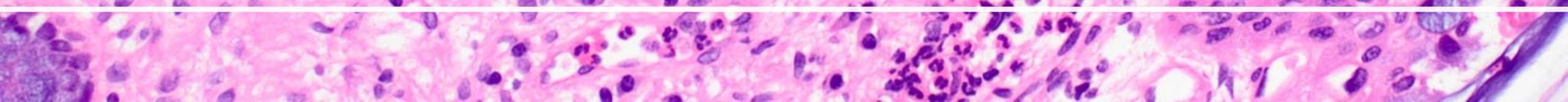
	<b>Adenocarcinoma In Situ</b>	<b>Tuboendometrial Metaplasia/Superficial Endometriosis</b>
p16	Diffuse (block-type) positive	Negative or focally (mosaic-type) positive
bcl2	Negative	Diffuse positive
MIB1	> 30%	< 30%
vimentin	Negative	Diffuse positive
ER/ PR	Negative	Diffuse positive
CEA	Diffuse positive (cytoplasmic)	Negative or luminal staining

*Courtesy Prof McCluggage*

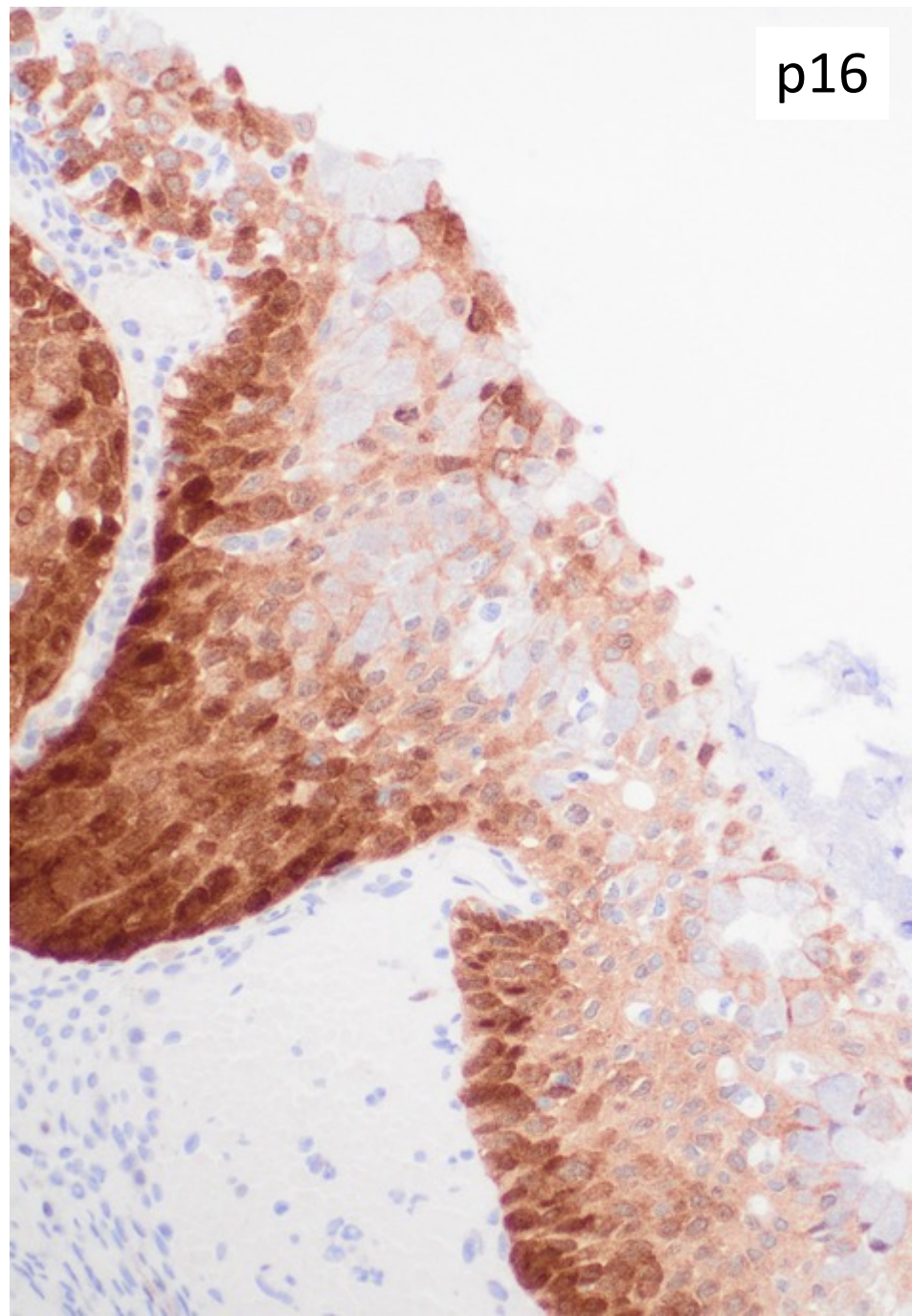
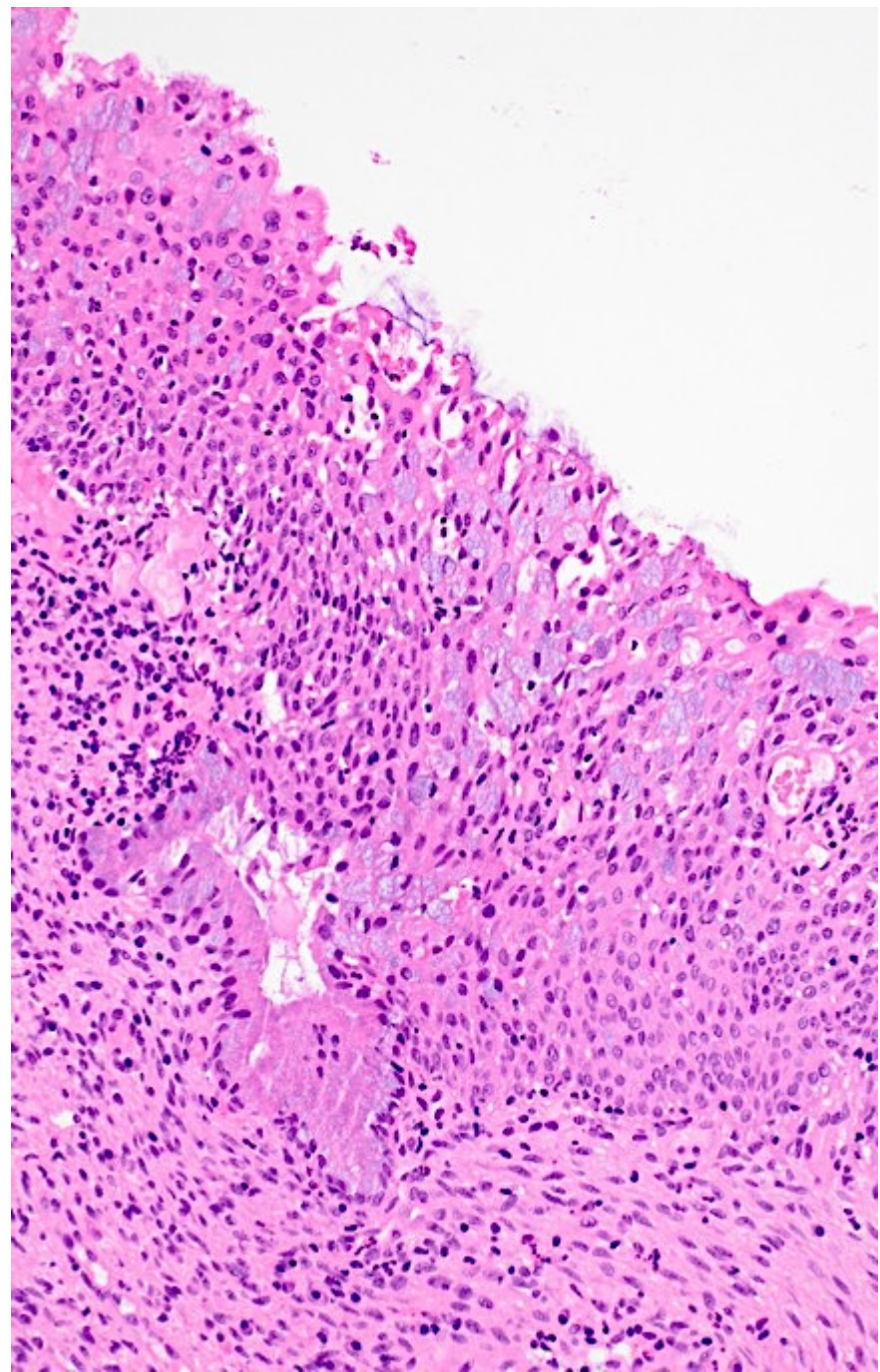
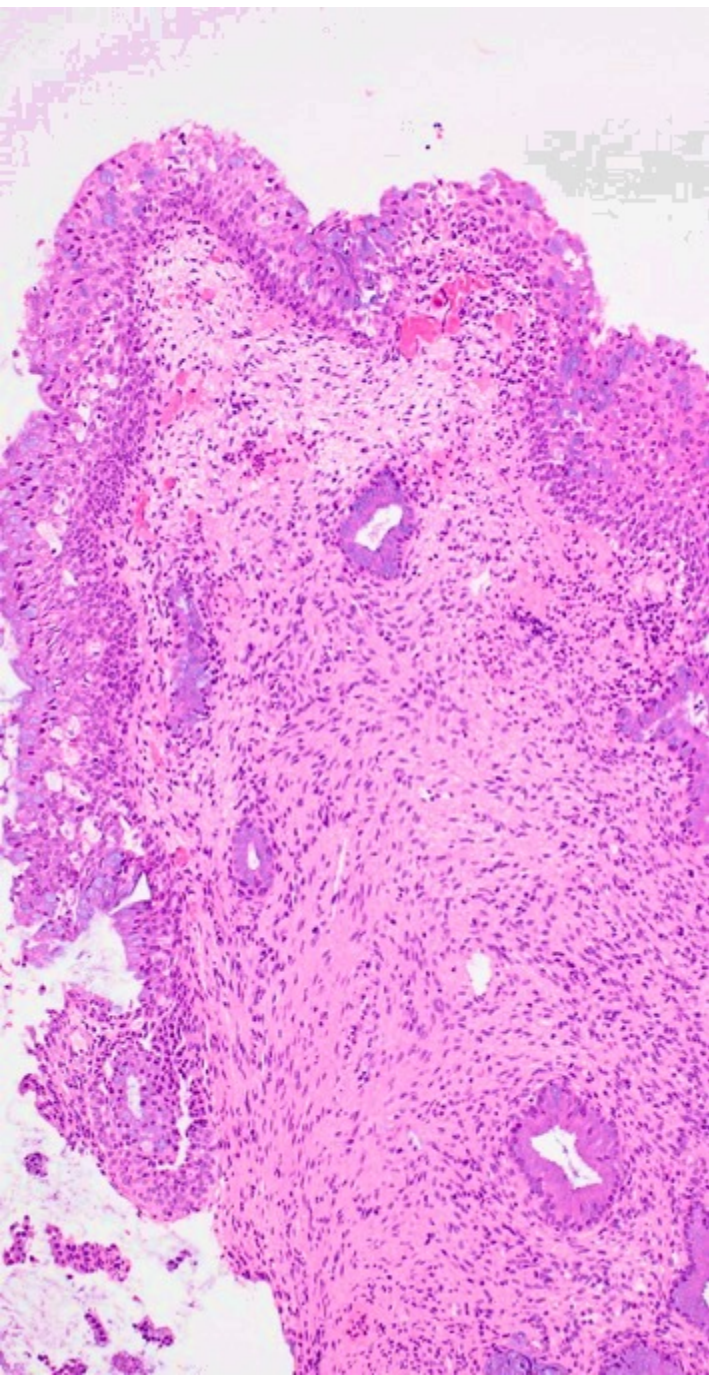




**Mimics of SMILE**

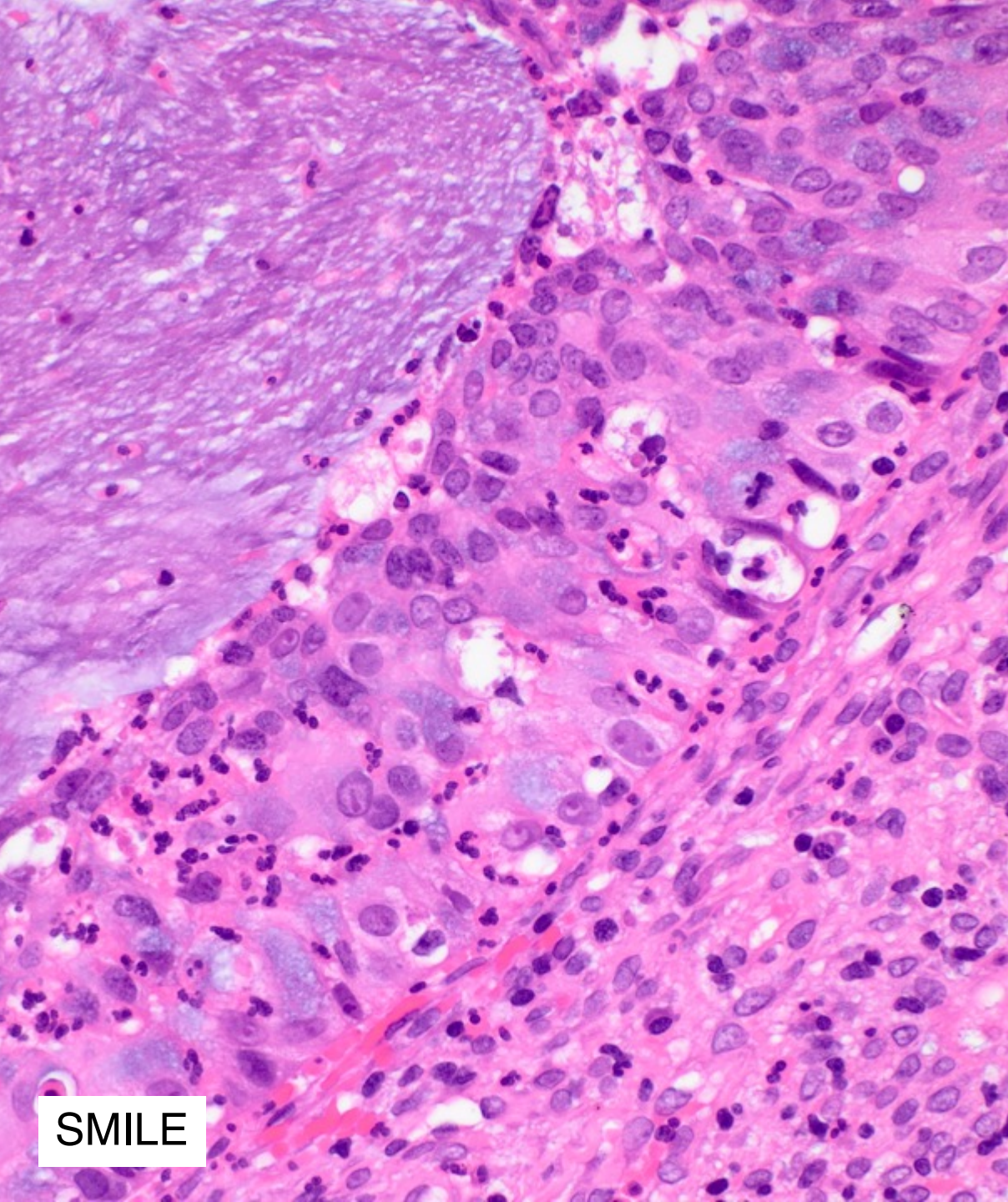




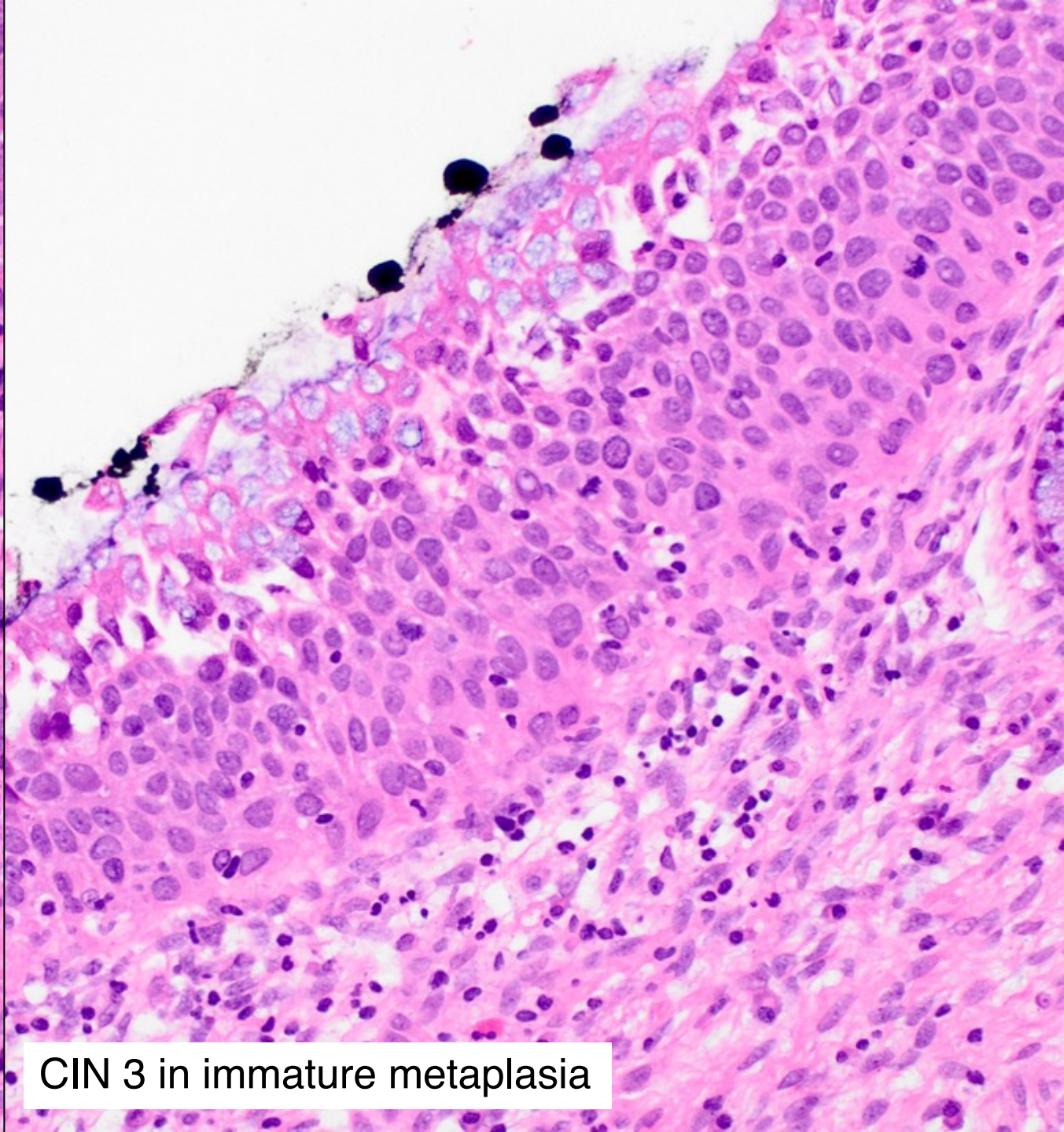


p16



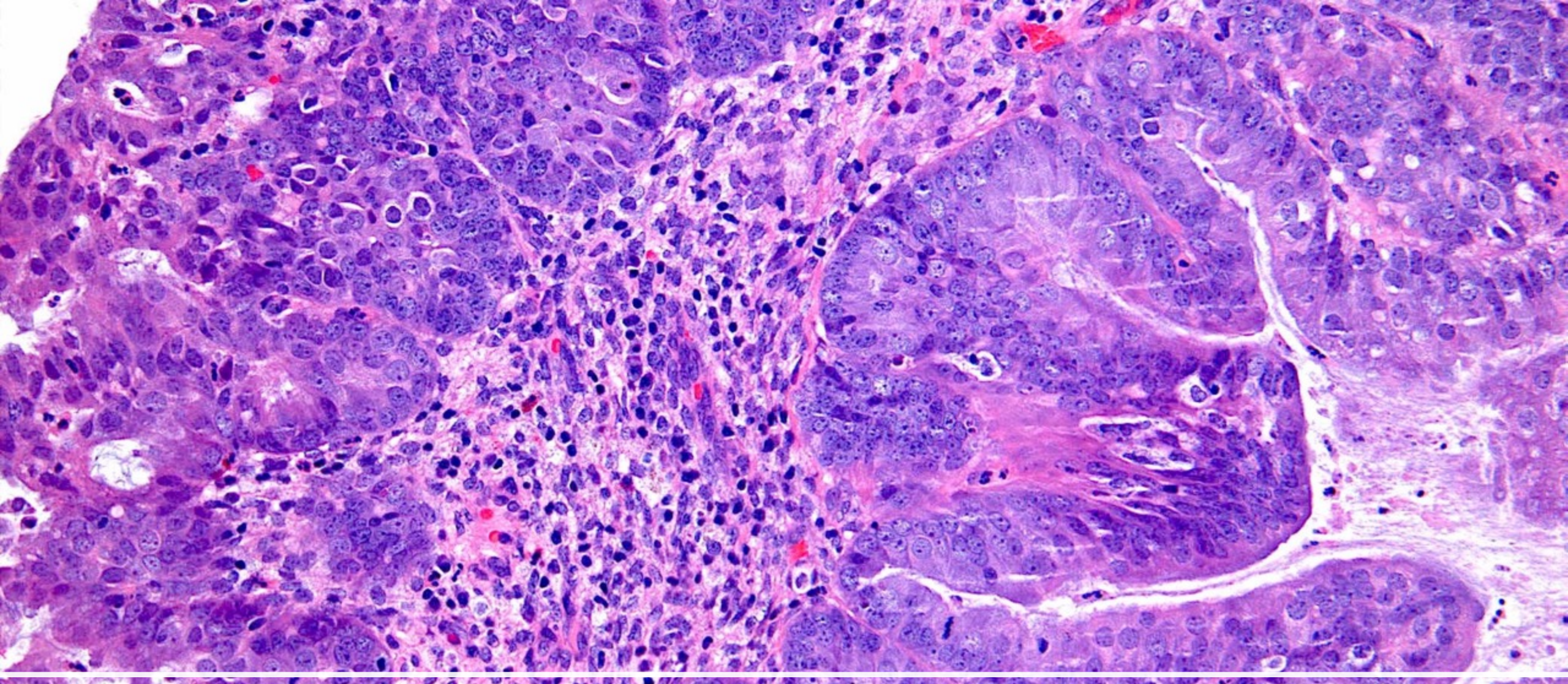


SMILE

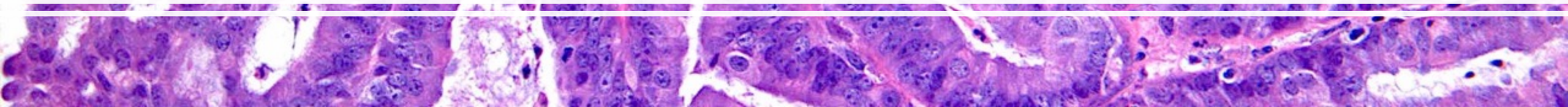


CIN 3 in immature metaplasia

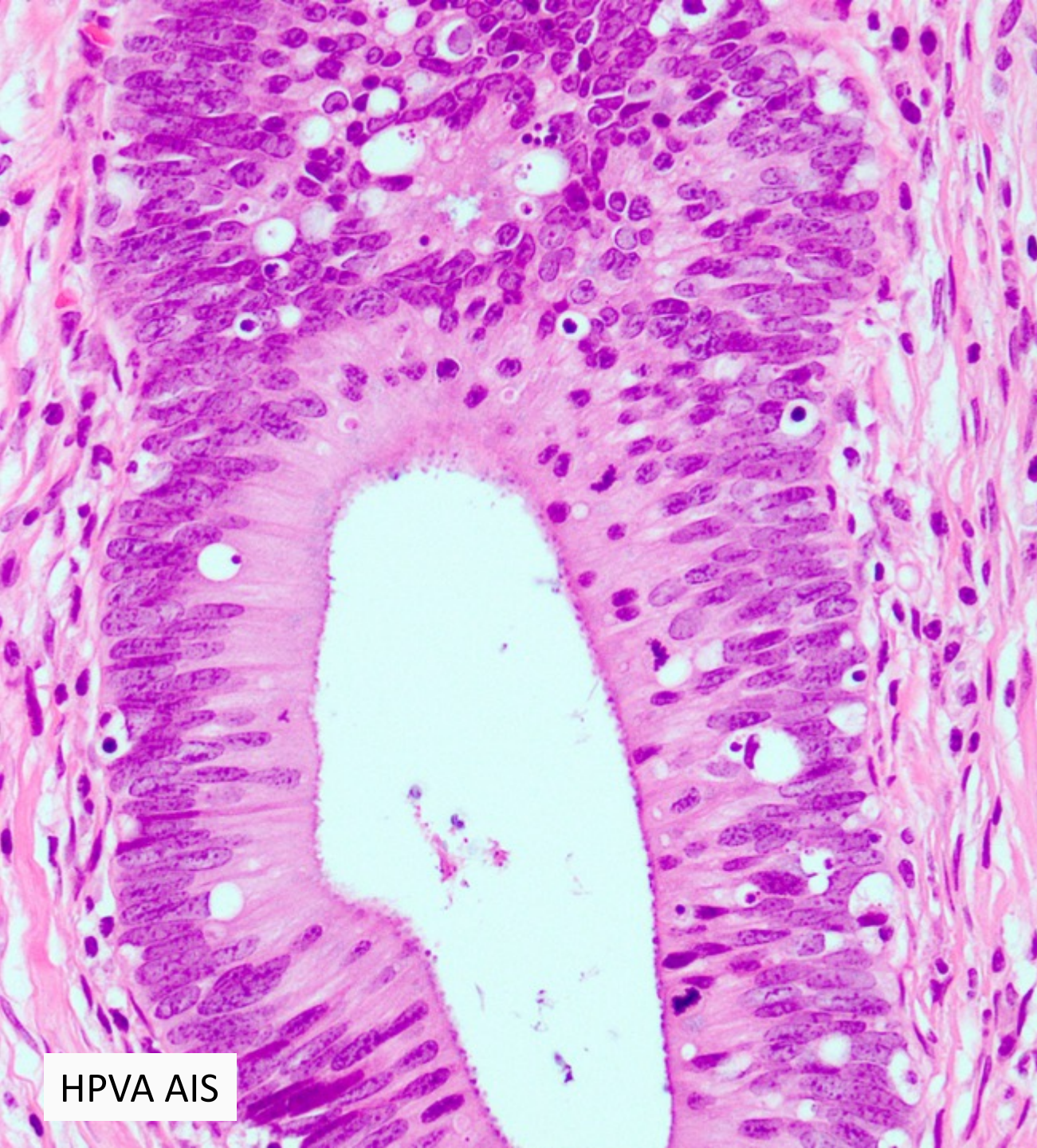



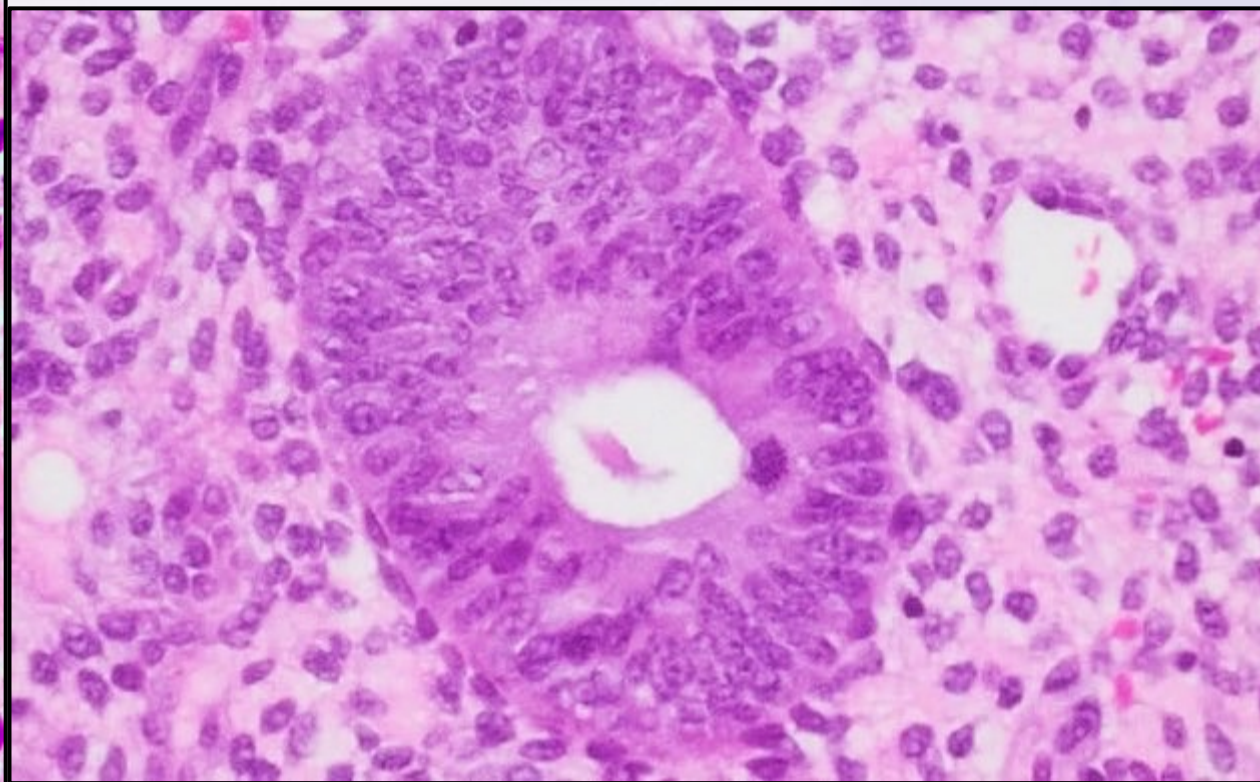
**Endometrioid adenocarcinoma**







HPVA AIS

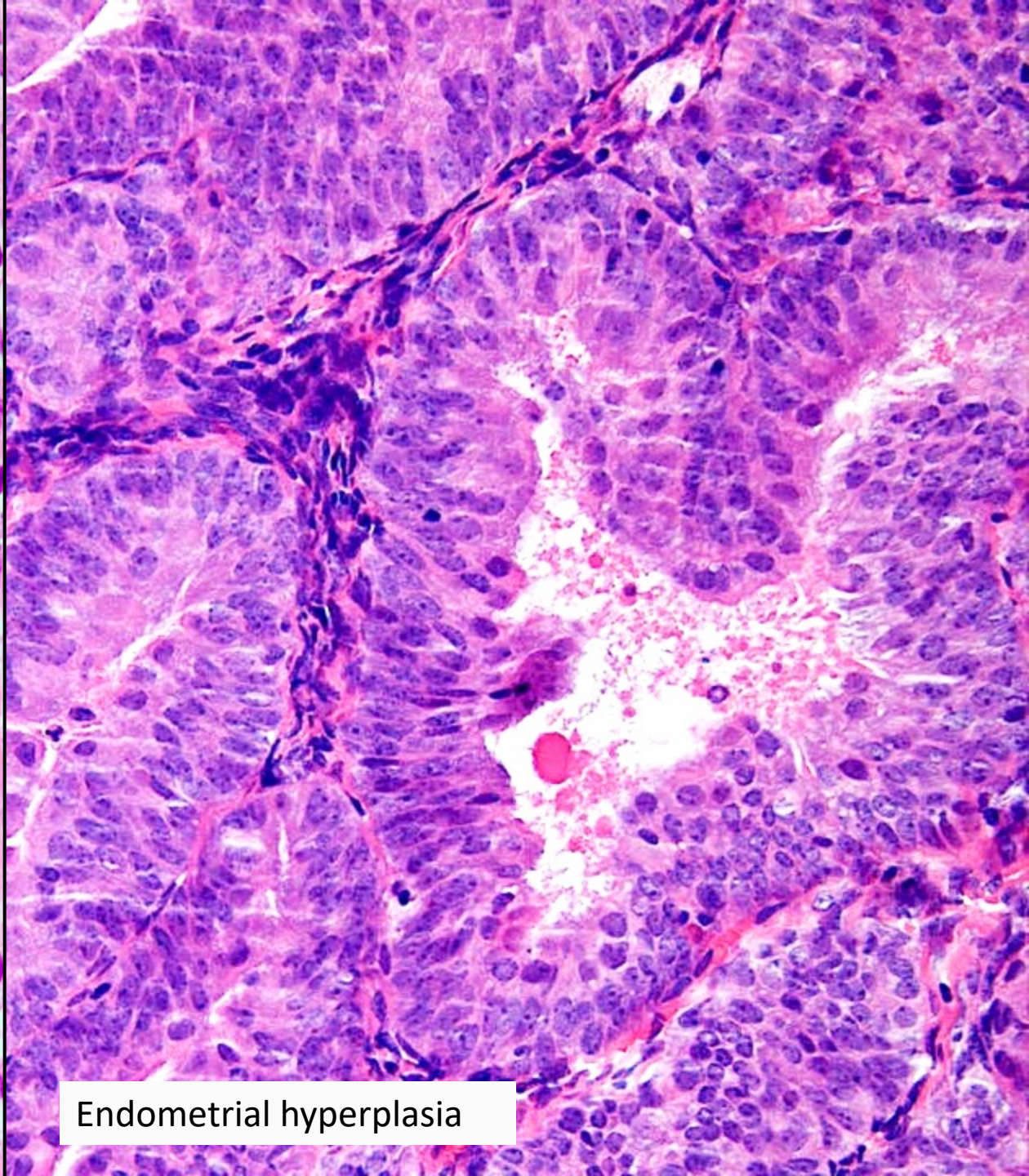


Normal proliferative  
endometrium



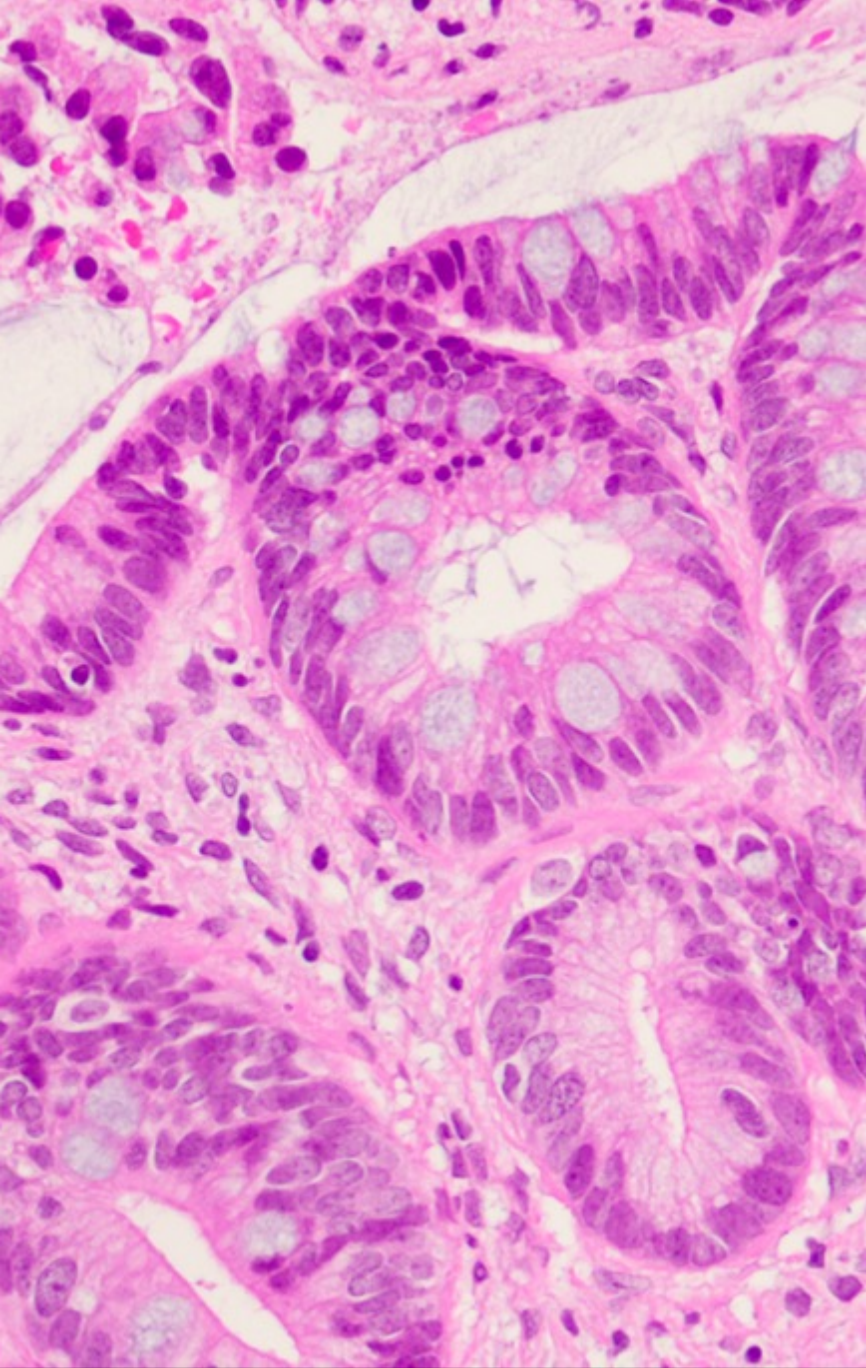


HPVA AIS

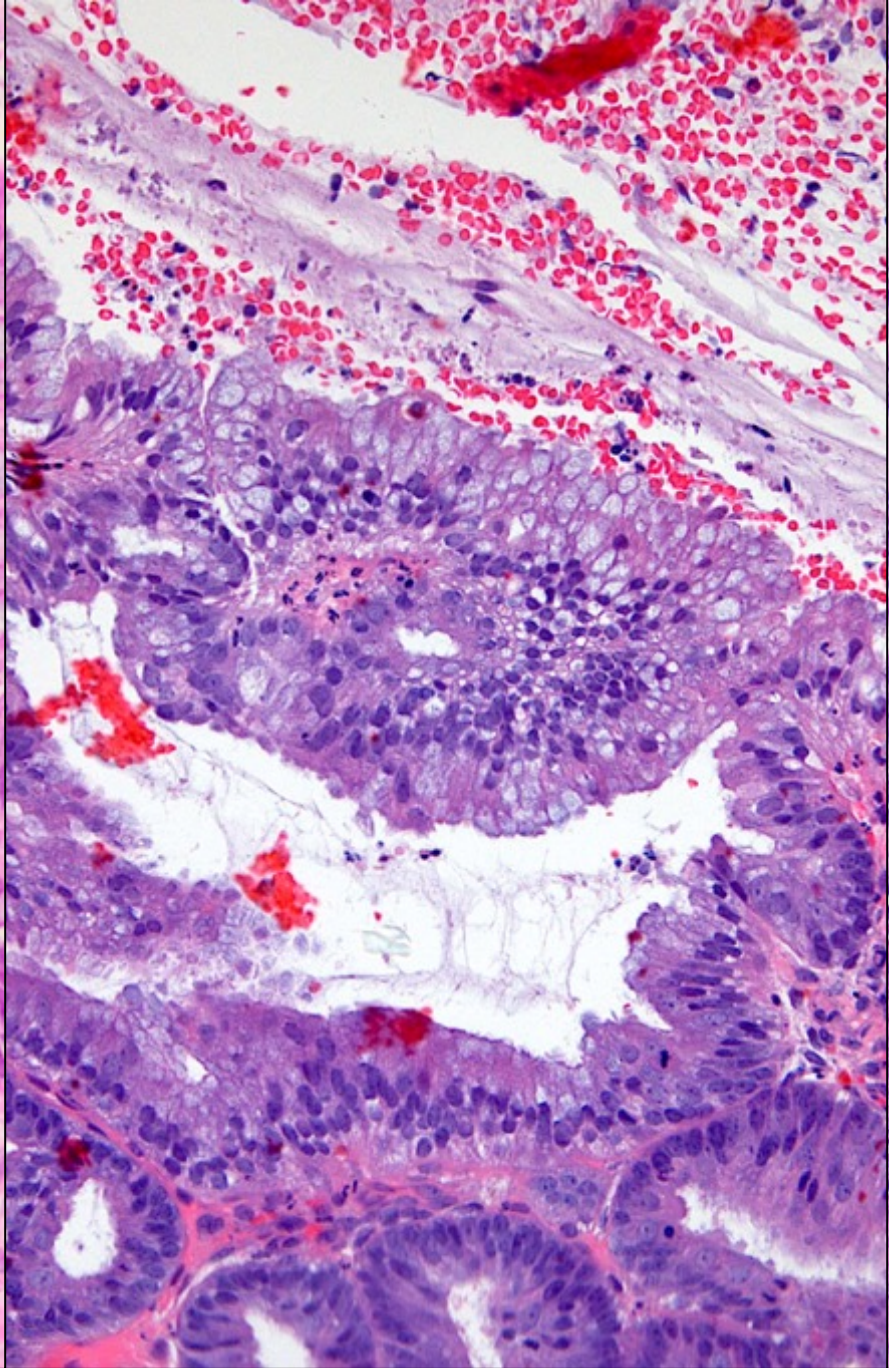


Endometrial hyperplasia

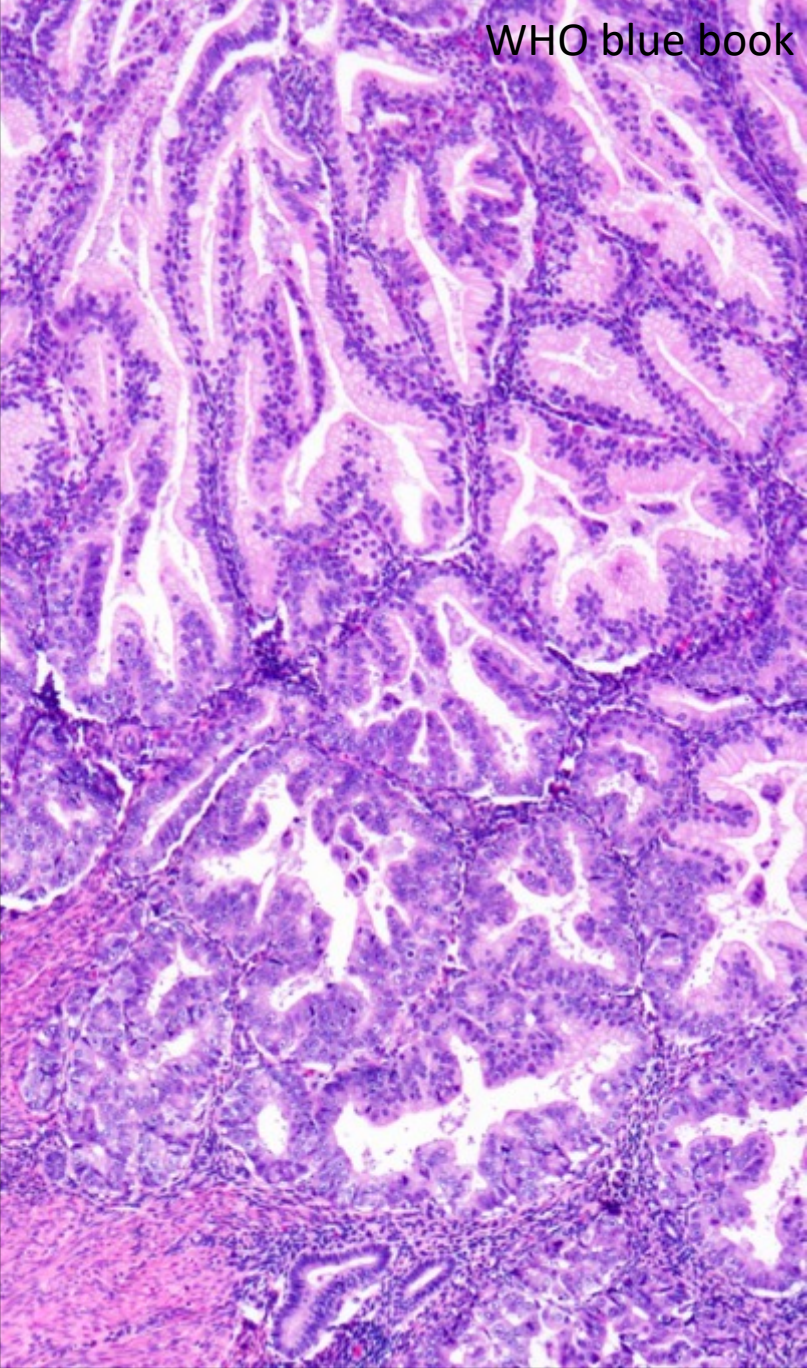




HPVA AIS, intestinal differentiation

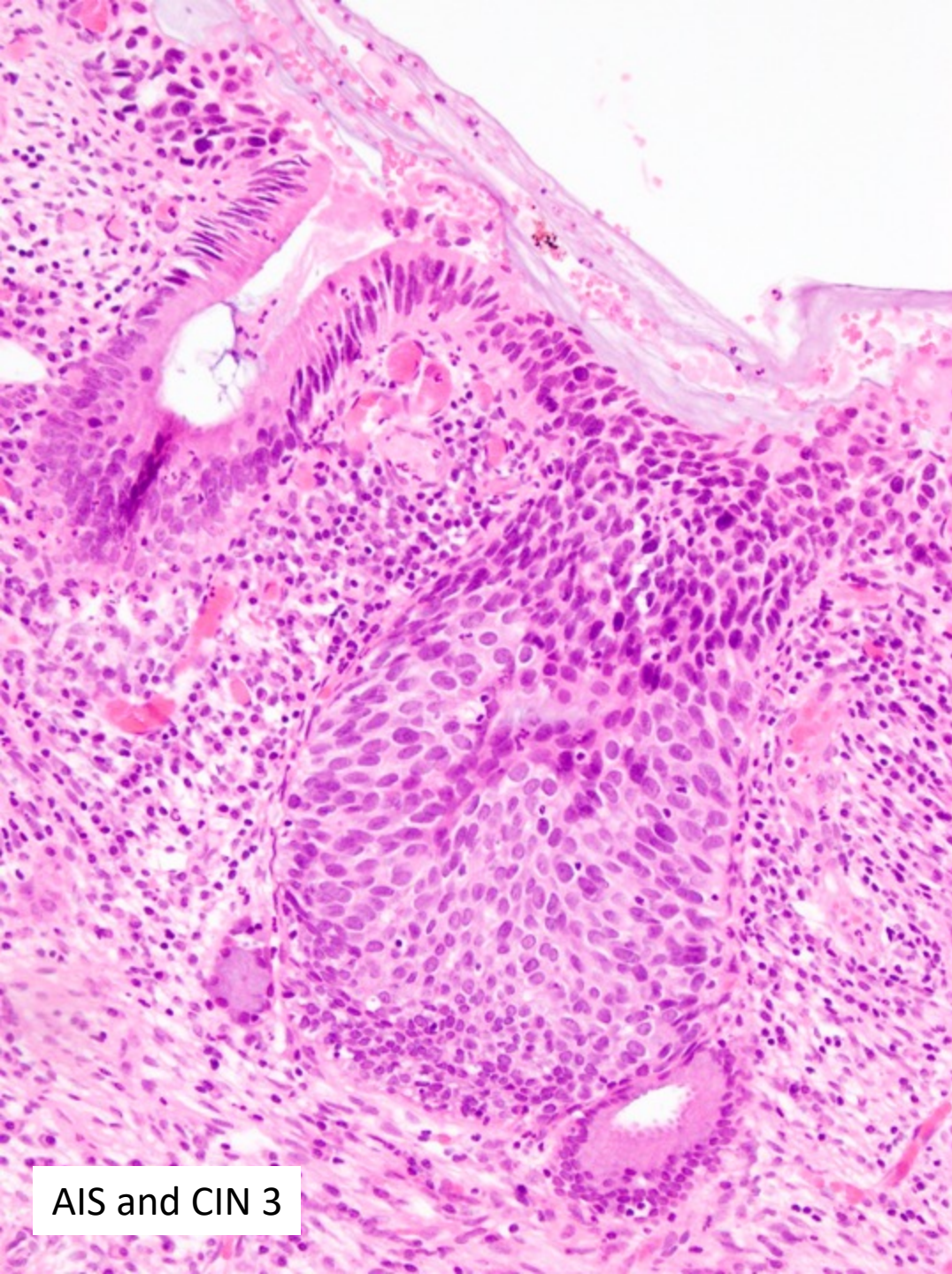


Endometrioid adenocarcinoma

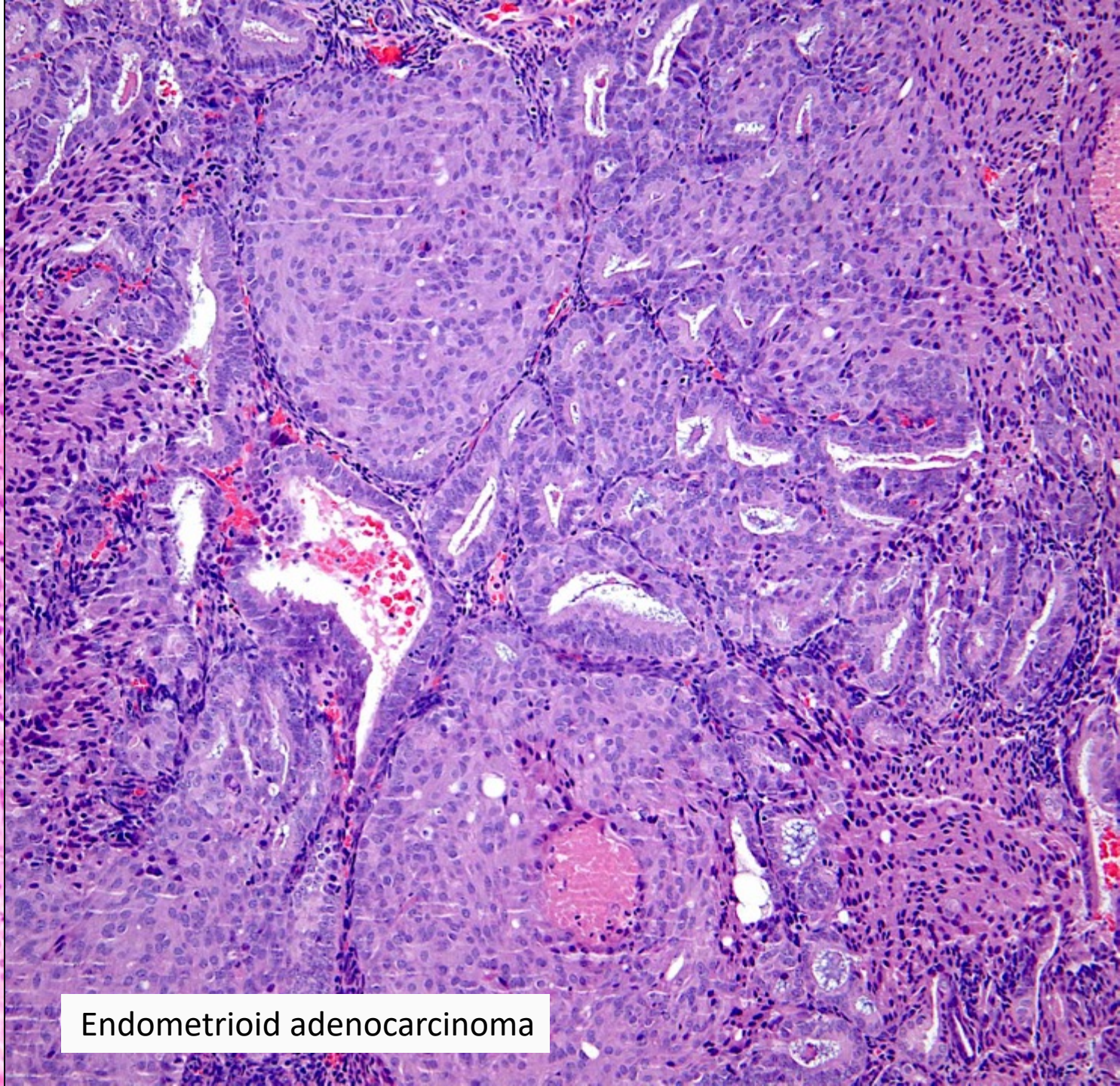


Endometrial gastric-type adenoca



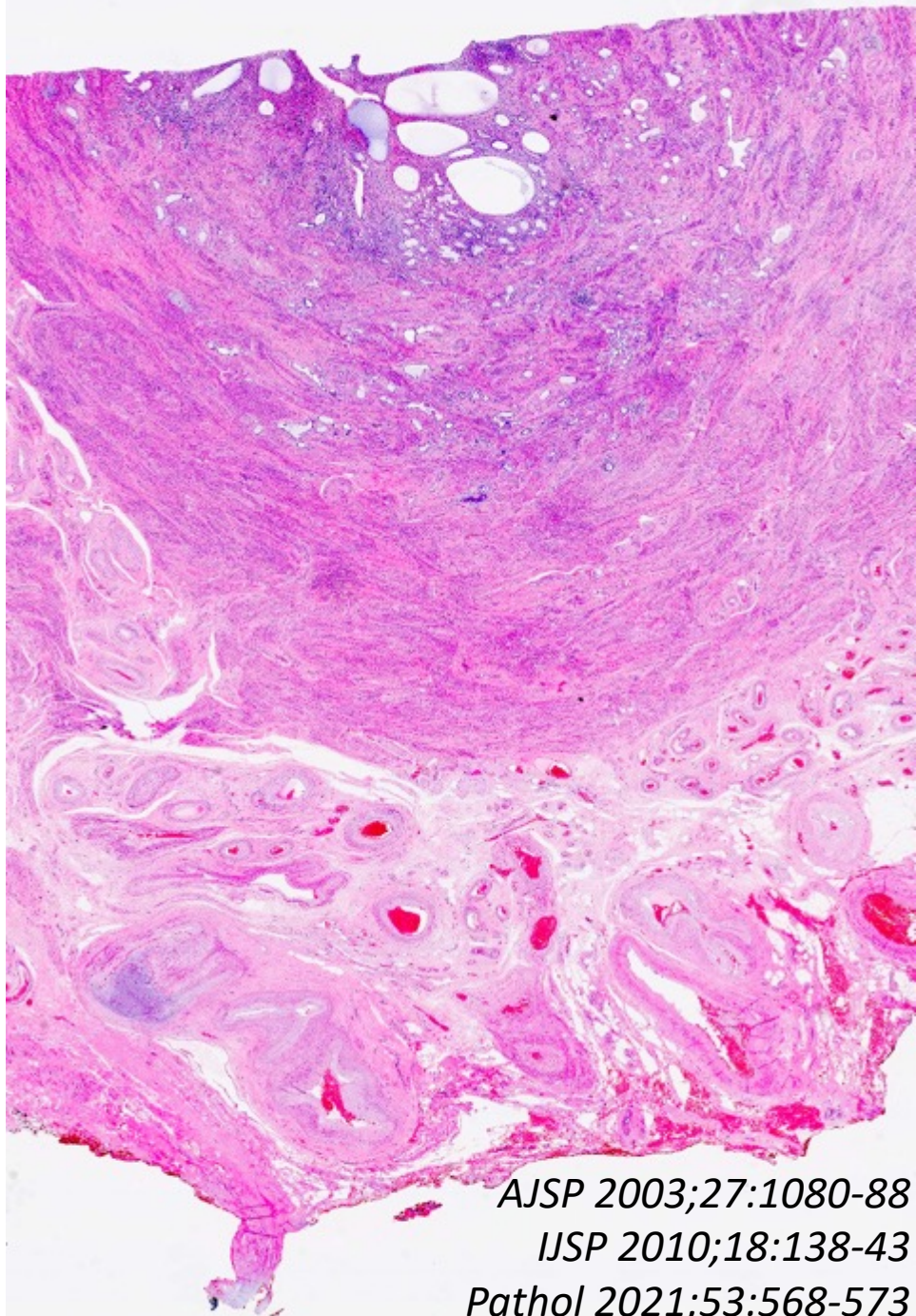


AIS and CIN 3

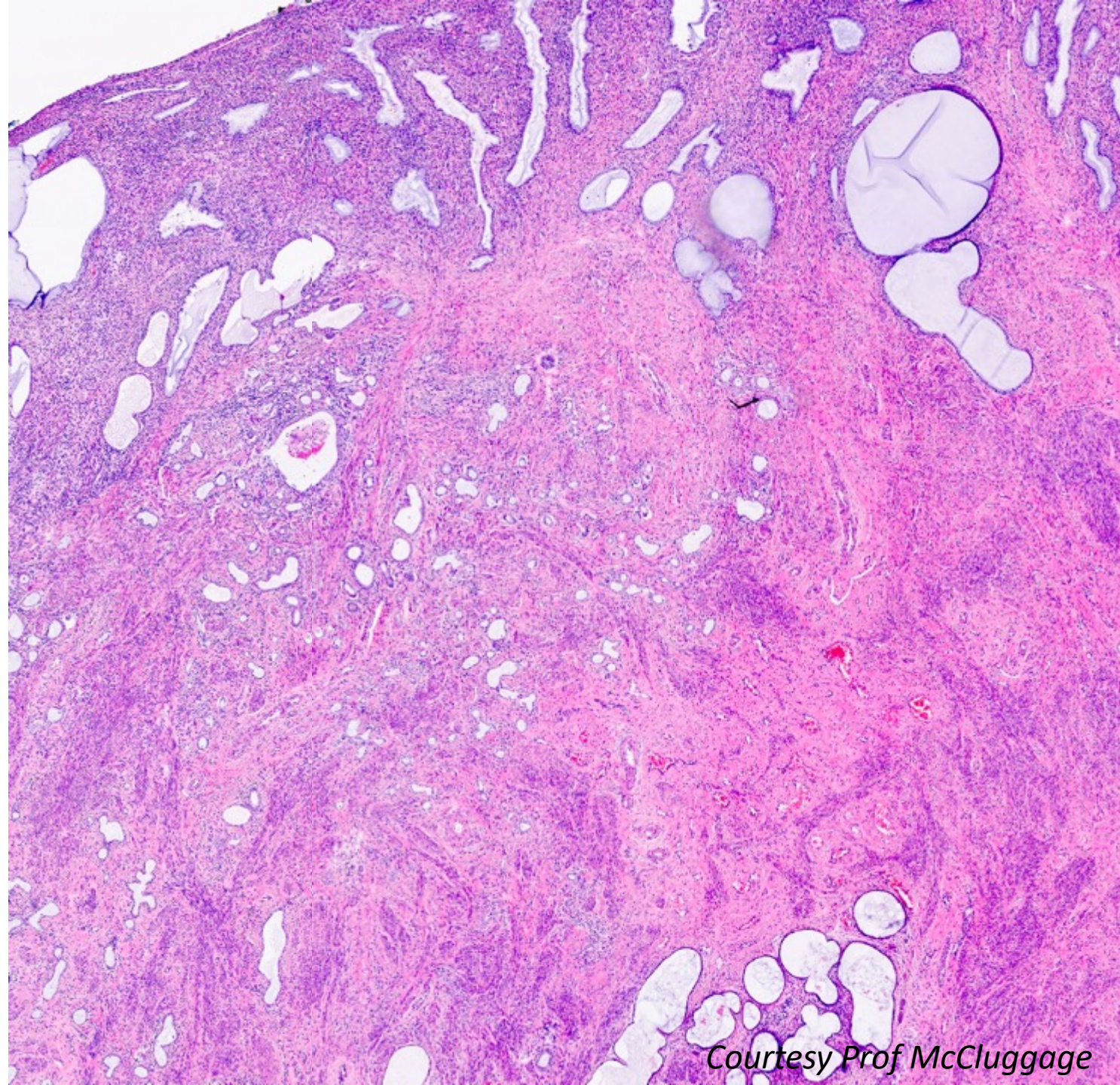


Endometrioid adenocarcinoma



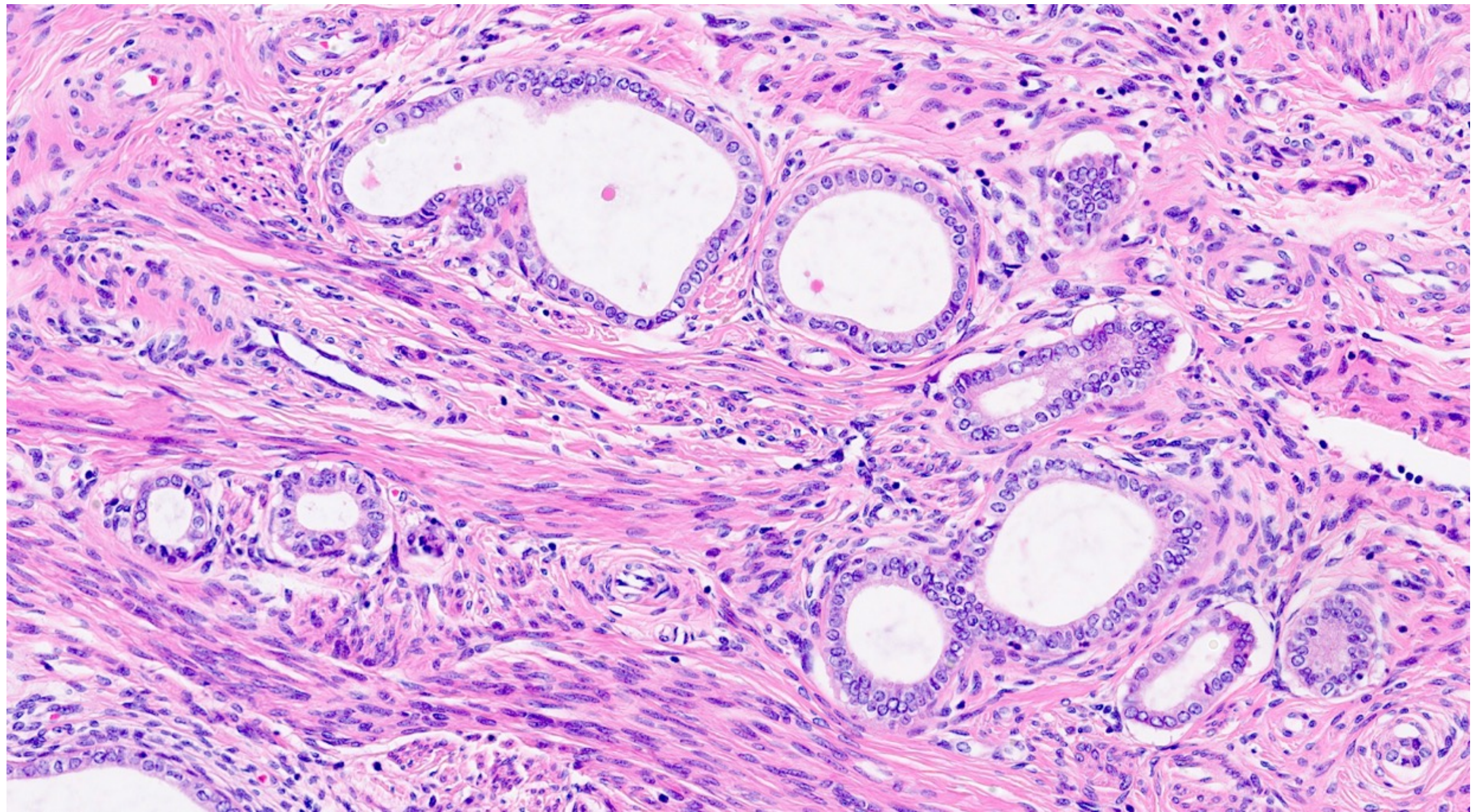


*AJSP 2003;27:1080-88*  
*IJSP 2010;18:138-43*  
*Pathol 2021;53:568-573*



*Courtesy Prof McCluggage*







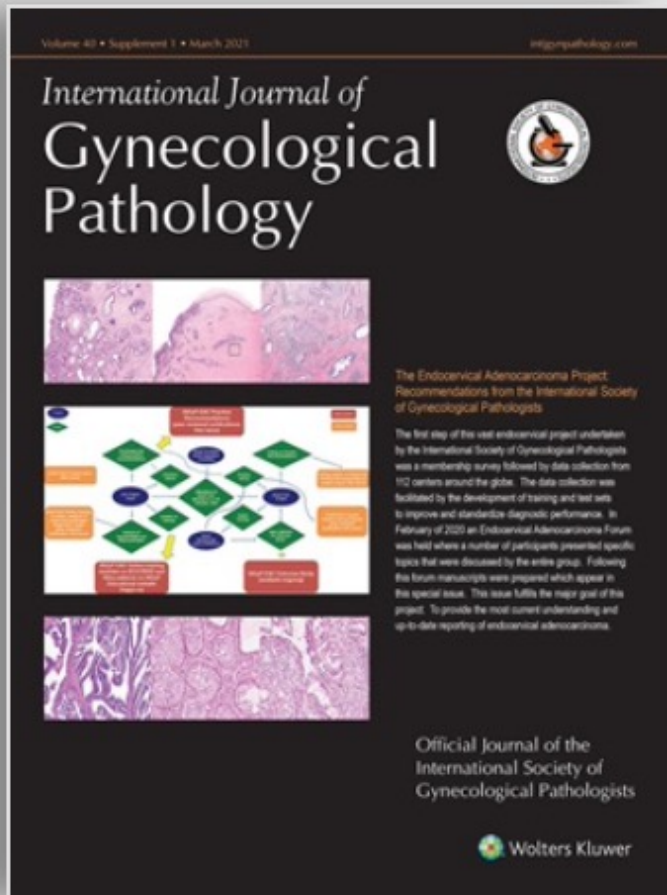
# ISGyP Endocervical Adenocarcinoma Project

## March 2021 - Volume 40 - Issue 2, Supplement 1

Open access, 9 individual papers

Consensus recommendations, best practice guidelines

- Distinction of in situ from invasive adenocarcinoma
- Silva patterns of invasion
- Grading of endocervical adenocarcinoma
- **Tumour typing including immunohistochemistry**
- Staging
- Predictive biomarkers
- Intraoperative evaluation





**ISGyP 2021  
Endocervical  
Adenocarcinoma  
Project**



**ISGyP 2018  
Endometrial  
Cancer  
Project**

Article

**Tumor Typing of Endocervical Adenocarcinoma:  
Contemporary Review and Recommendations From the  
International Society of Gynecological Pathologists**

Simona Stolnicu, M.D., Kay J. Park, M.D., Takako Kiyokawa, M.D., Esther Oliva, M.D.,  
W. Glenn McCluggage, M.D., and Robert A. Soslow, M.D.

*IJGP 2021;40:S75-91*

**Guidelines to Aid in the Distinction of Endometrial and  
Endocervical Carcinomas, and the Distinction of Independent  
Primary Carcinomas of the Endometrium and Adnexa From  
Metastatic Spread Between These and Other Sites**

Colin J.R. Stewart, F.R.C.P.A., Christopher P. Crum, M.D., W. Glenn McCluggage, F.R.C.Path.,  
Kay J. Park, M.D., Joanne K. Rutgers, M.D., Esther Oliva, M.D., Anais Malpica, M.D.,  
Vinita Parkash, M.D., Xavier Matias-Guiu, M.D., and Brigitte M. Ronnett, M.D.

*IJGP 2018;38:S75-92*





If mucin deplete with apical mitoses and apoptoses  
→ **UNLIKELY ENDOMETRIOID ADENOCARCINOMA**  
→ **Invariably HPV-associated adenocarcinoma**



## HPVA AIS

Apical mitoses, apoptoses

Hyperchromasia

Goblet cells

**p16 diffuse**

**ER/PR -**

**Vimentin -**

**HPV-ISH +**

*Caveat: Rare positive staining  
ER>PR*

## LG Endometrioid adenocarcinoma

Often inconspicuous mitoses

Bland nuclei

Squamous/mucinous diff<sup>n</sup>

Atypical hyperplasia

Stromal foam cells

**p16 non-diffuse**

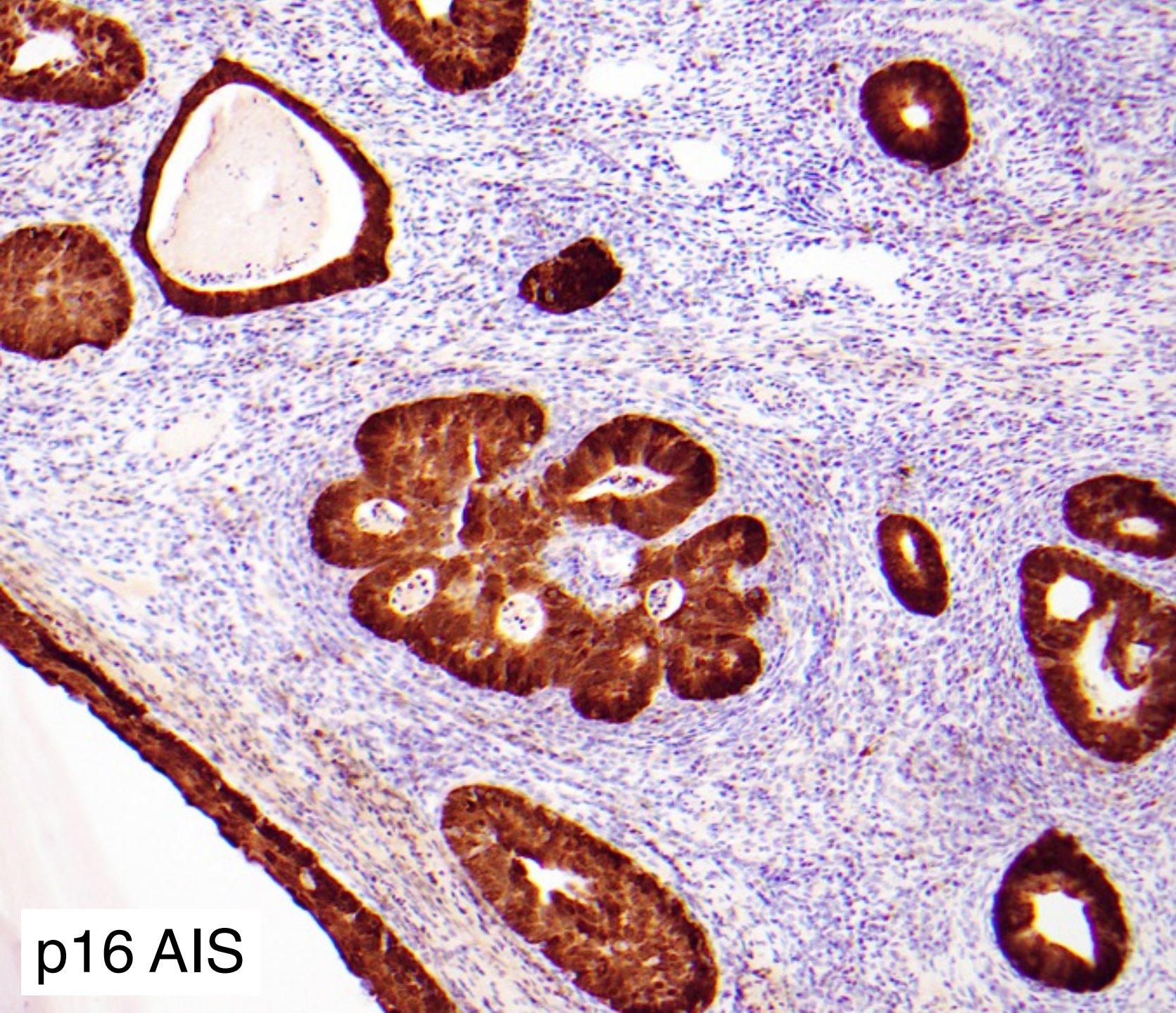
**ER/PR +**

**Vimentin +**

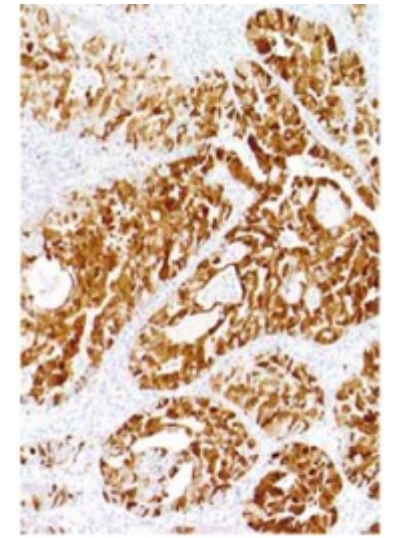
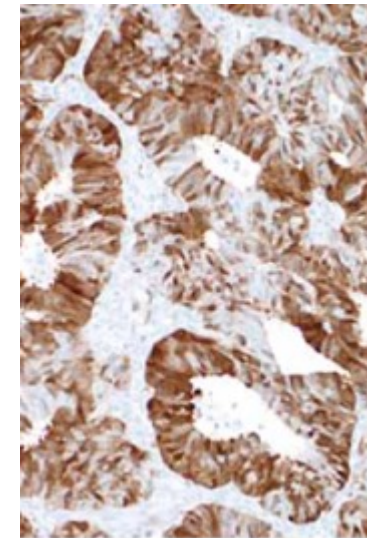
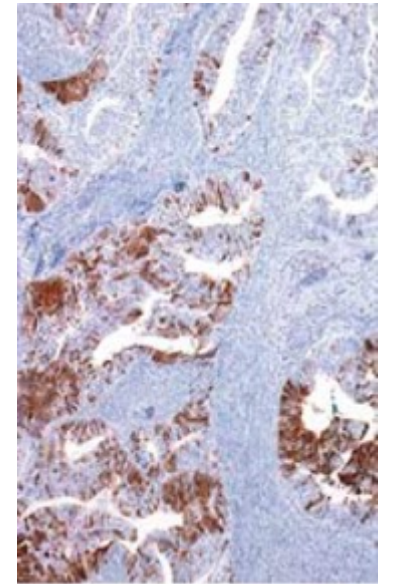
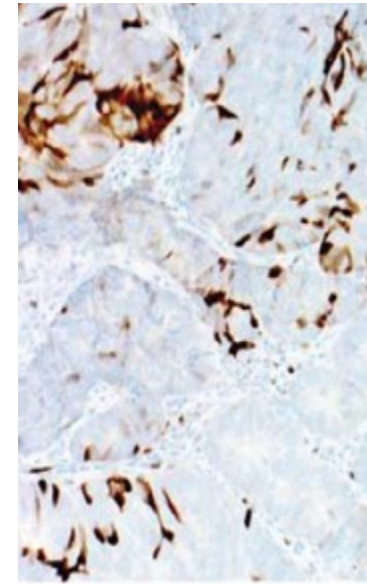
**MMRd**

*Caveat: HG endometrioid  
carcinoma*





p16 AIS

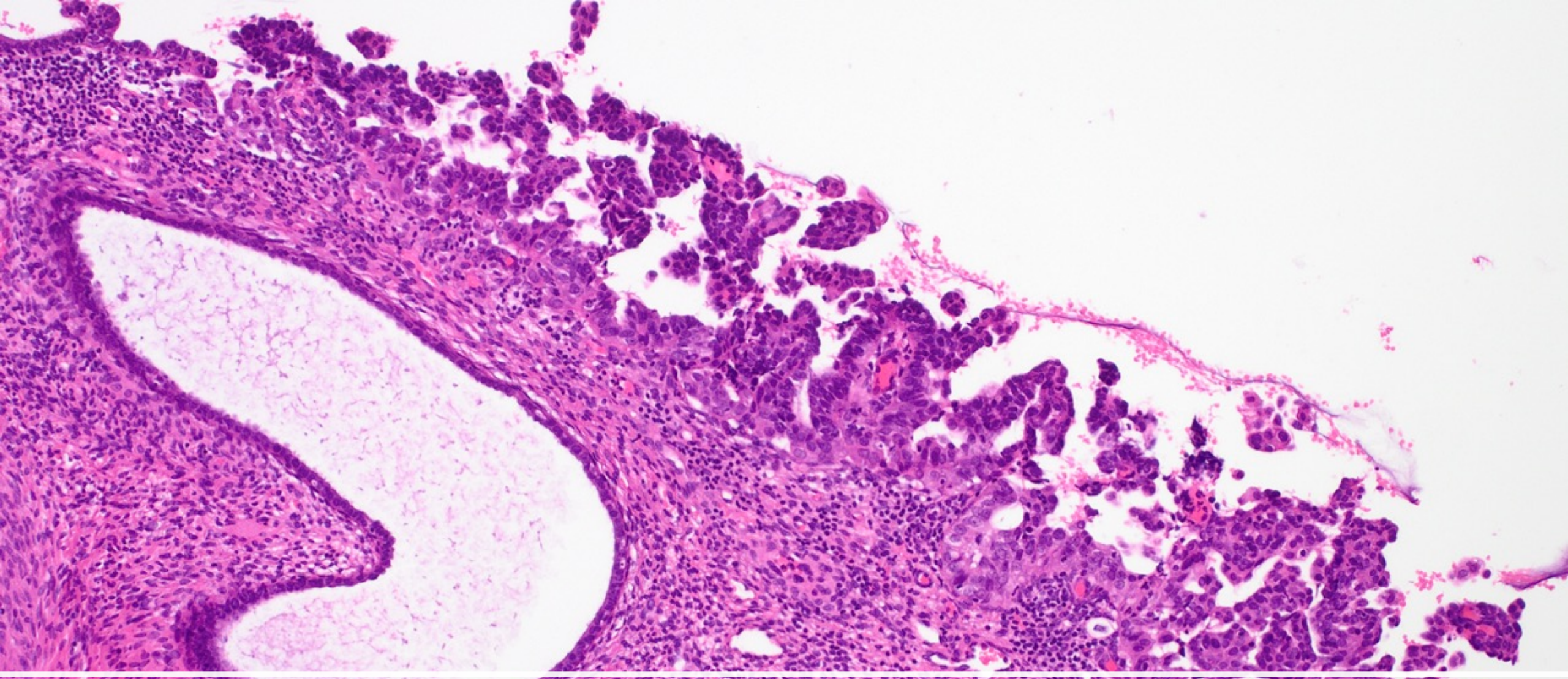


*IJGP 2018;38:S75-92*

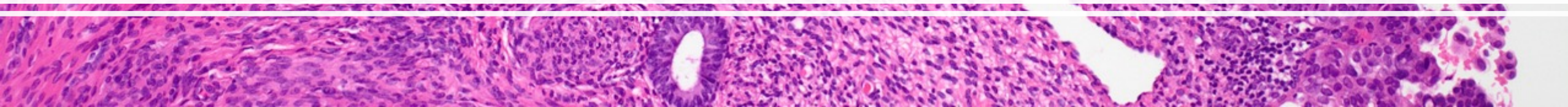
**Endometrioid**



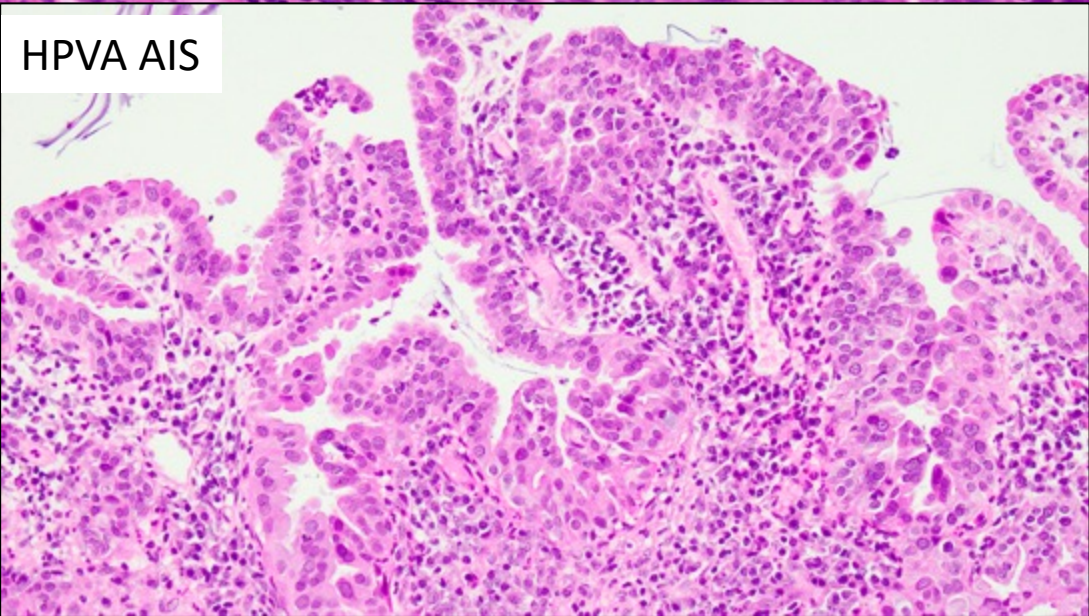
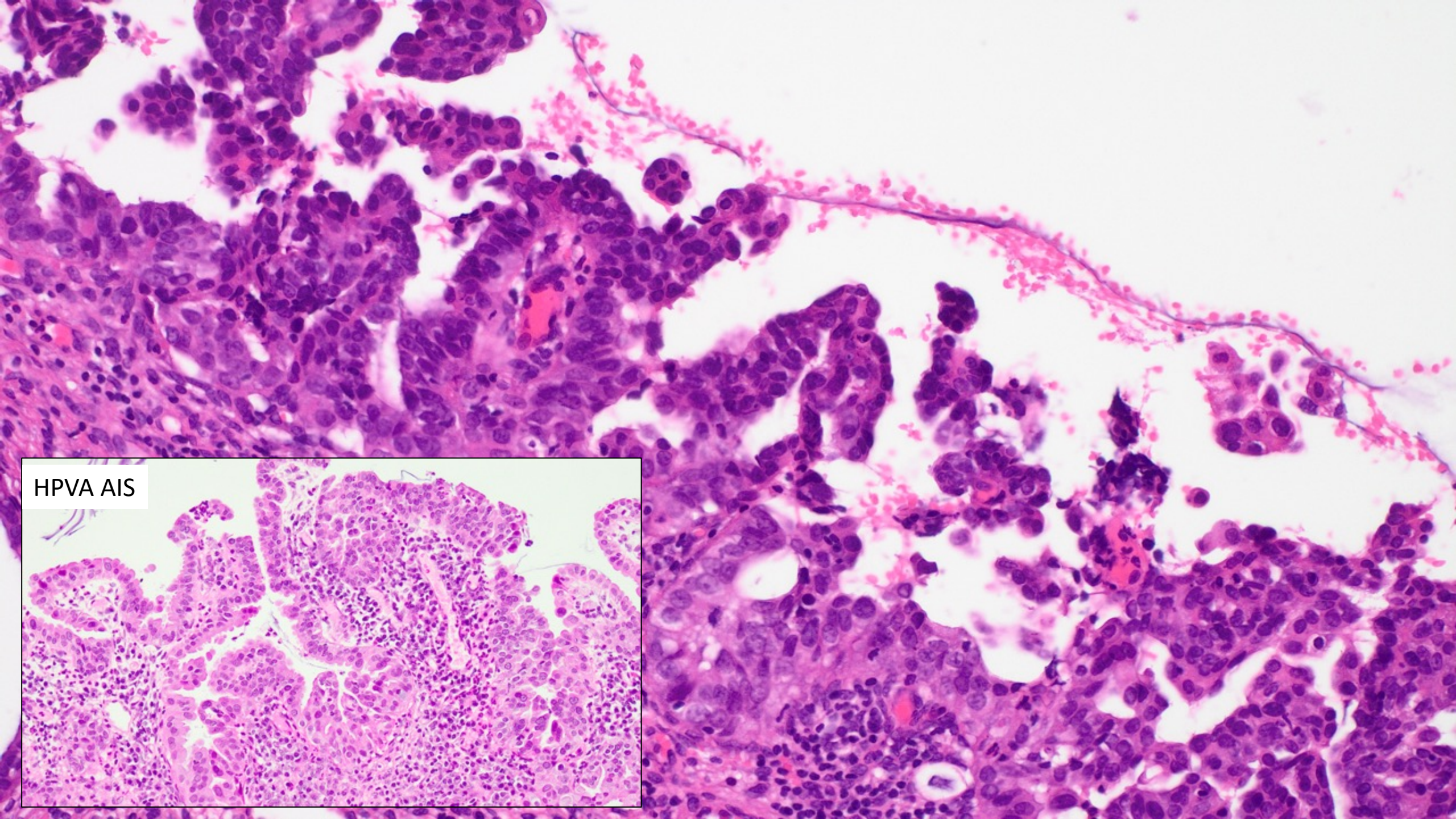




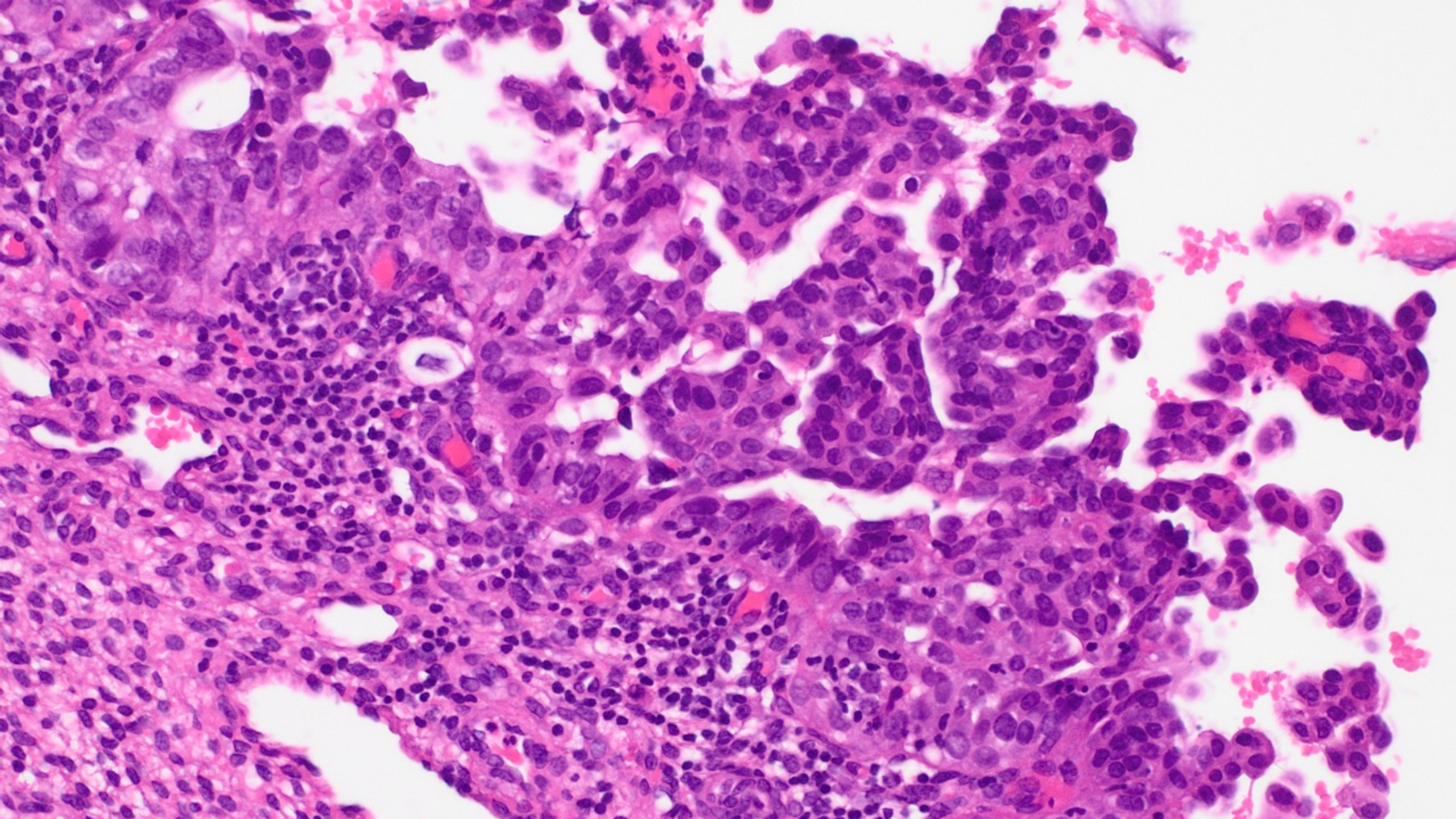
**Serous carcinoma**



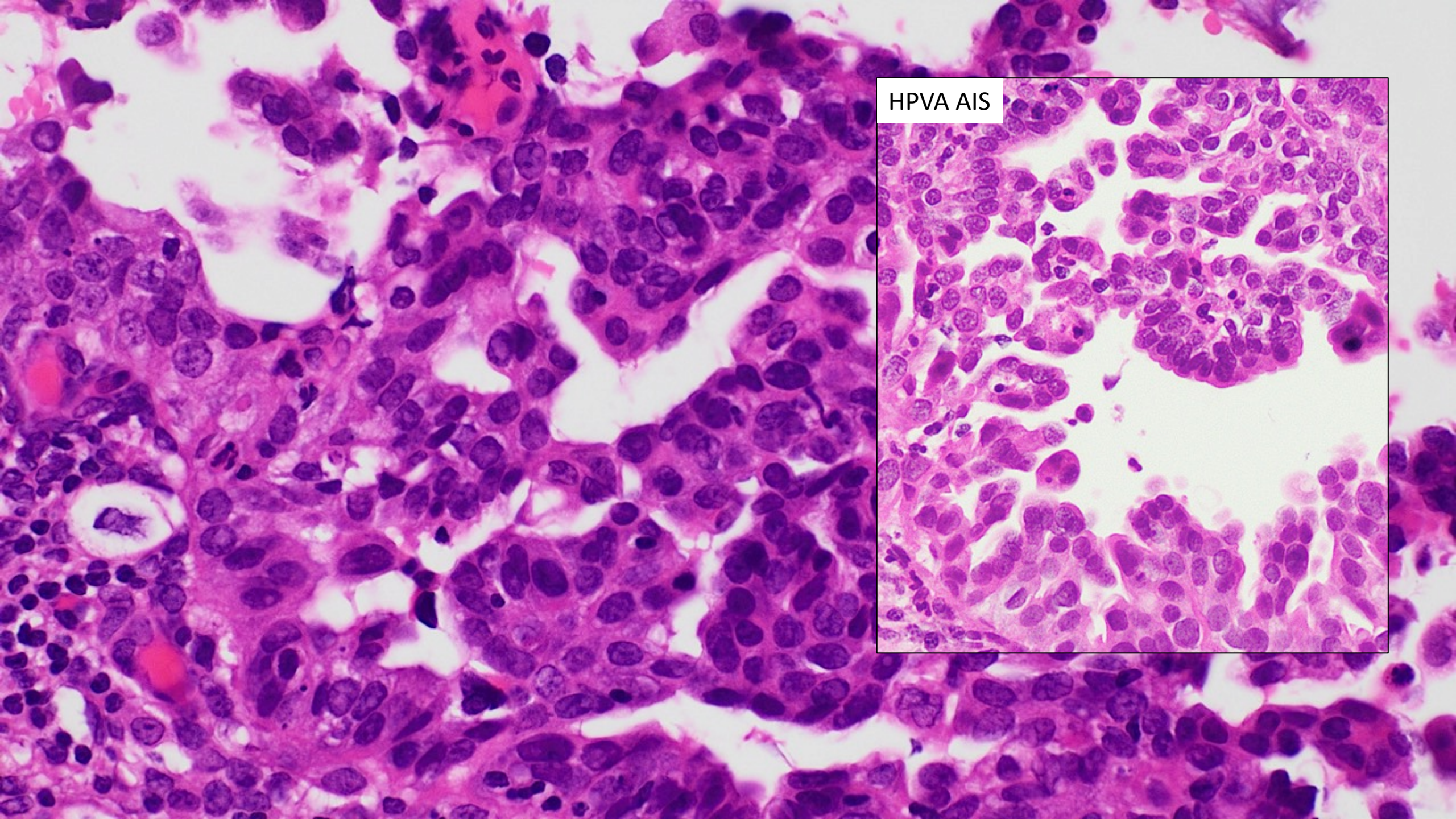






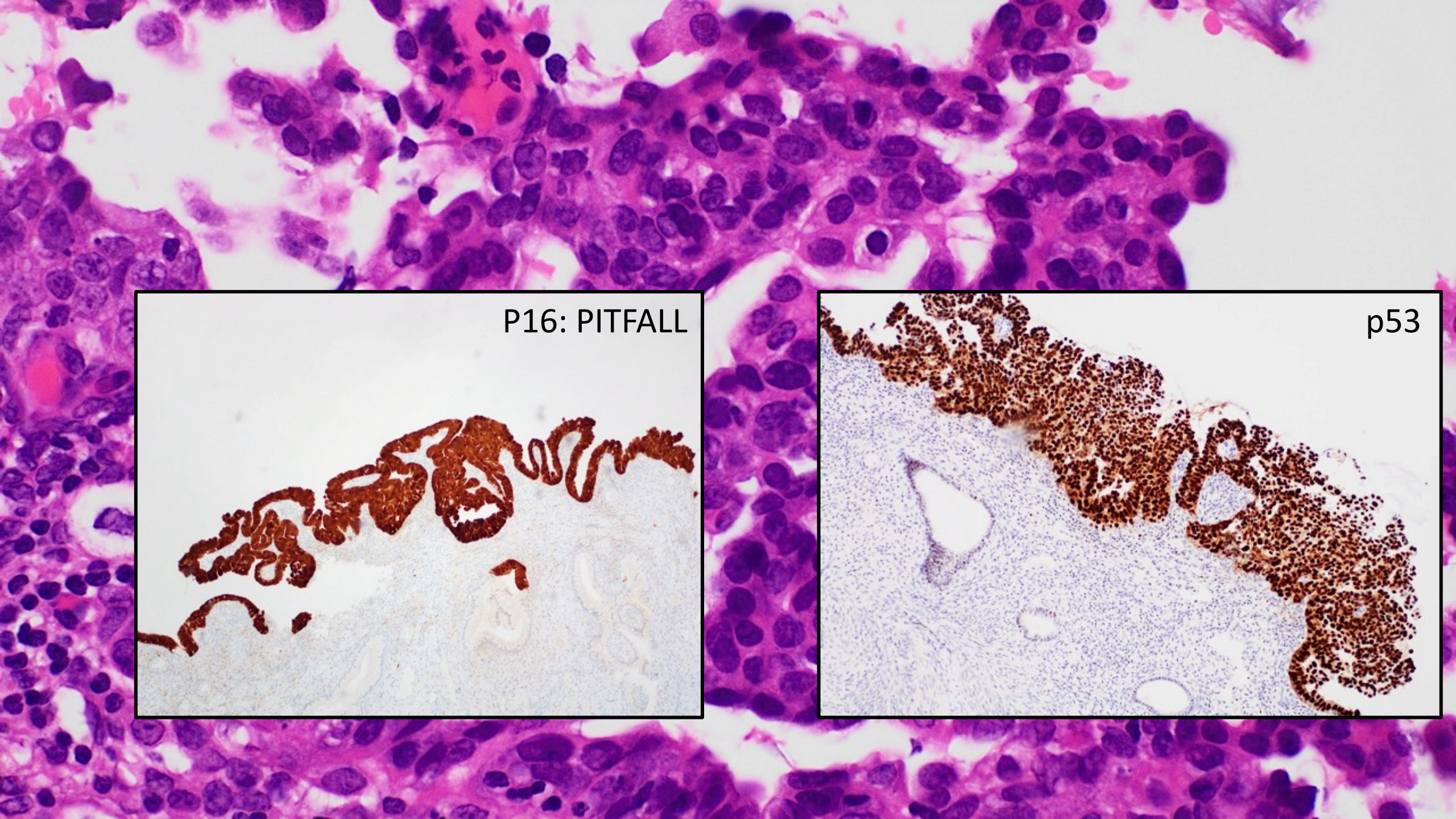




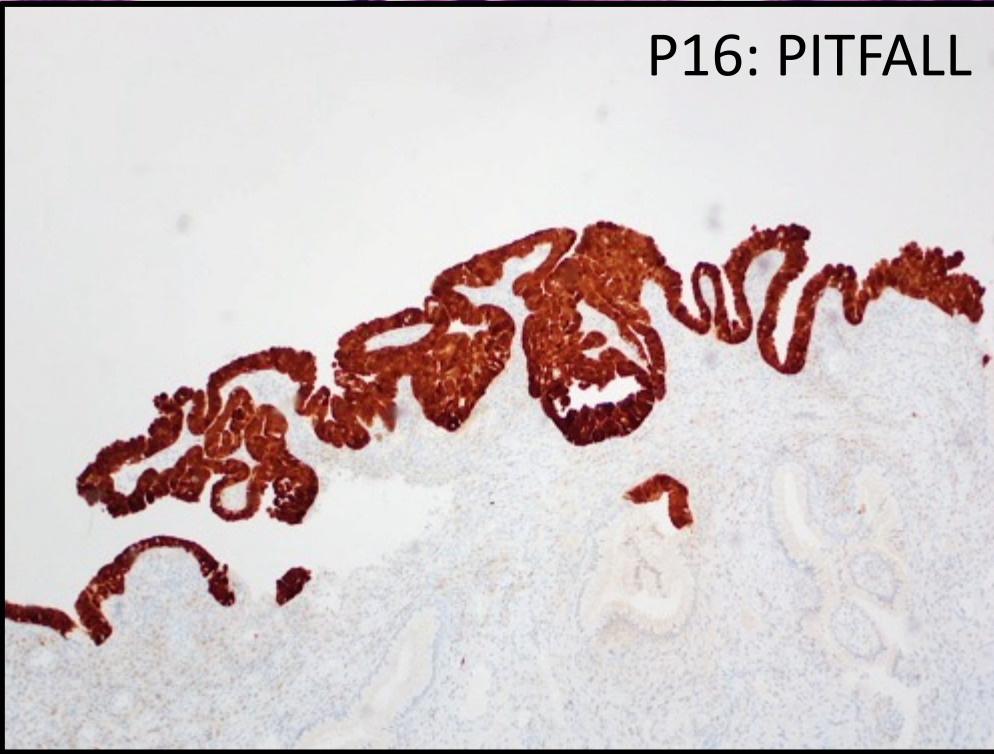

HPVA AIS

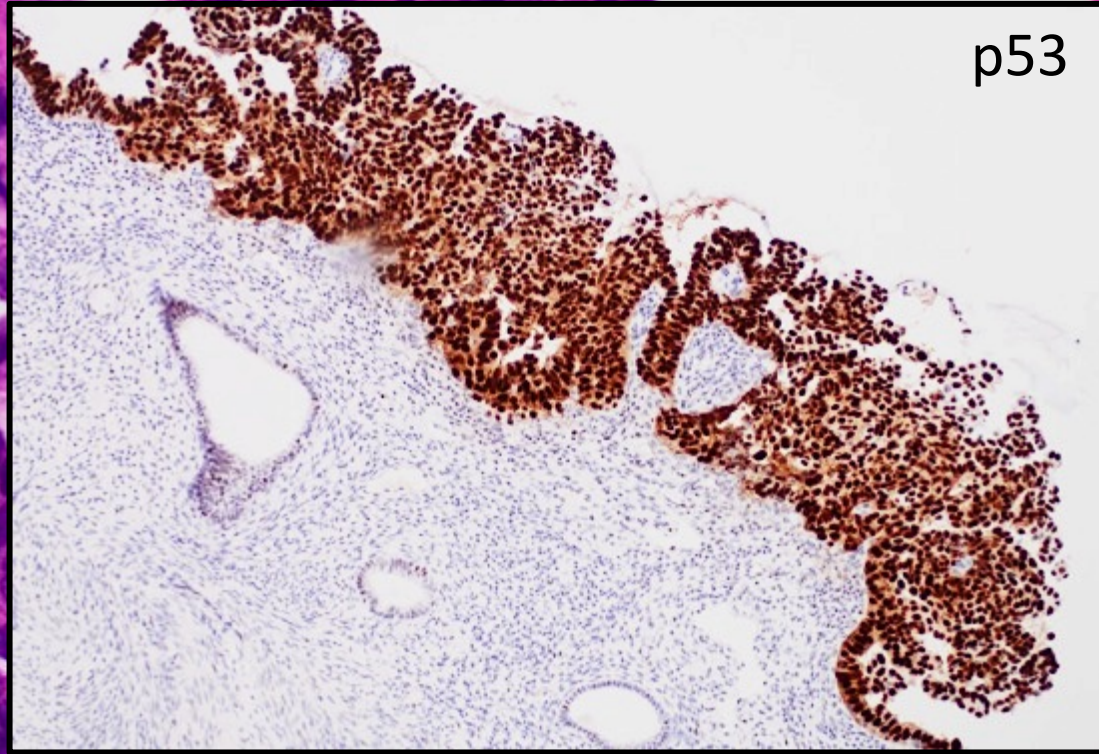




P16: PITFALL



p53





# WHO 2020

## HPV-associated adenocarcinoma

Usual type ~ 75% all adenocarcinoma

- Villoglandular variant

Mucinous type ~ 10% all adenocarcinoma

- Mucinous NOS adenocarcinoma
- Intestinal adenocarcinoma
- Signet-ring cell adenocarcinoma
- Invasive stratified mucinous carcinoma

## HPV-independent adenocarcinoma

Gastric type

Clear cell type

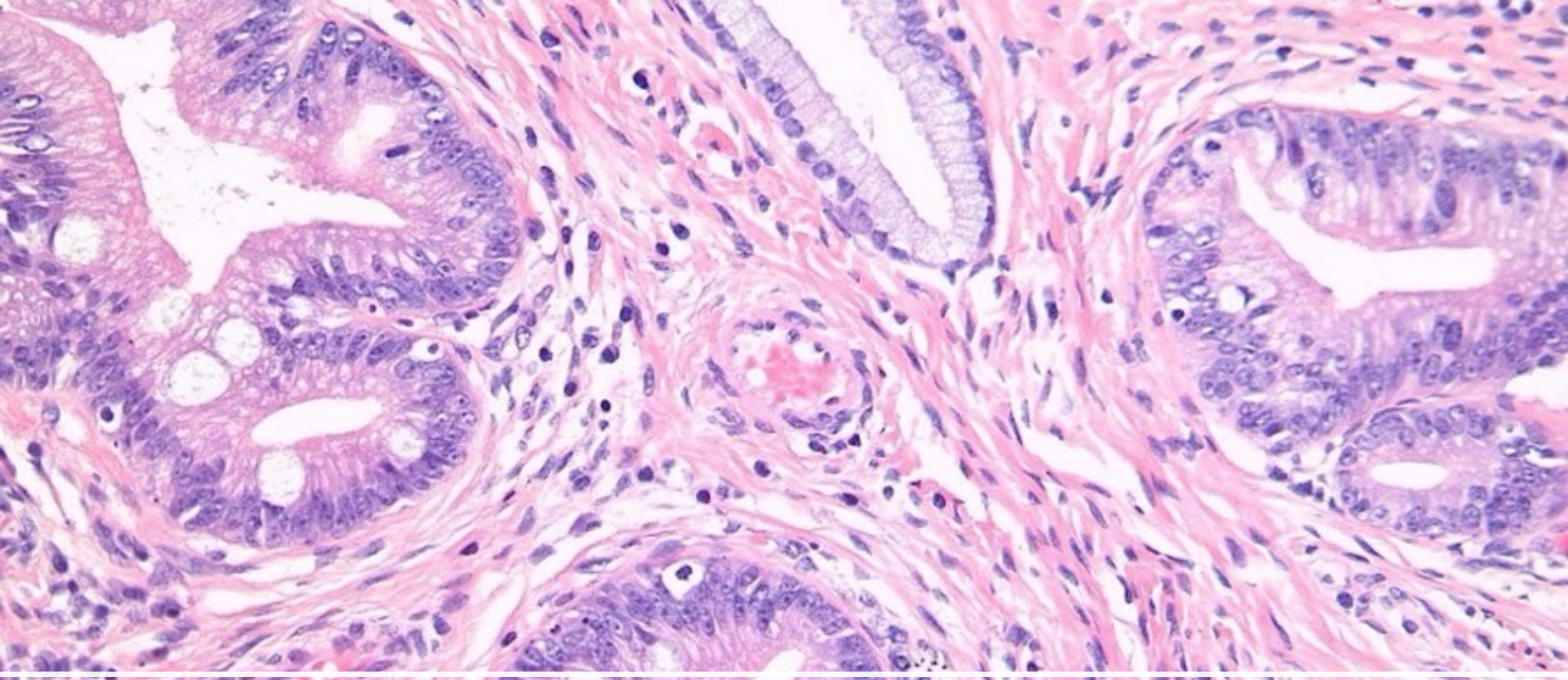
Mesonephric type

Other:

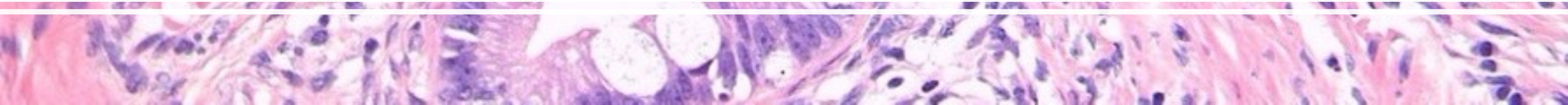- Endometrioid adenocarcinoma
- Carcinoma secondarily involving cervix
- Adenocarcinoma NOS

Serous cancer of cervix removed from 2020 WHO





**HPV-independent AIS**



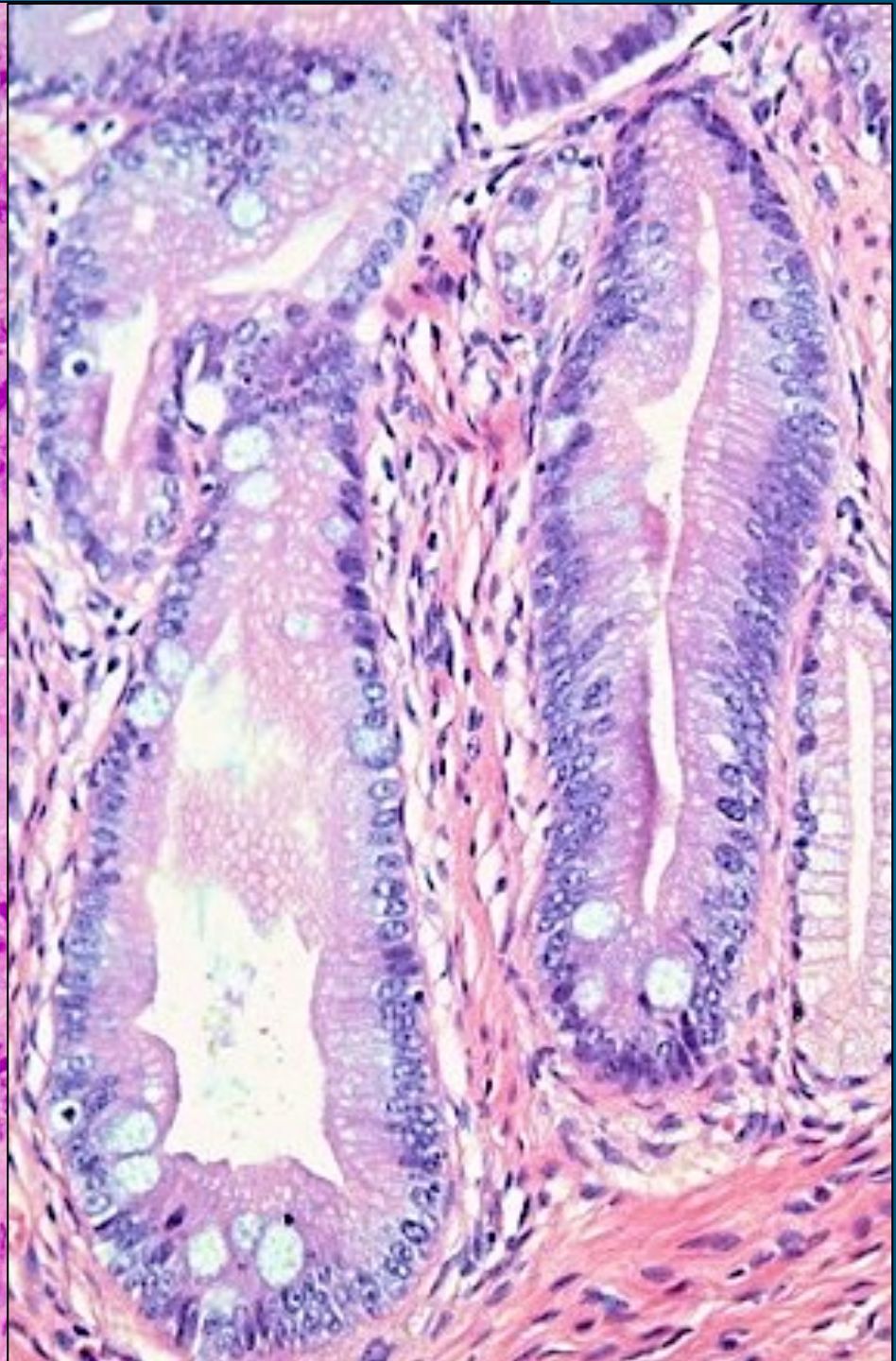
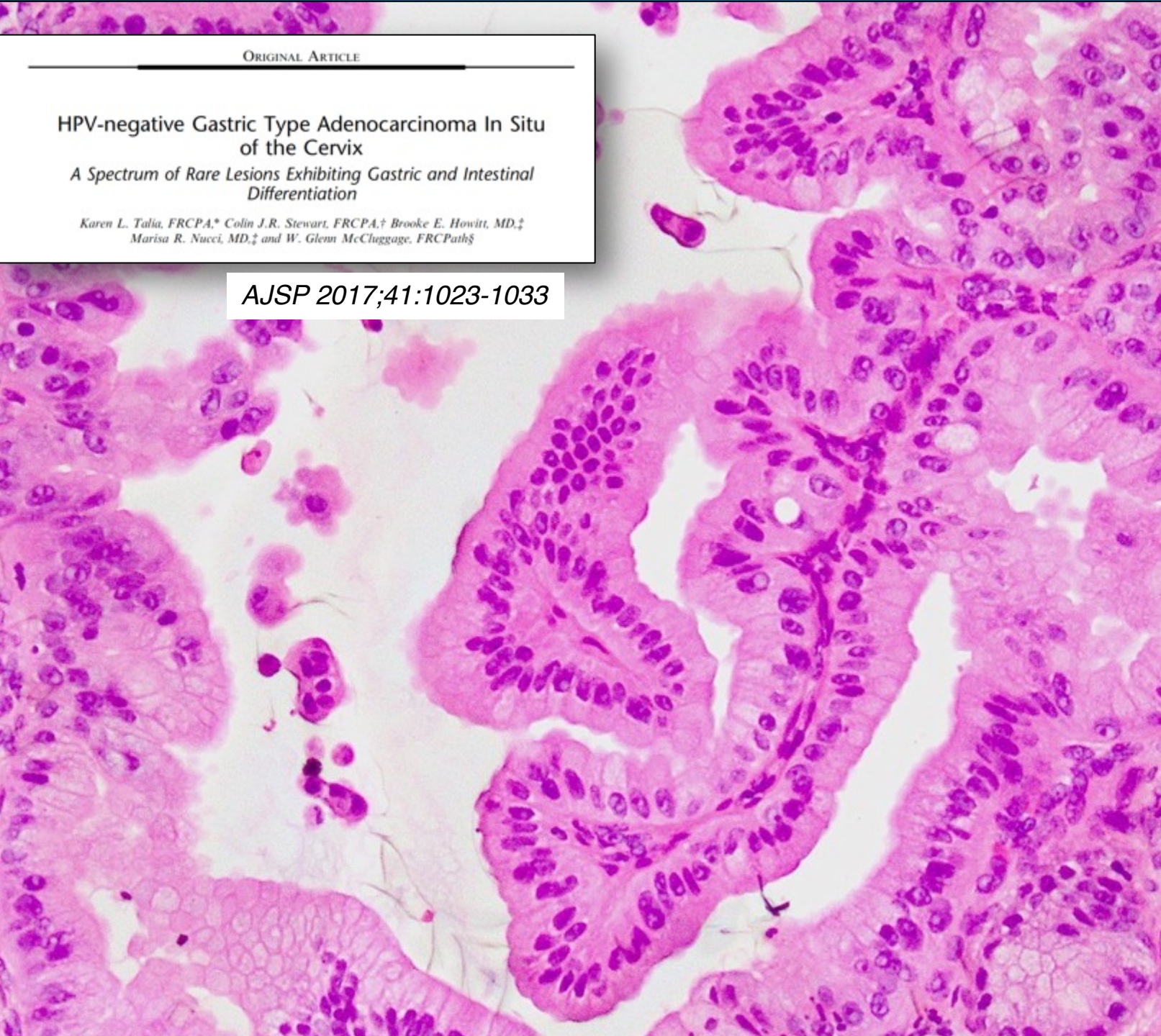


# HPV-negative Gastric Type Adenocarcinoma In Situ of the Cervix

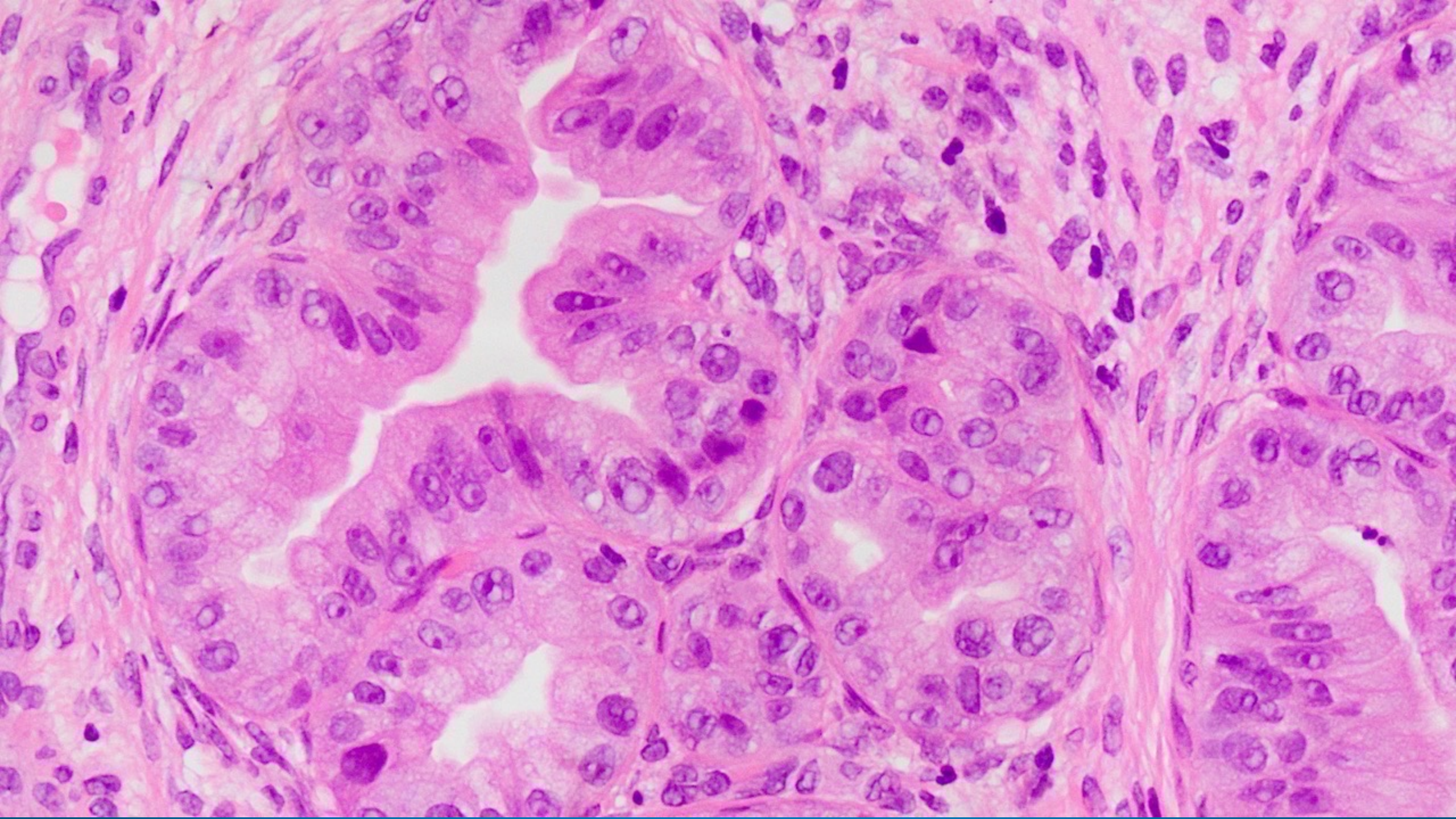
*A Spectrum of Rare Lesions Exhibiting Gastric and Intestinal Differentiation*

Karen L. Talia, FRCPA,\* Colin J.R. Stewart, FRCPA,† Brooke E. Howitt, MD,‡  
Marisa R. Nucci, MD,‡ and W. Glenn McCluggage, FRCPath§

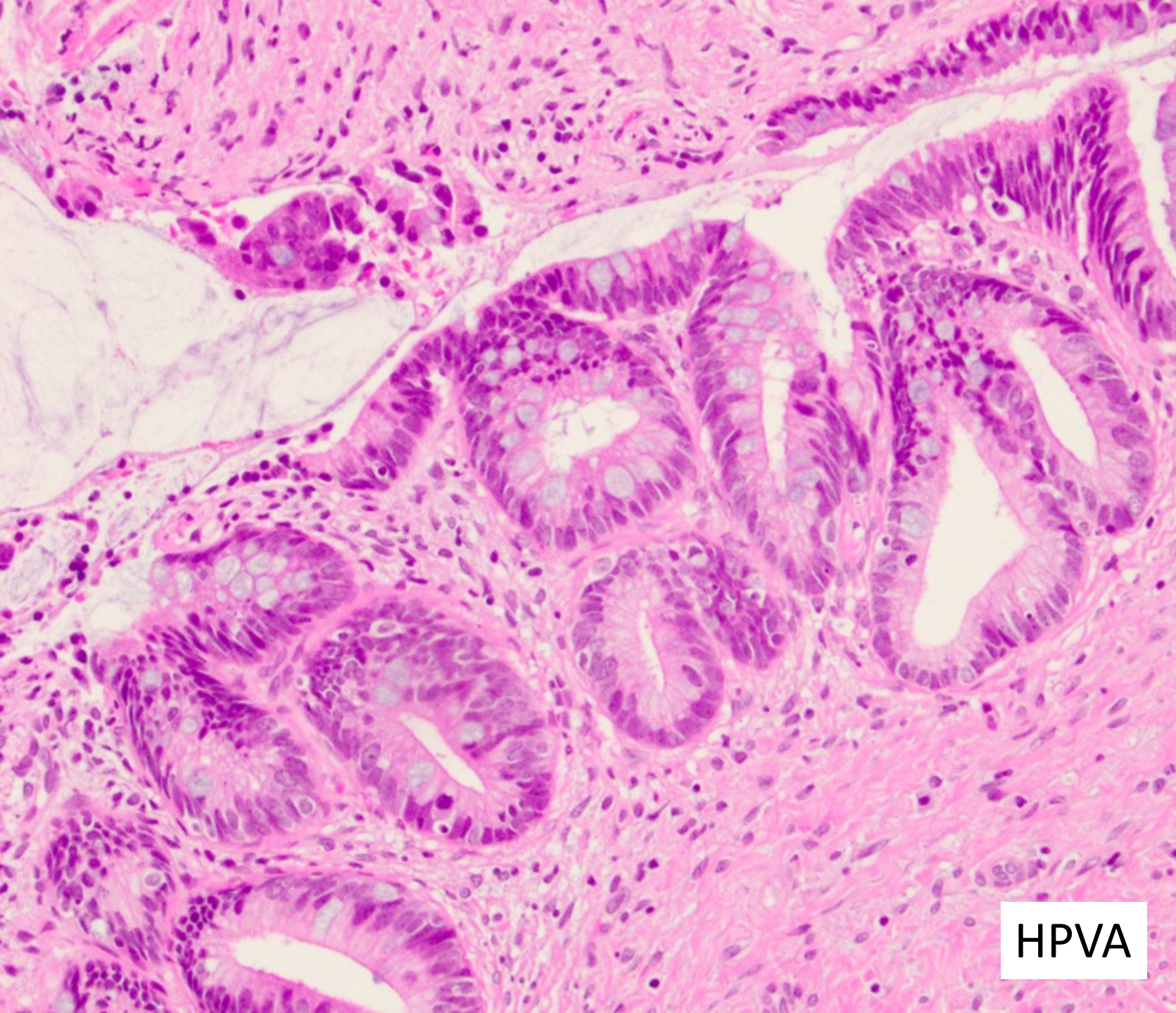
AJSP 2017;41:1023-1033



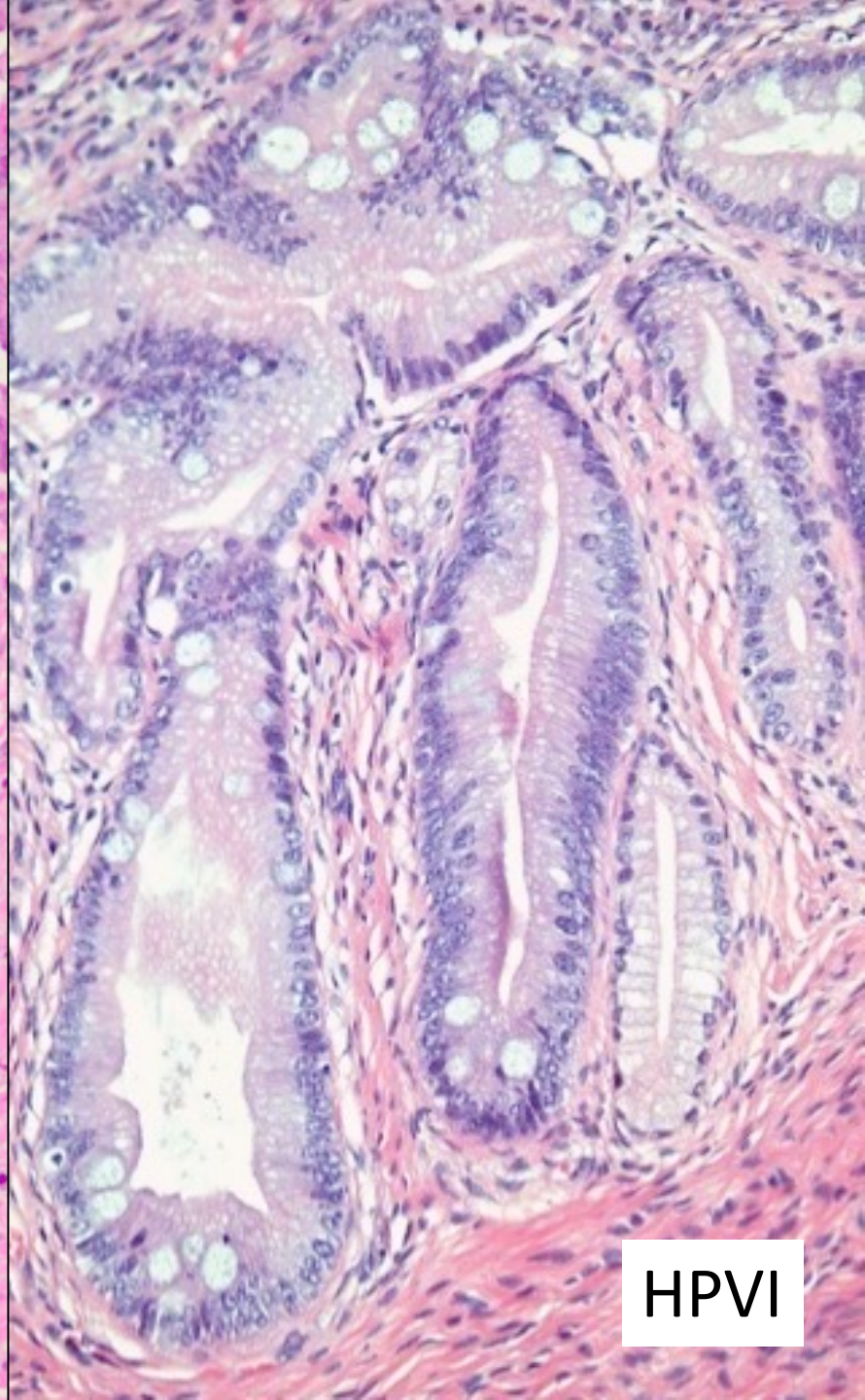








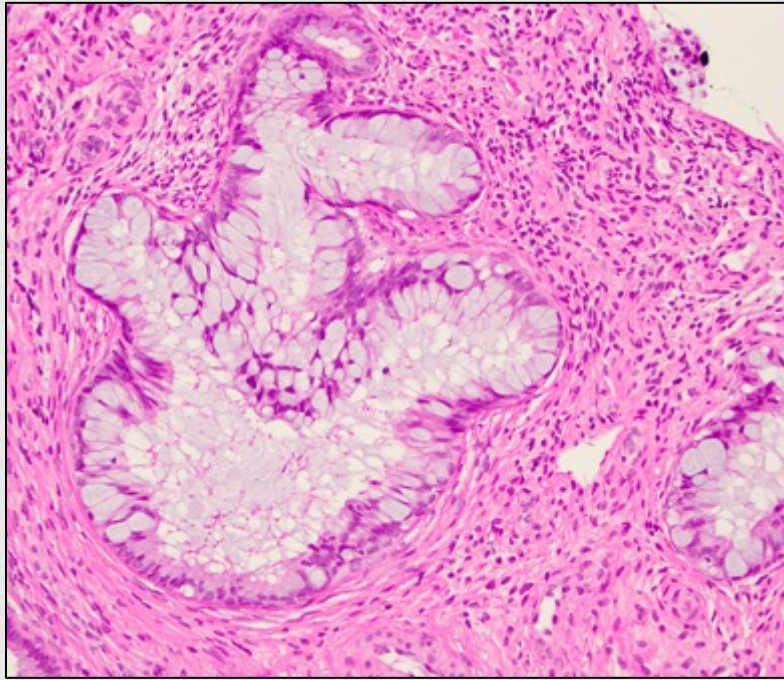
HPVA



HPVI



## HPVA AIS with intestinal differentiation



Nuclear compression by mucin → masks atypia

Elongate hyperchromatic nuclei

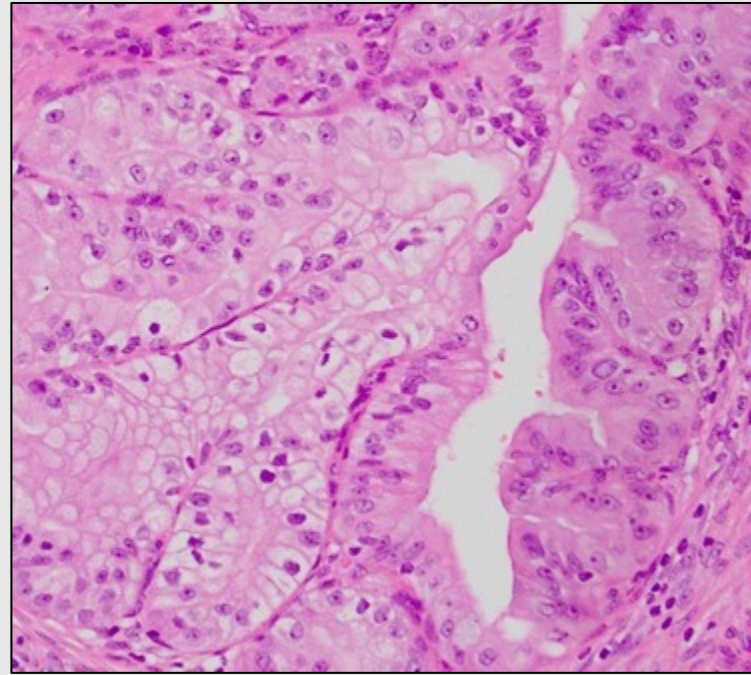
Mitotic and apoptotic activity

CK7+, CK20 +/-, CEA+/-, CDX2+/-, ER/PR-

p16 diffuse; **HPV ISH positive**

p53 wild type

## HPVI AIS, gastric type



Abundant eosinophilic/clear cytoplasm; demarcated borders

Basal rounded nuclei, subtle atypia

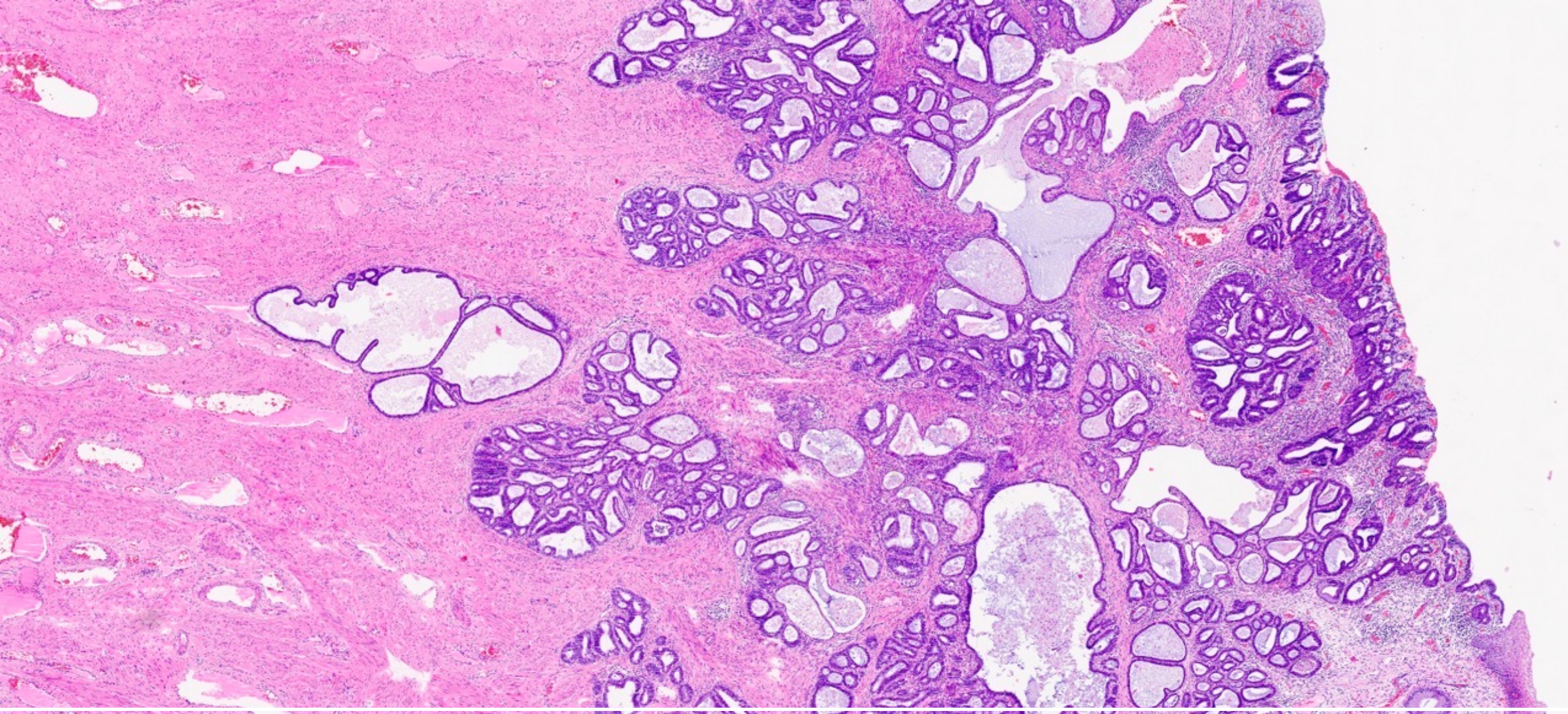
Low mitotic and apoptotic activity

CK7+, CK20 +/-, CEA+/-, CDX2+/-, ER/PR-  
MUC6, HIK1083, TFF2, Claudin 18

p16 non-diffuse (exceptions); HPV ISH negative

**p53 mutation type in some**

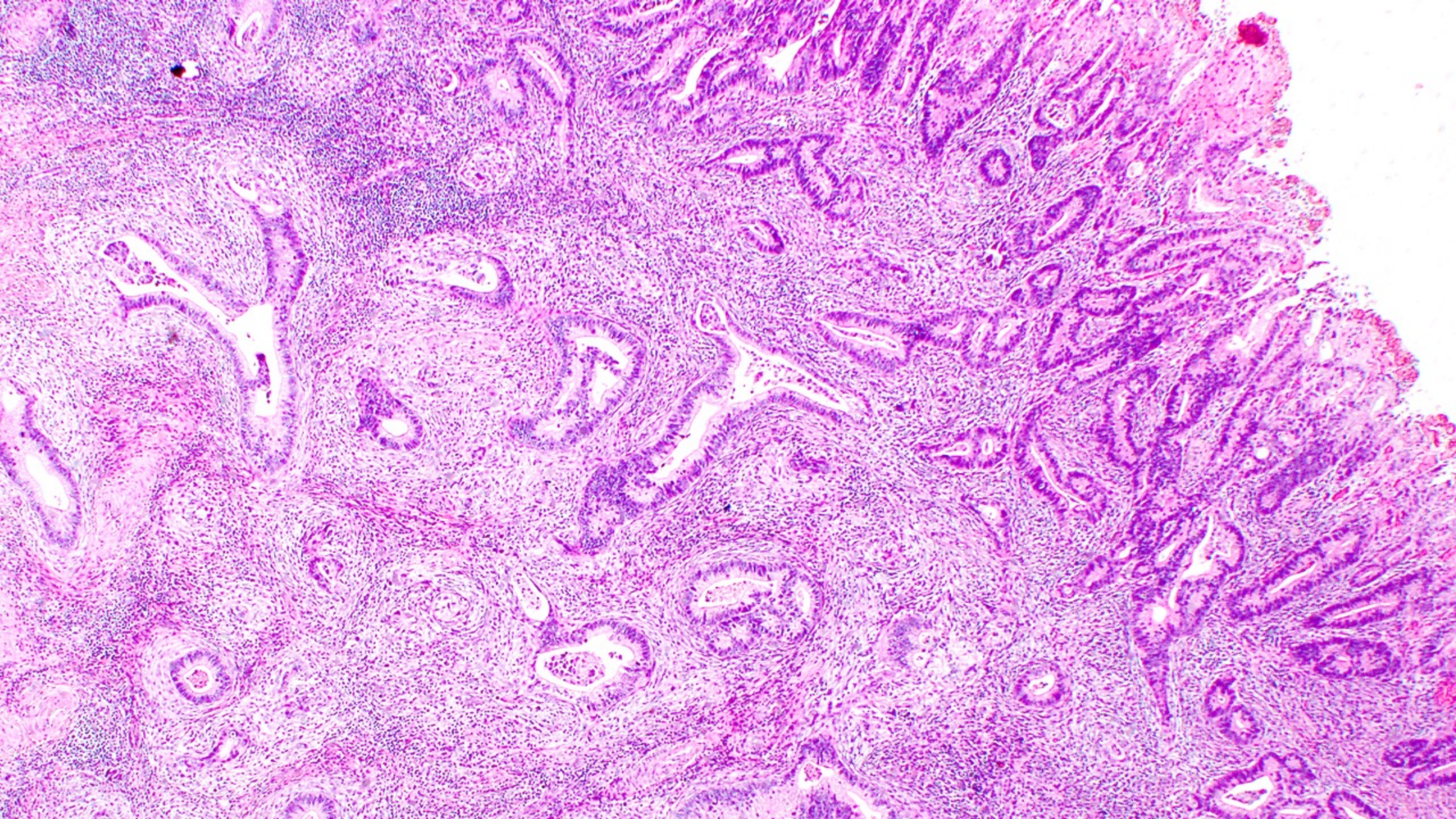




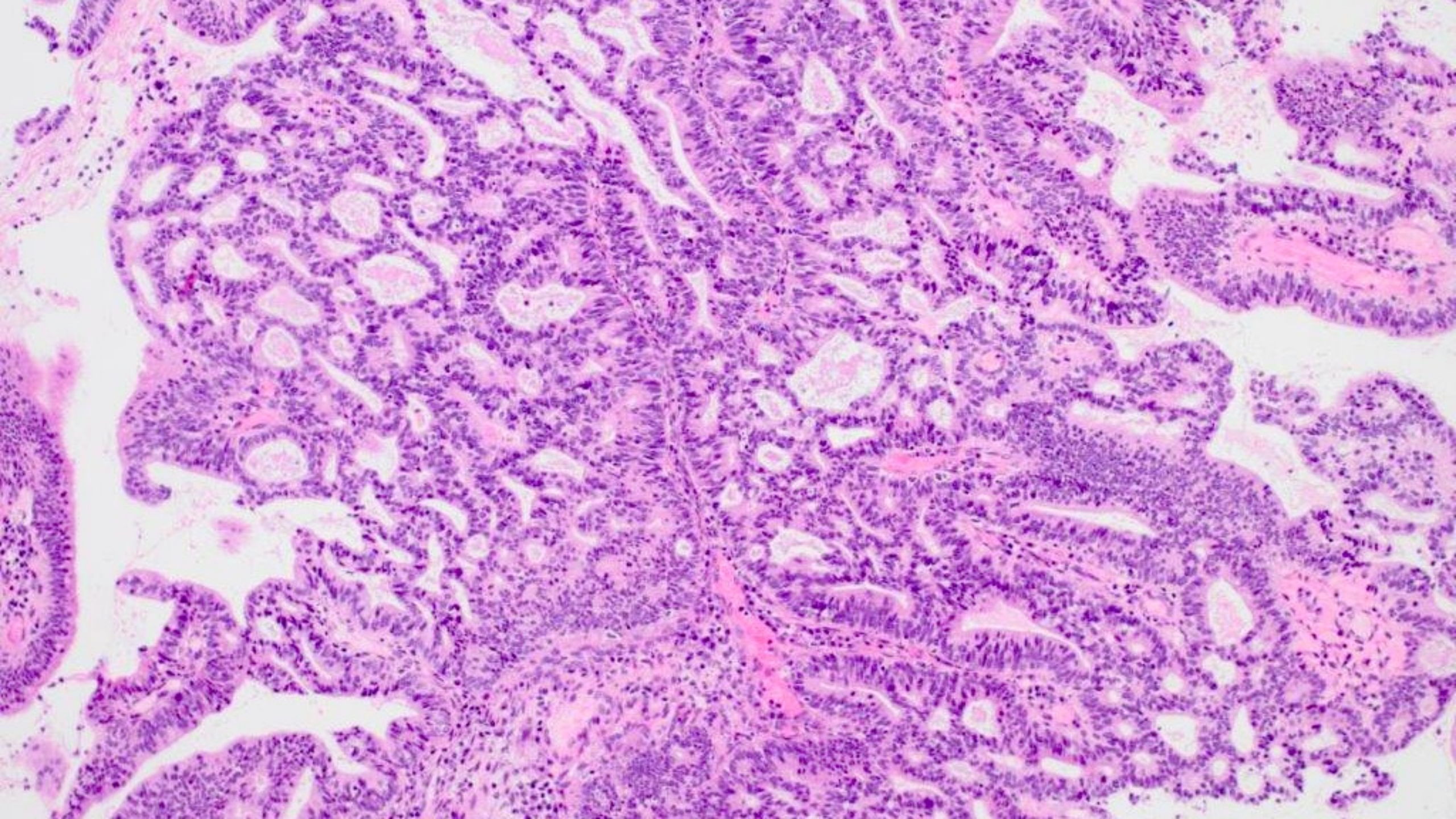
**HPVA endocervical adenocarcinoma – the sometimes-impossible mimic**

*Courtesy Prof McCluggage*

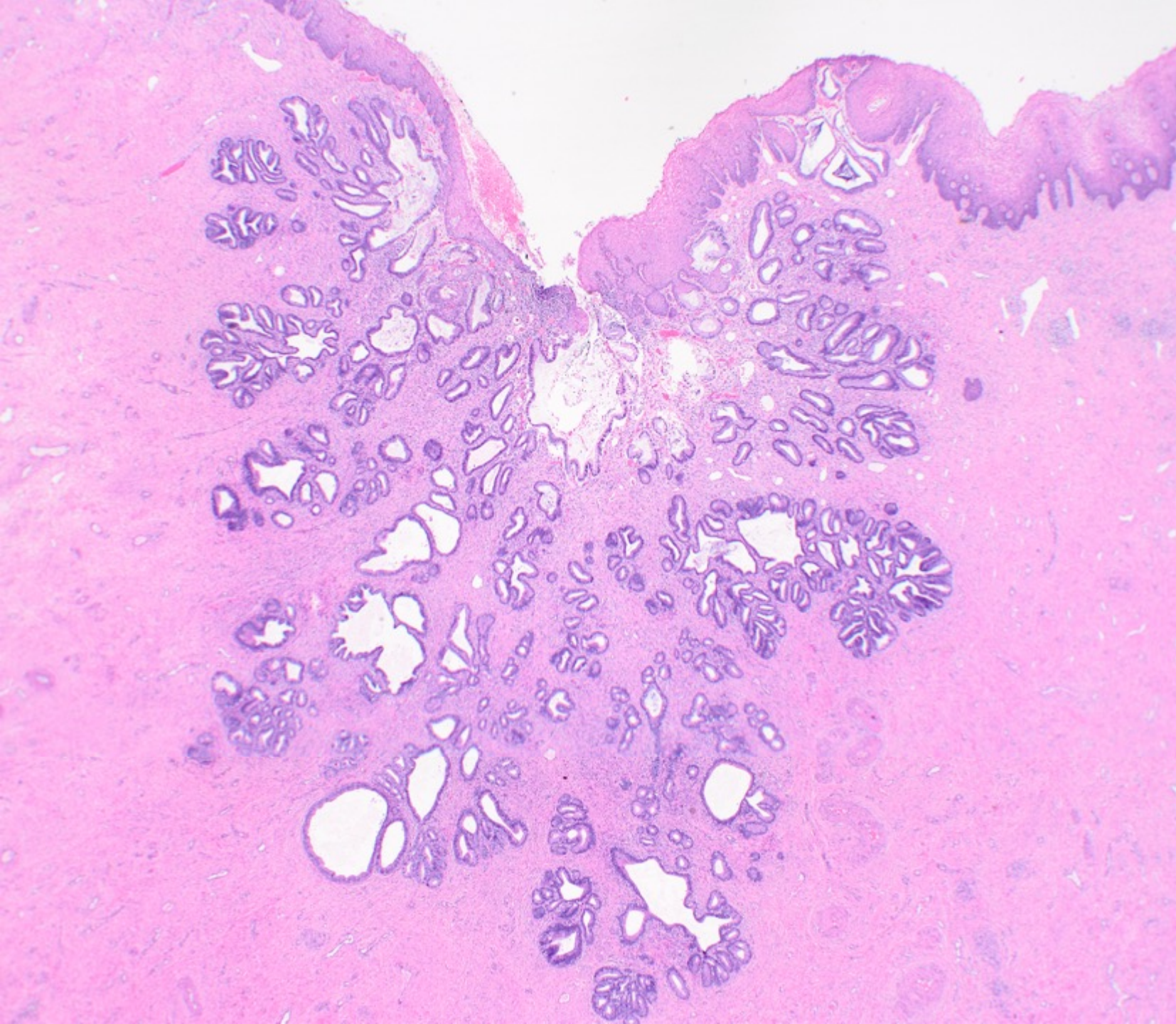












# **AIS or Pattern A Adenocarcinoma**

Estimated 20% of cases  
we cannot differentiate  
between in situ and  
invasive

Fair to poor  
reproducibility

*IJGP2000;19:29-38*

*IJGP2002;21:314-26*

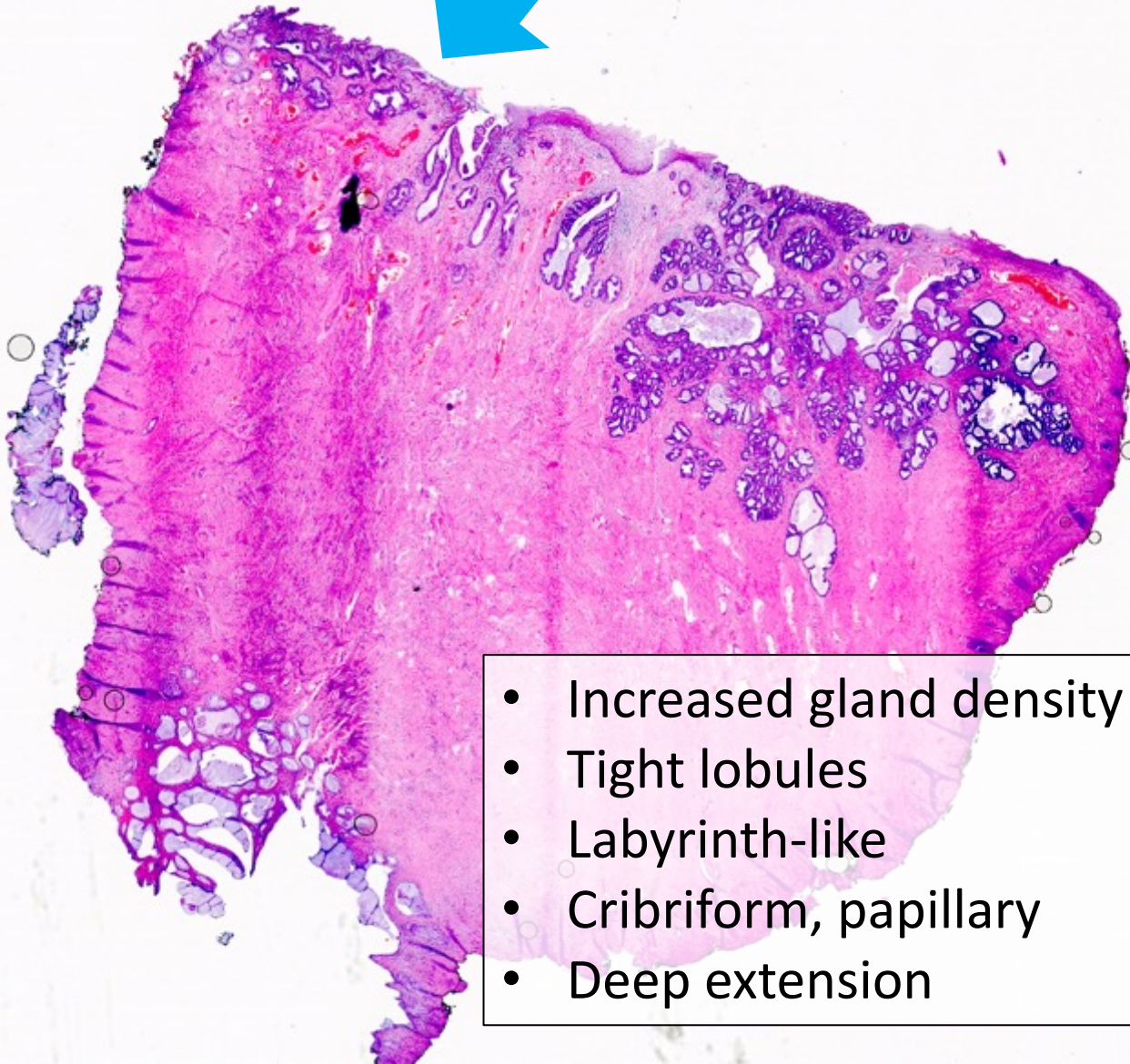
*Mod Pathol 2016;29:879-92*



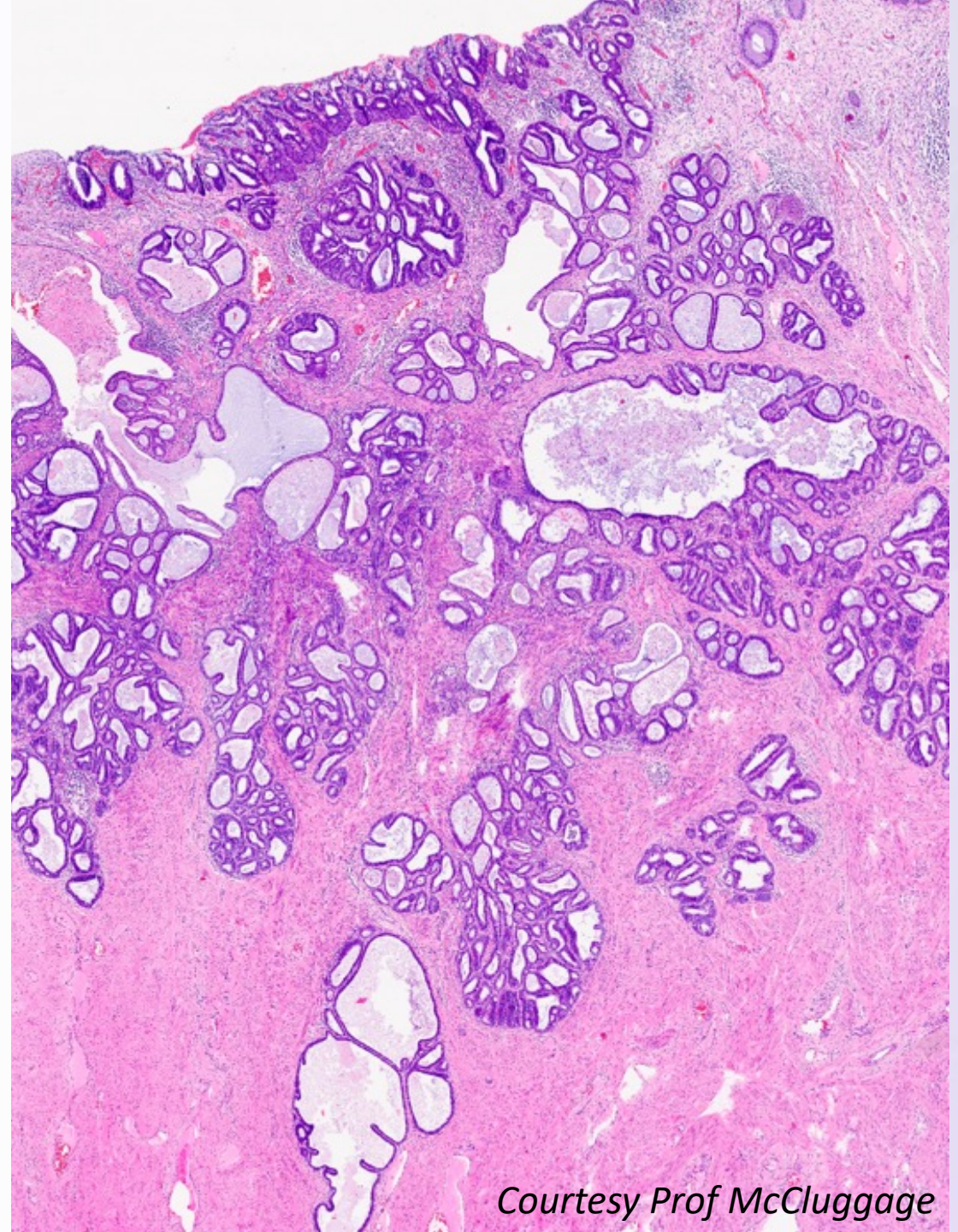
AIS or adenocarcinoma?



Compare with normal

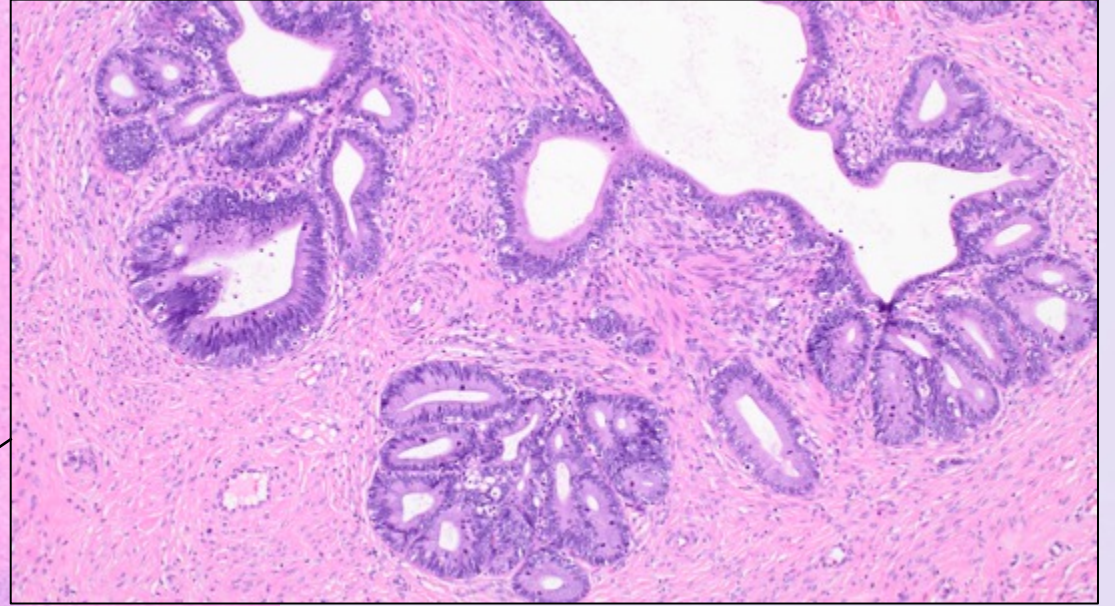
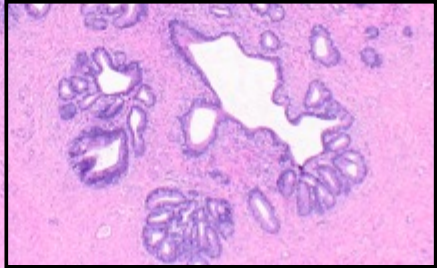
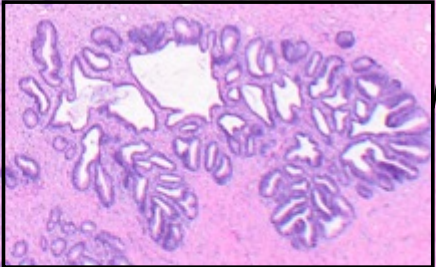
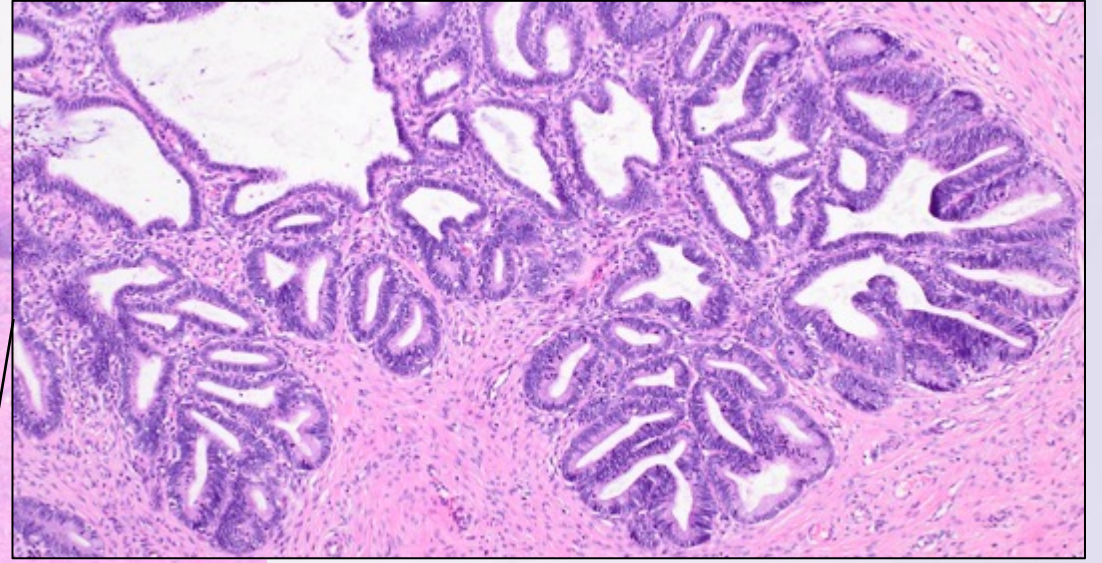
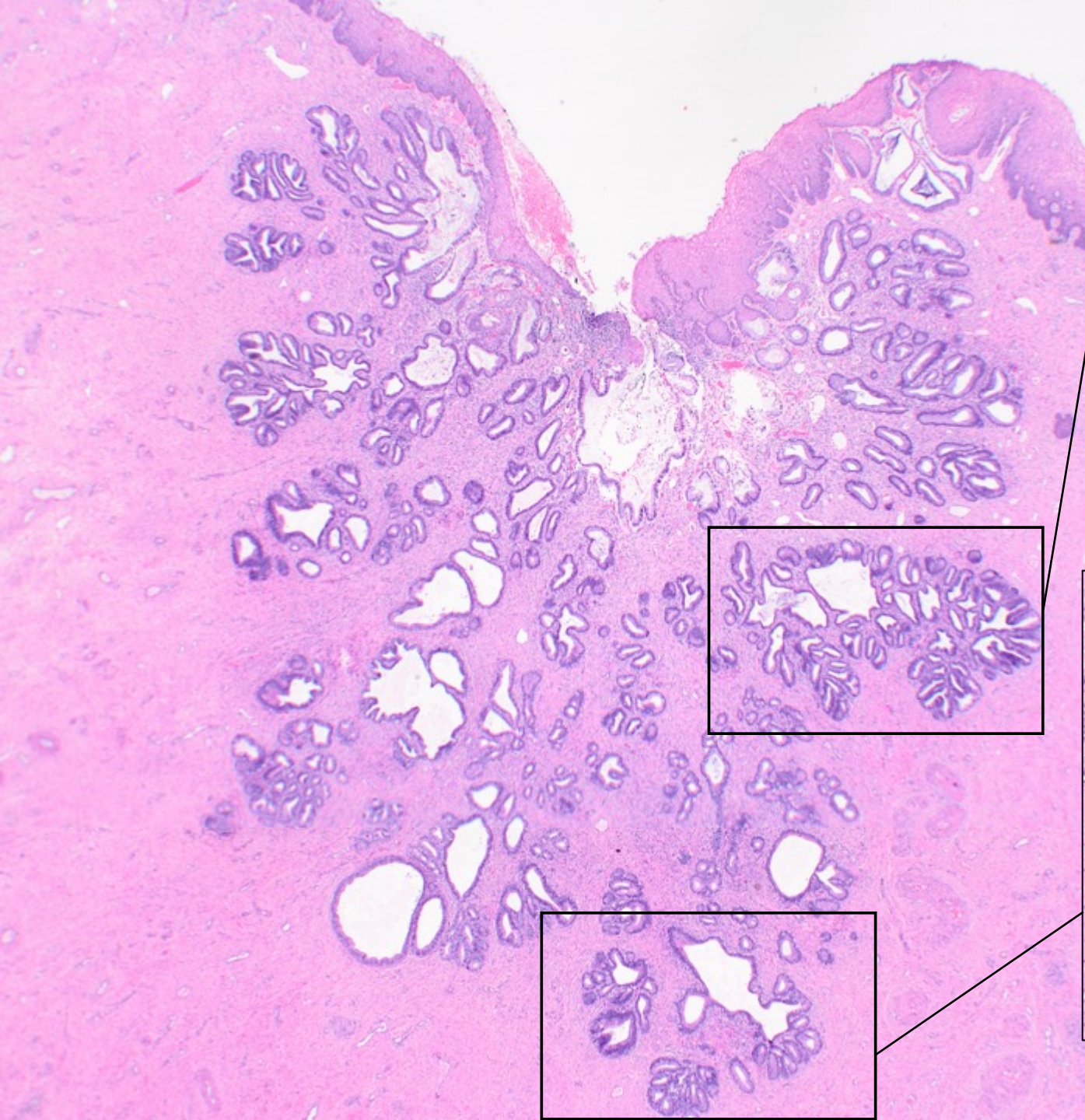


- Increased gland density
- Tight lobules
- Labyrinth-like
- Cribriform, papillary
- Deep extension

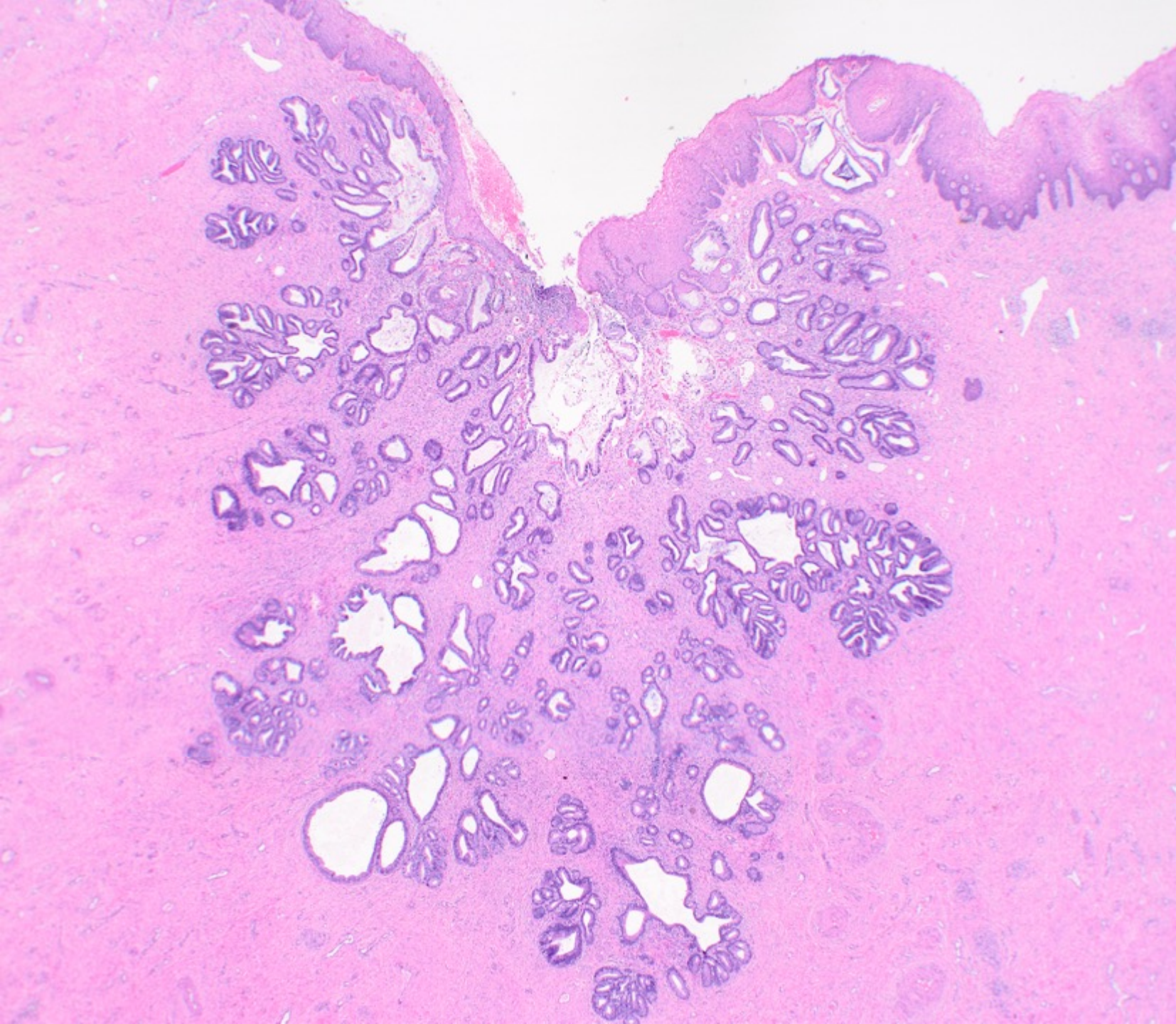


*Courtesy Prof McCluggage*









# AIS or Pattern A Adenocarcinoma

If cannot reliably determine:  
→ “pattern-A (non-destructive)  
adenocarcinoma”

Article

The Silva Pattern-based Classification for HPV-associated Invasive Endocervical Adenocarcinoma and the Distinction Between In Situ and Invasive Adenocarcinoma: Relevant Issues and Recommendations From the International Society of Gynecological Pathologists

Isabel Alvarado-Cabrero, M.D., Ph.D., Carlos Parra-Herran, M.D., Simona Stolnicu, M.D., Ph.D., Andres Roma, M.D., Esther Oliva, M.D., and Anais Malpica, M.D.

*IJGP 2021;40:S48-65*

? Move to consolidate AIS  
and AIS-like carcinoma



# Summary

Hyperchromasia, mitoses and apoptoses

Reserve cell layer

p16, ER/PR

History – is the patient HRHPV+?



# THANK YOU!

## ACKNOWLEDGEMENTS

Joseph Rabban

Natalie Banet

Glenn McCluggage

Marsali Newman

Michelle Moore